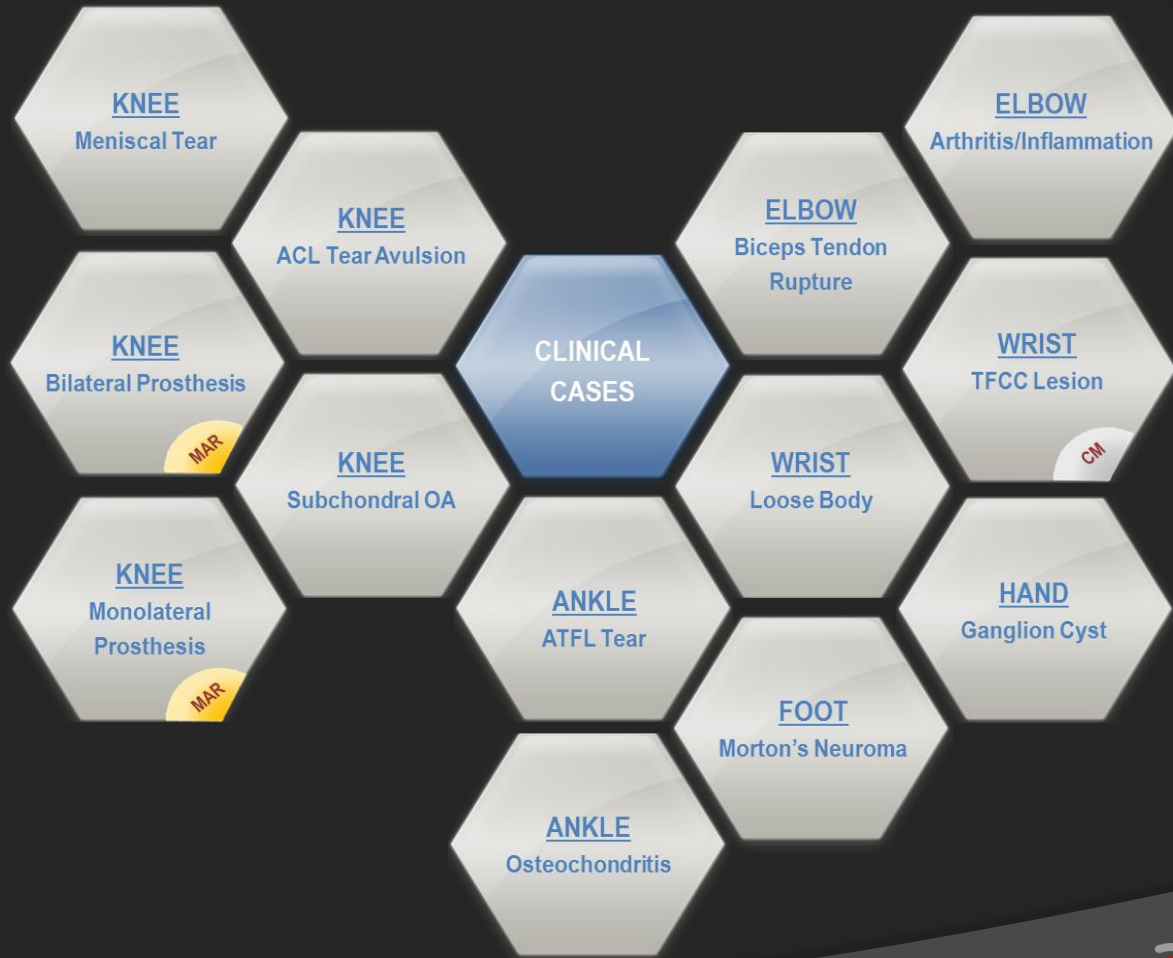


CLINICAL CASES

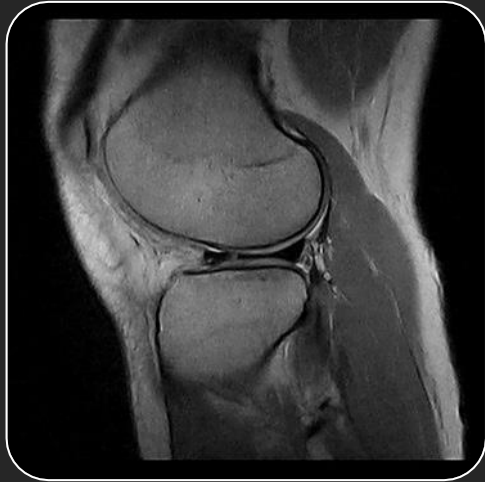



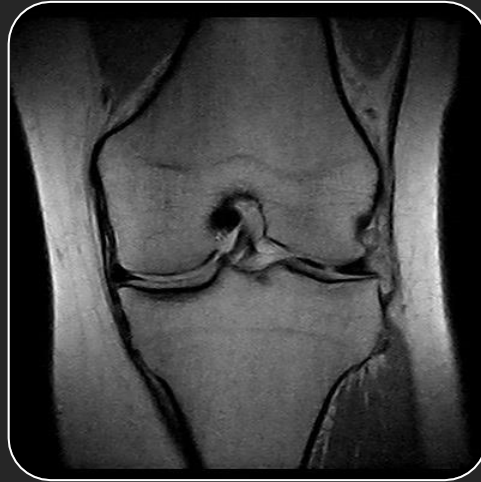Take Pride in
Performance



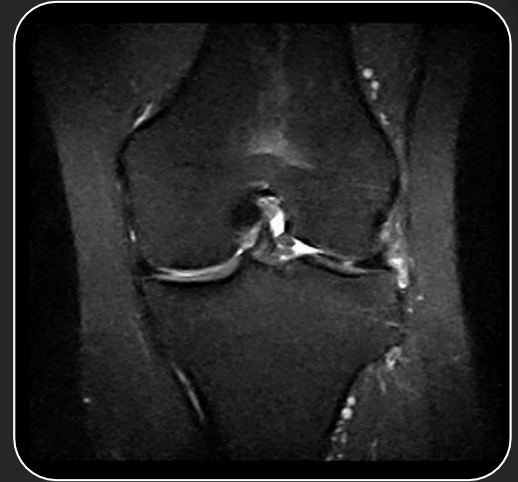Knee: Meniscal Tear



FSE PD - Sagittal

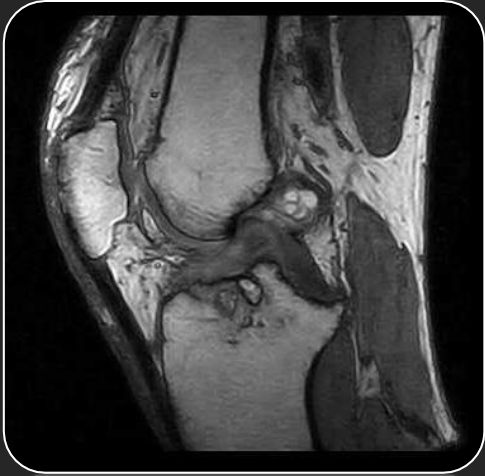

FSE PD - Coronal

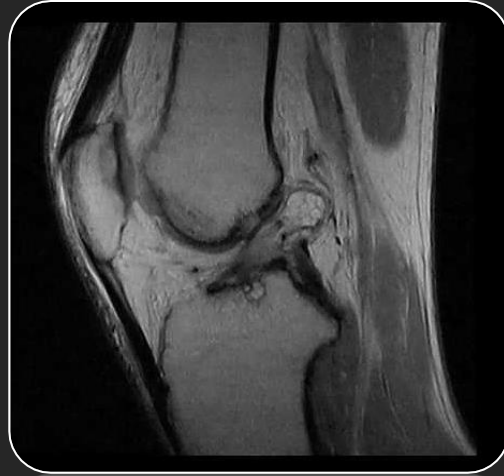

FSTIR - Coronal

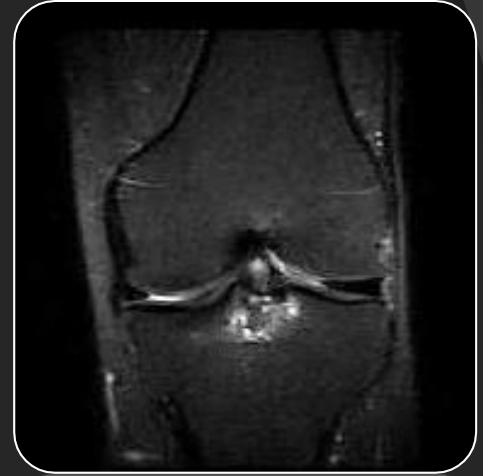Knee: ACL Tibial Avulsion



3D SHARC ISO - Sagittal

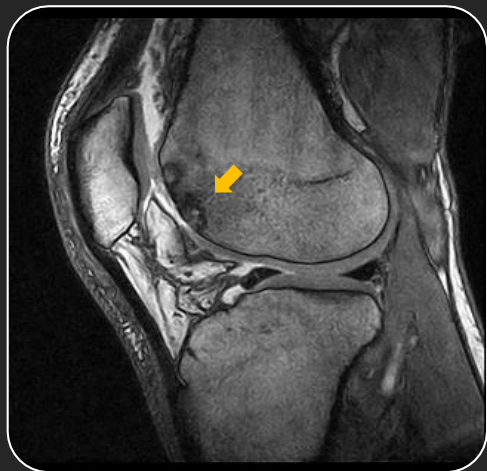

FSE PD - Sagittal

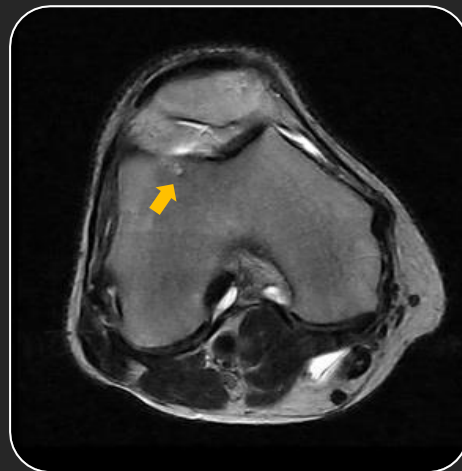


FSTIR - Coronal

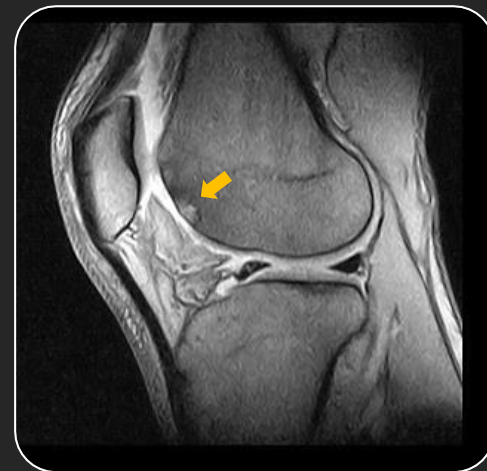Knee: Subchondral OA



3D SHARC ISO - Sagittal

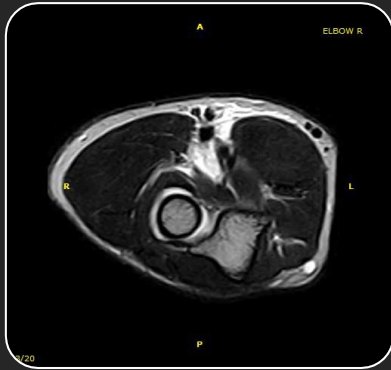

FSE T2 - Axial

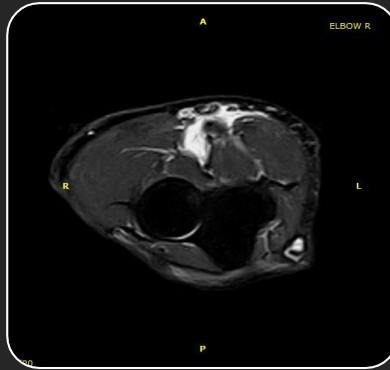

GE T2 - Sagittal

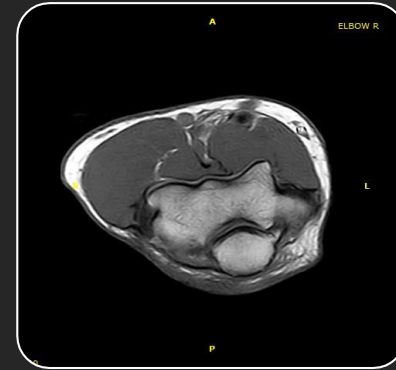
Elbow: Biceps Tendon Rupture



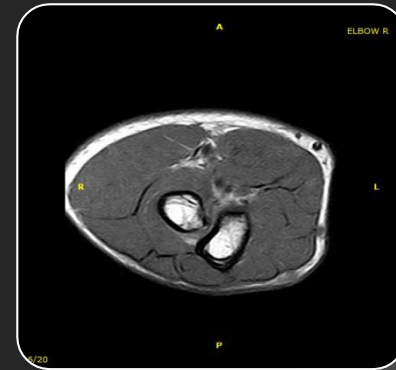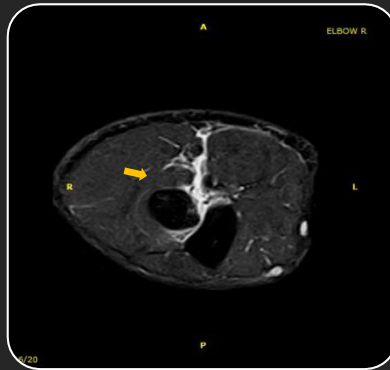
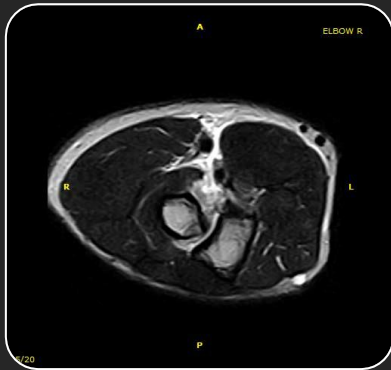FSE T2 - Axial



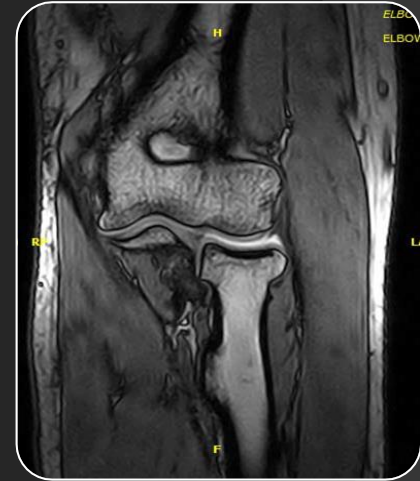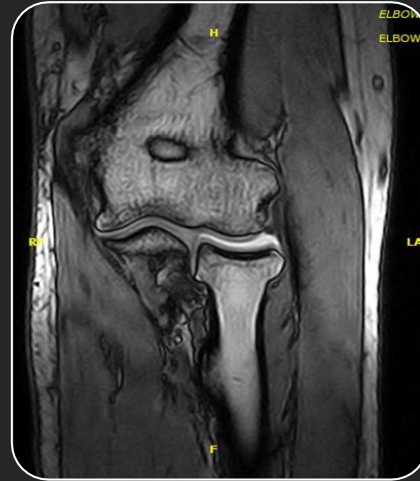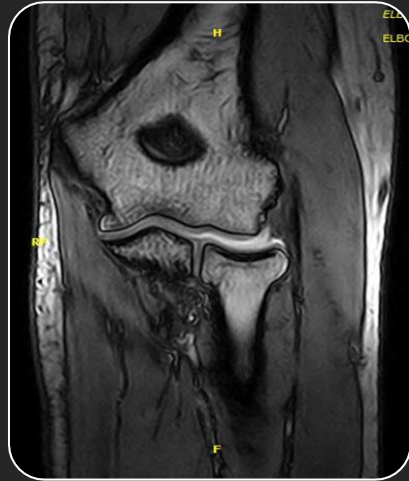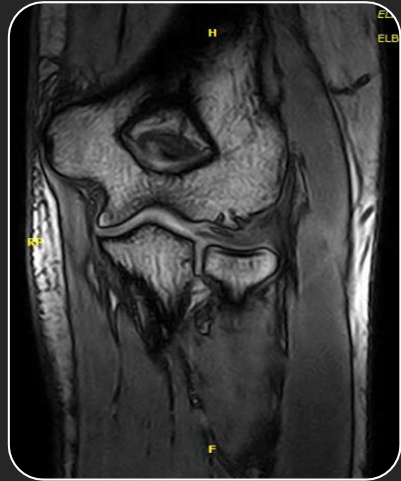GE STIR- Axial



SE T1 - Axial

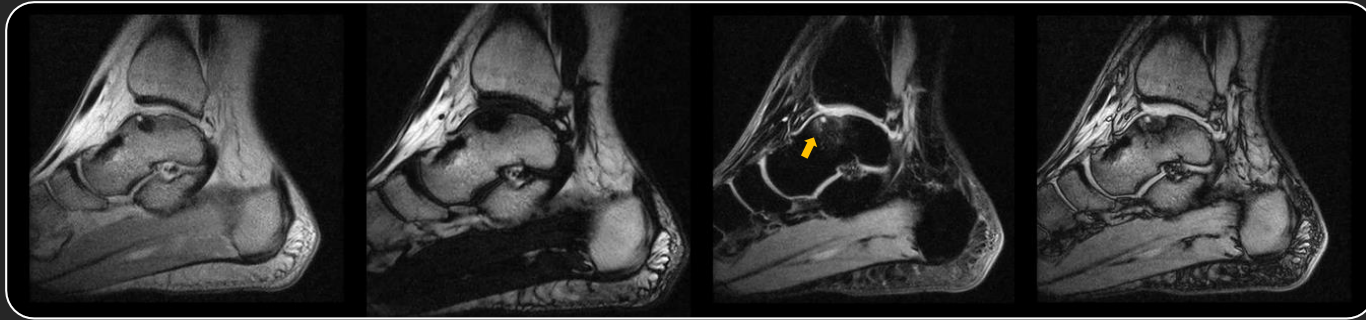


Elbow: Arthritis & Inflammation

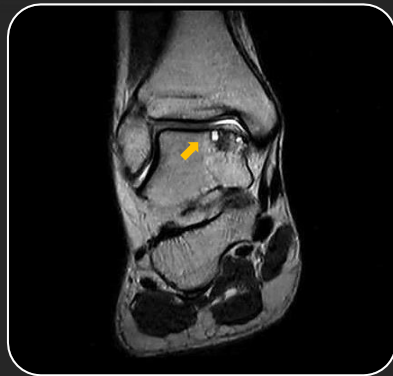

3D SHARC ISO - Coronal

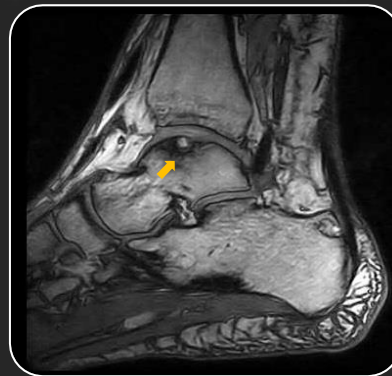Ankle: Osteochondritis Dissecans



X-Bone T2 (4 echoes) -
Sagittal

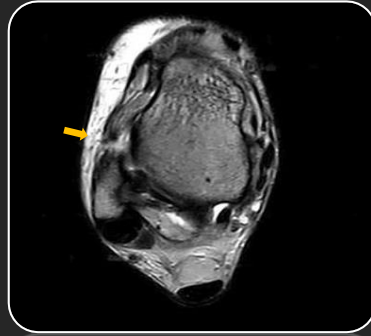
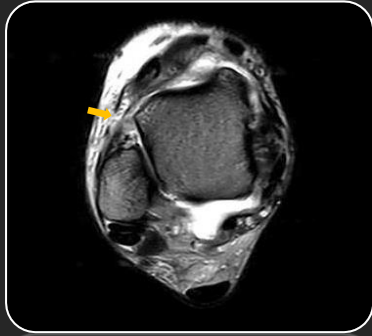
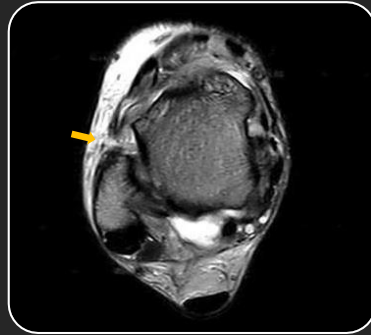
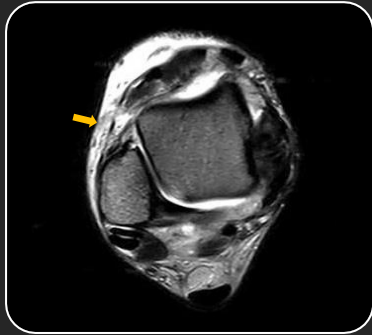FSE T2 - Coronal

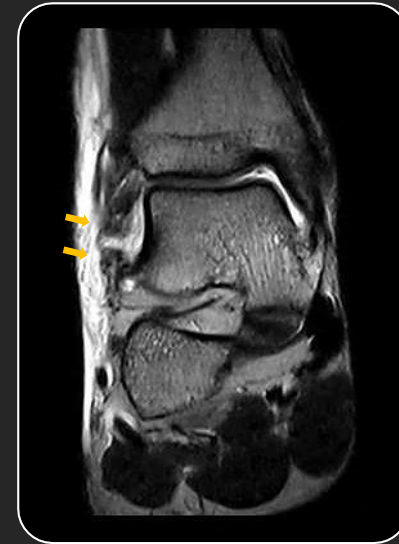

3D SHARC ISO - Sagittal

Ankle: ATFL Tear

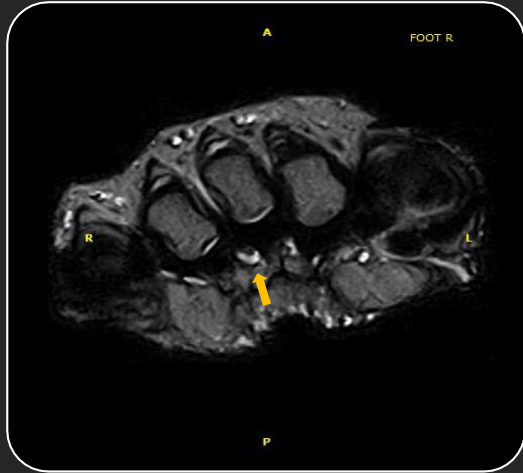


FSE T2 - Axial

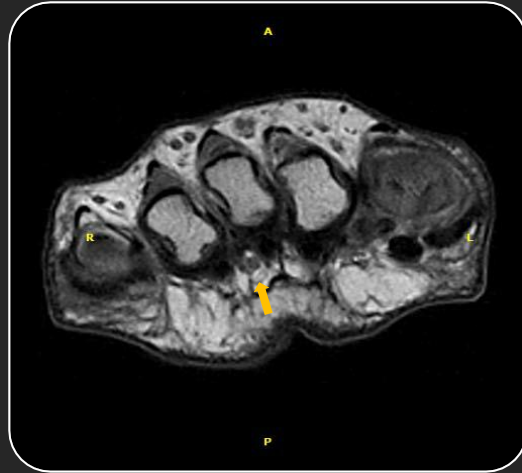


FSE T2 - Coronal

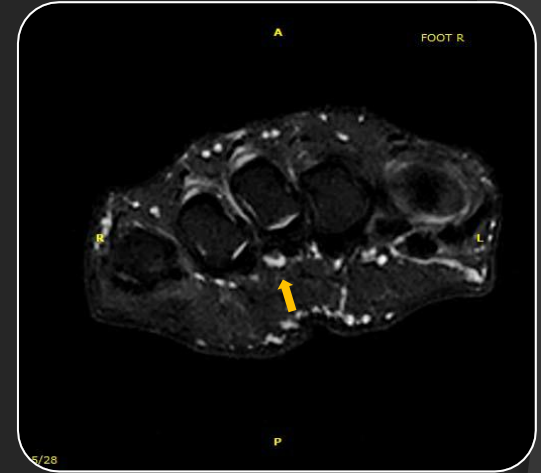
Foot: Morton's Neuroma



FSE T2 - Axial

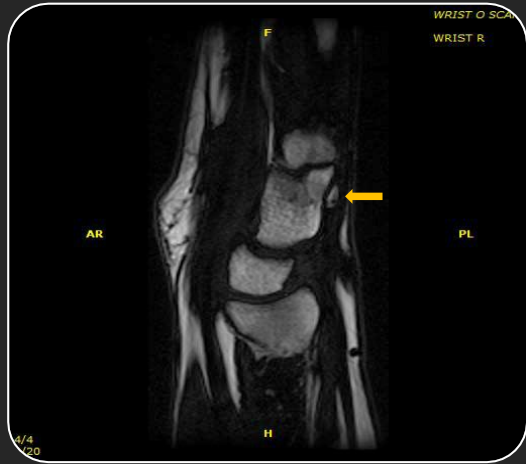


SE T1 - Axial

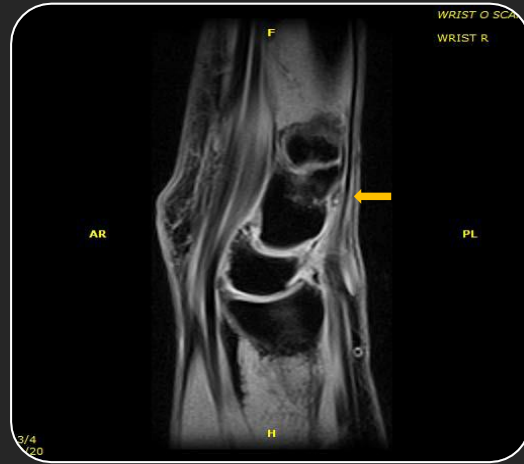


FSTIR - Axial

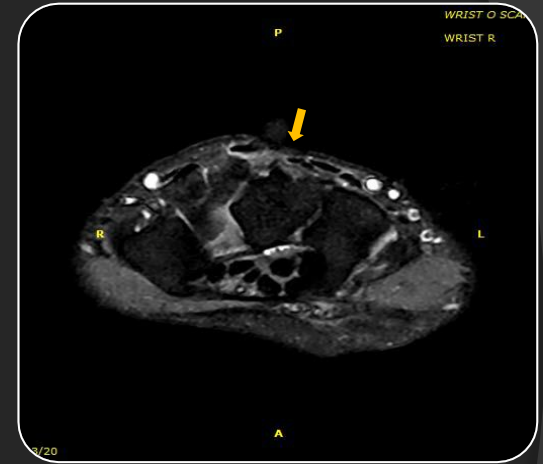
Wrist: Loose Body



FSE T2 - Sagittal

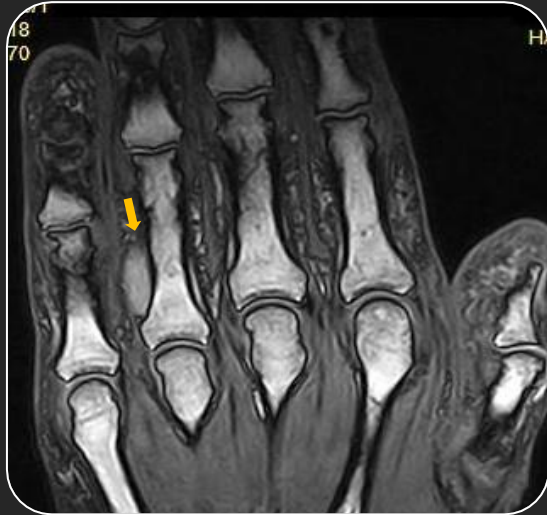

X-Bone T2 (Fat Suppression Echo) - Axial

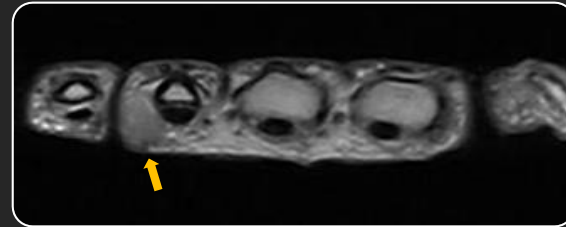
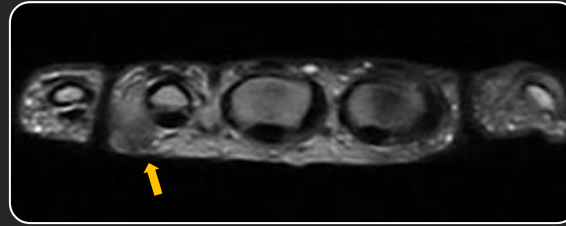


FSTIR - Axial

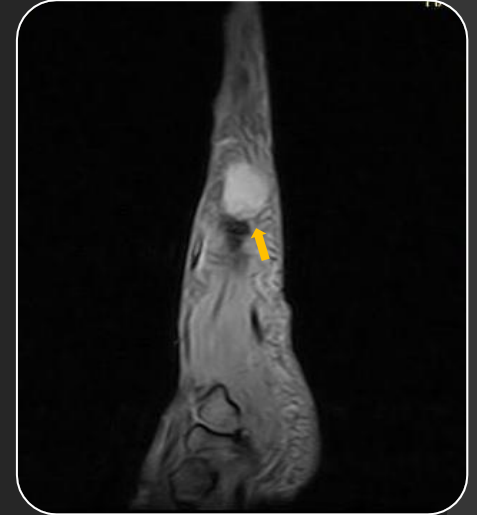
Hand: Ganglion Cyst



3D SHARC ISO - Coronal

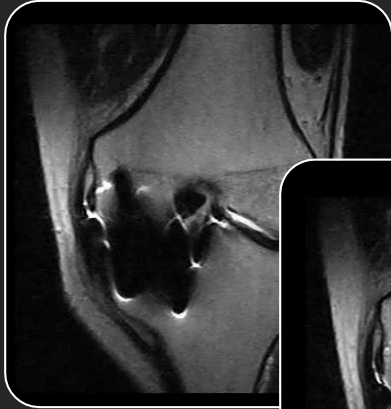


FSE PD-T2 - Axial

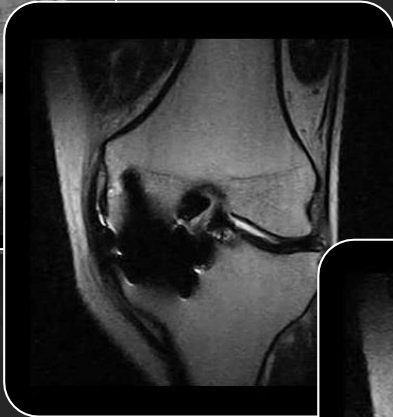

GE T2 - Sagittal

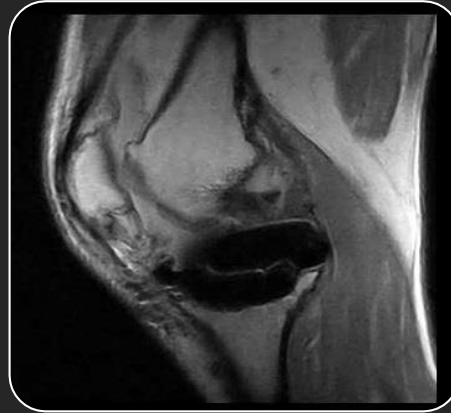Knee: Monolateral Prosthesis W / MAR



FSE T2
Coronal

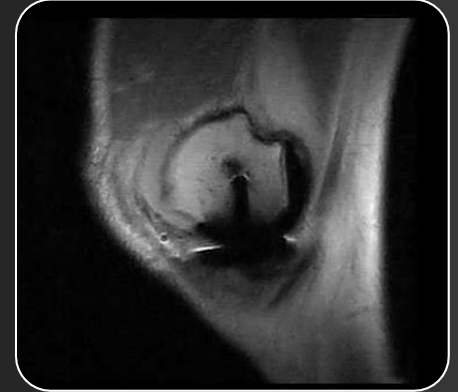

FSE T2
Coronal
(MAR)

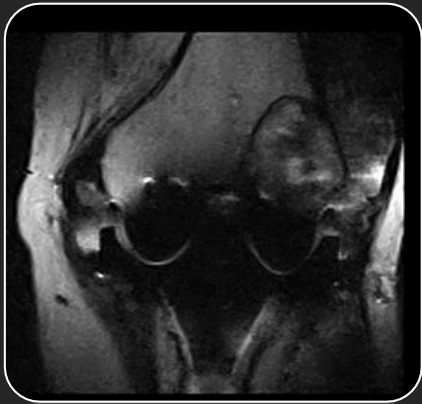

FSE T2
Coronal (X-MAR)

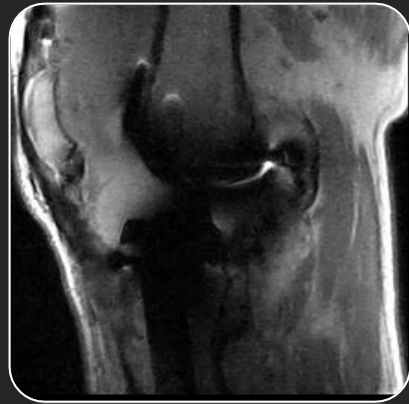FSE PD
Sagittal (X-MAR)



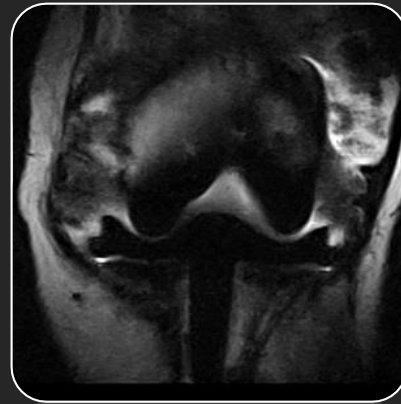Knee: Total Knee Replacement



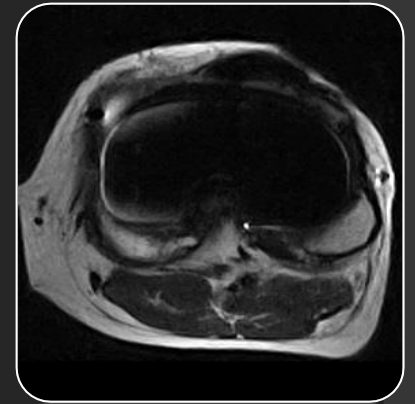
FSE T2 w/ MAR - Coronal



FSE PD w/ MAR - Sagittal

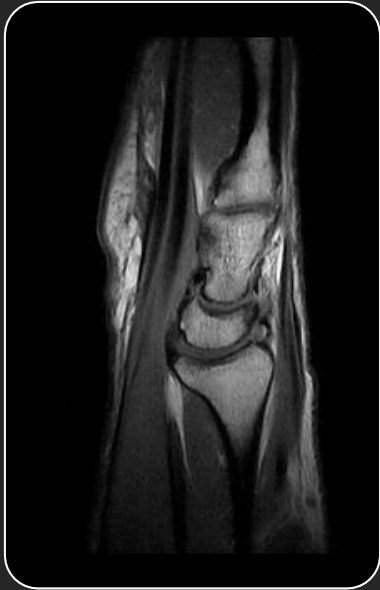

FSE T2 w/ MAR - Coronal

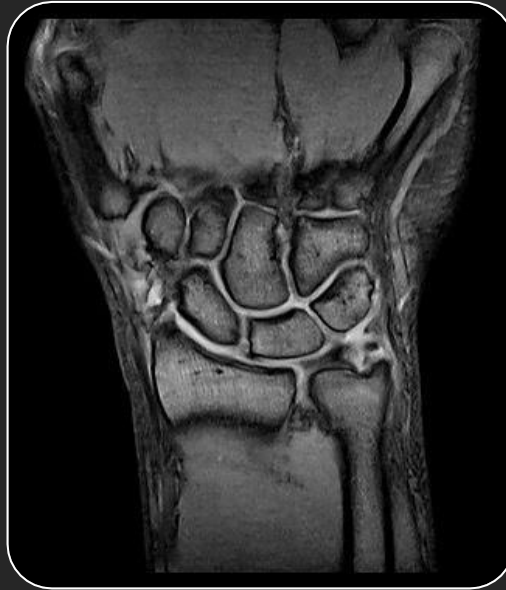

FSE T2 w/ MAR - Axial

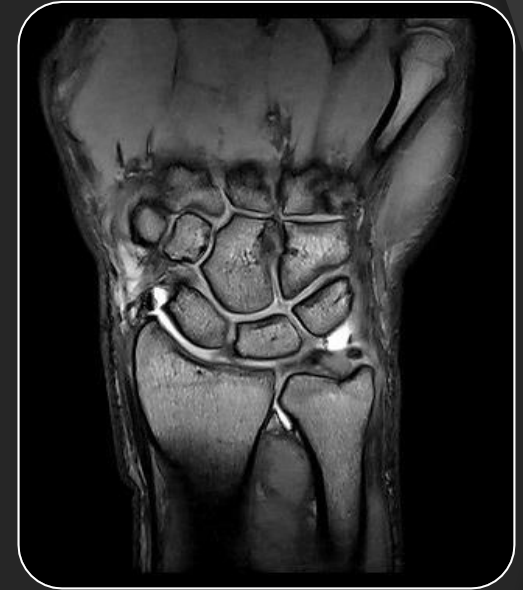Wrist: TFCC Lesion w/ CM



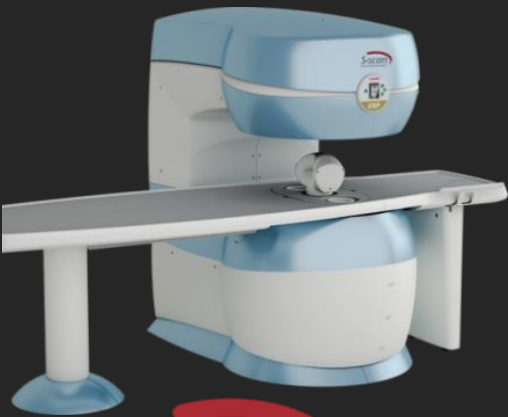SE T1 - Sagittal



GE T1 (pre-contrast) - Coronal

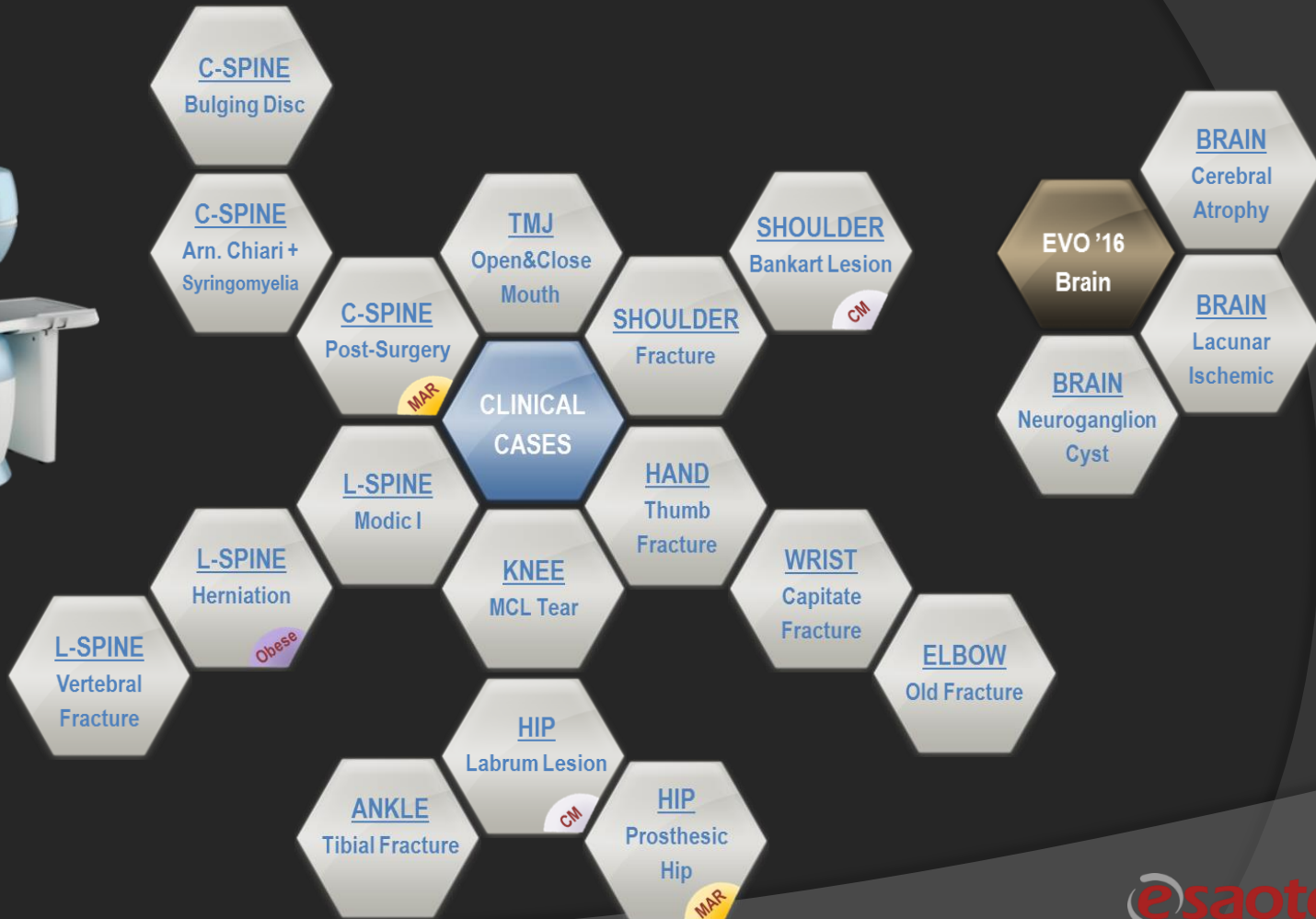

GE T1 (post-contrast) -
Coronal

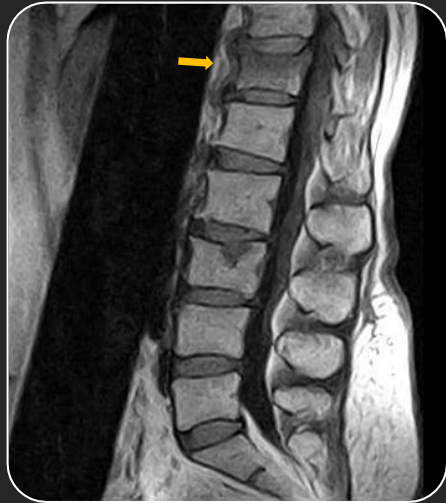


S-scan
eXP
Technology

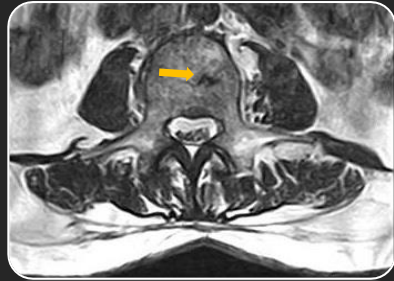
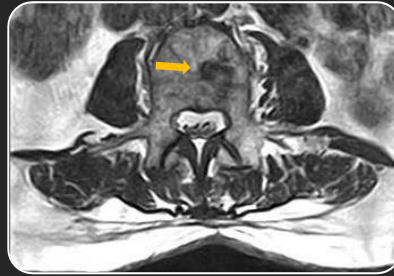
Top Performance
In Action



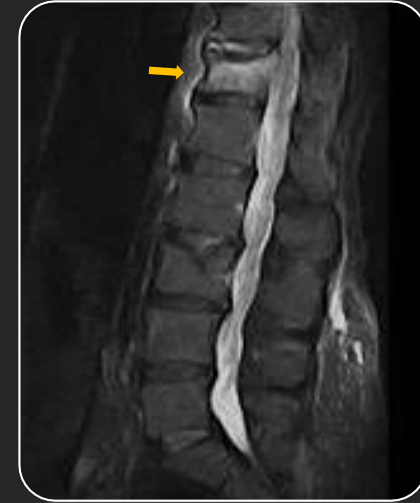L-Spine: Vertebral Fracture



SE T1 - Sagittal

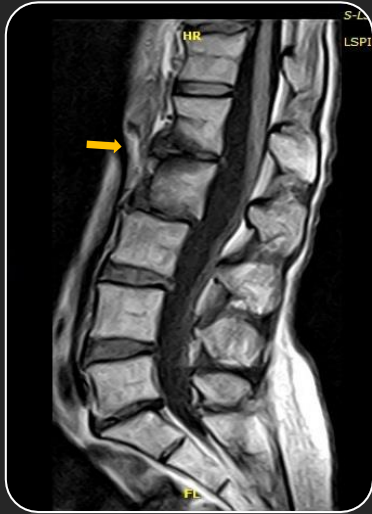


3D HYCE ISO - Axial

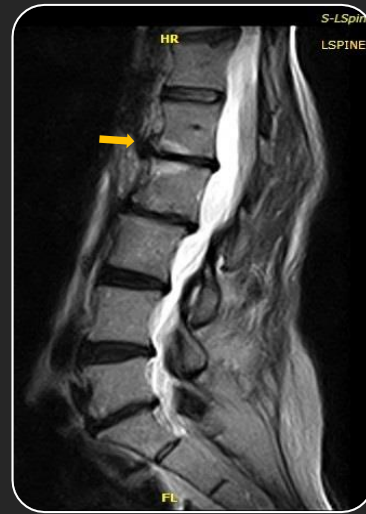
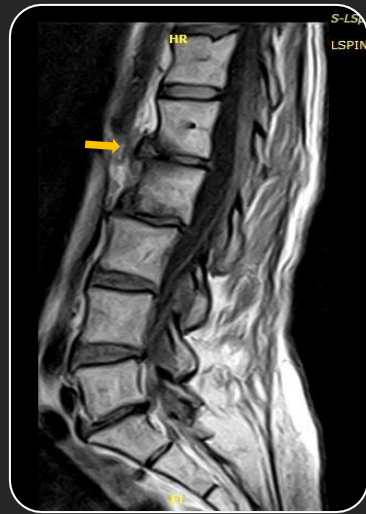
FSTIR - Sagittal

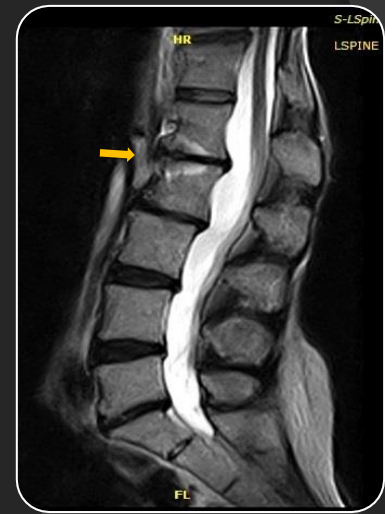L-Spine: Disc Degeneration (Modic I)



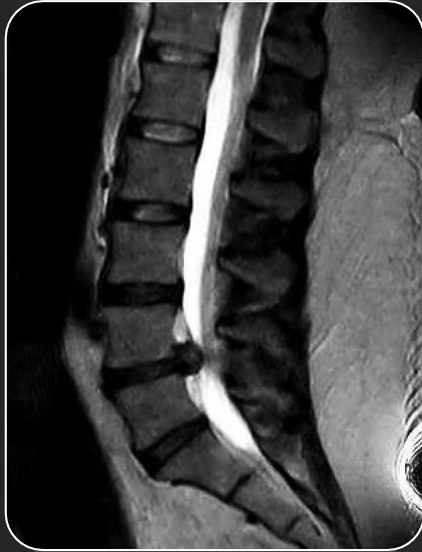SE T1 - Sagittal



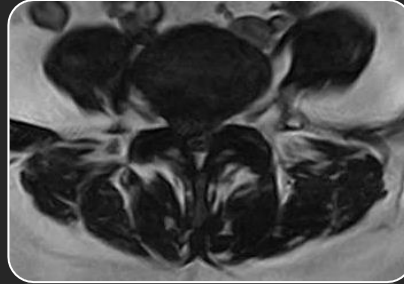
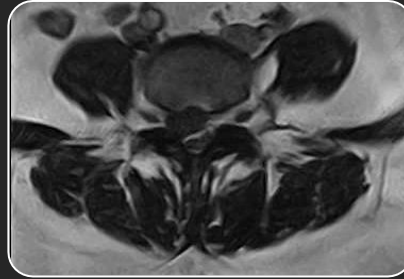
FSE T2 - Sagittal



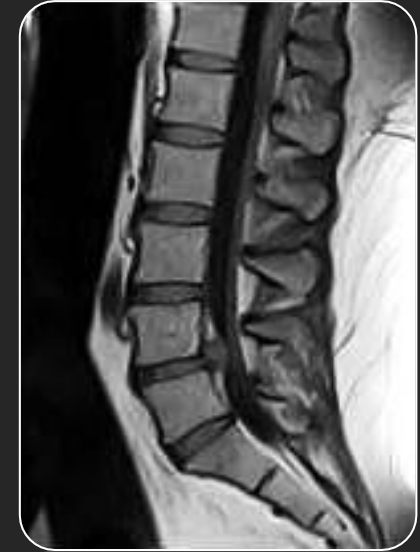L-Spine: Disc Herniation (Obese Patient)



FSE T2 - Sagittal

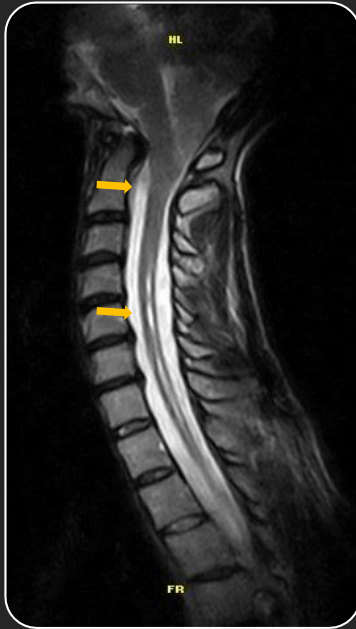

3D HYCE ISO - Axial

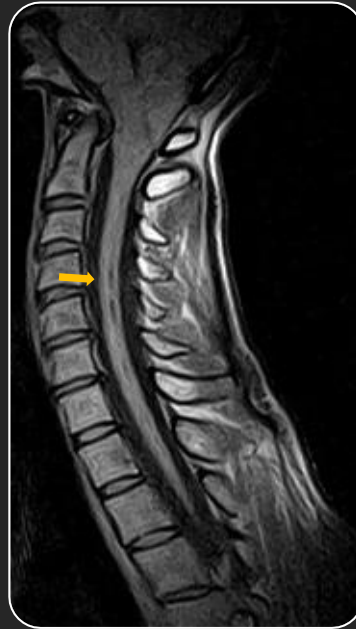

SE T1 - Sagittal

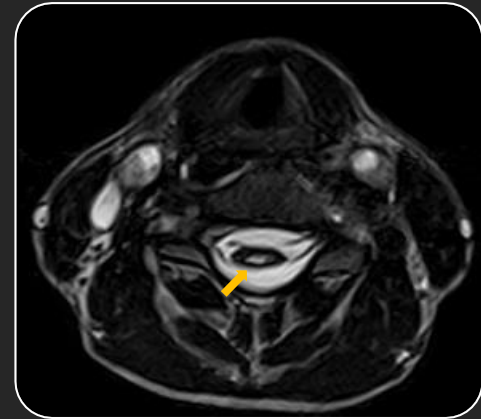
C-Spine: Arnold Chiari + Syringomyelia



FSE T2 - Sagittal

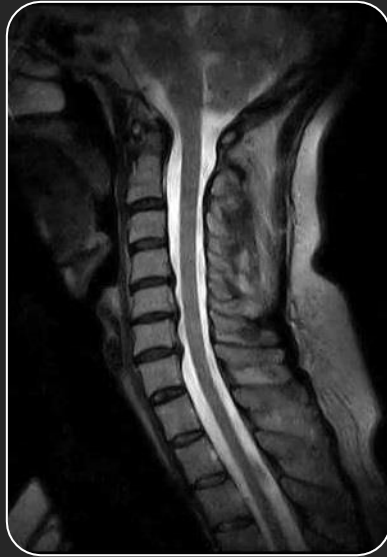

SE T1 - Sagittal

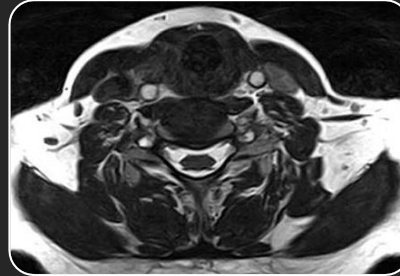
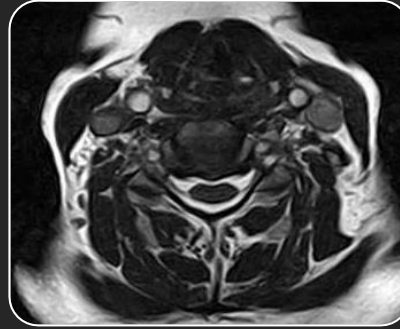


3D HYCE ISO - Axial

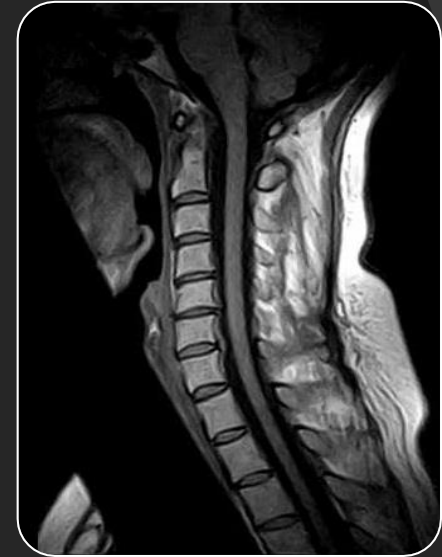C-Spine: Bulging Disc



FSE T2 - Sagittal

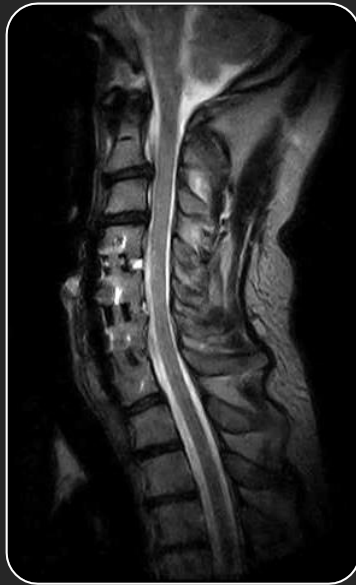

3D HYCE ISO - Axial

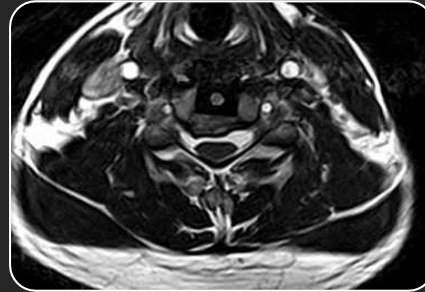
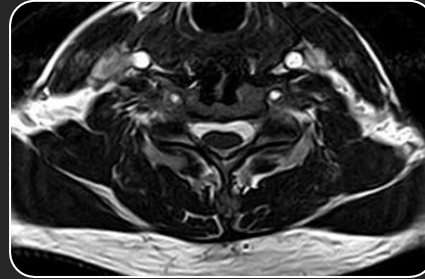


SE T1 - Sagittal

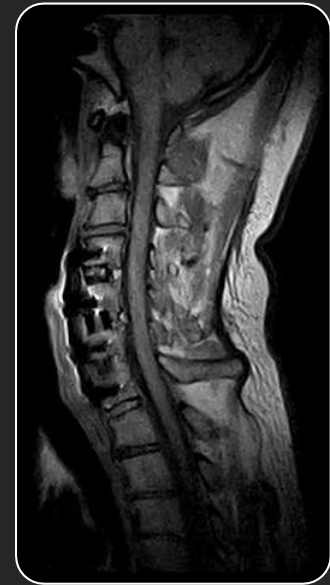C-Spine: Postsurgical Fixation (MAR)



FSE T2 - Sagittal

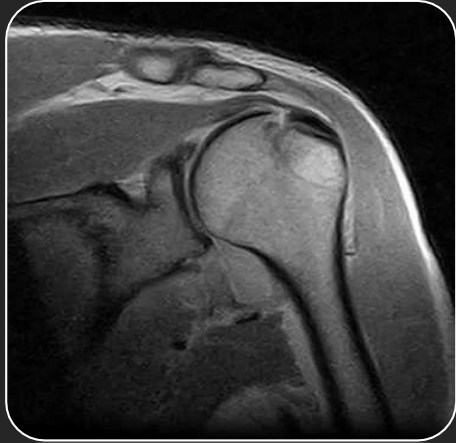

3D HYCE ISO - Axial

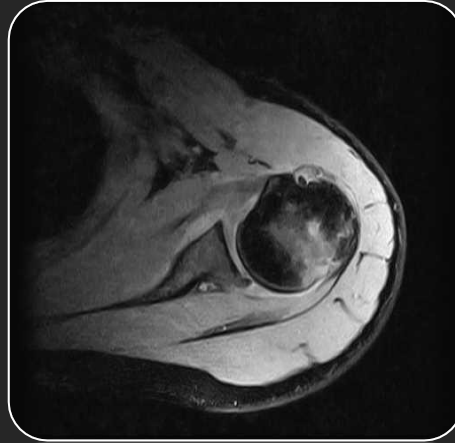


SE T1 - Sagittal

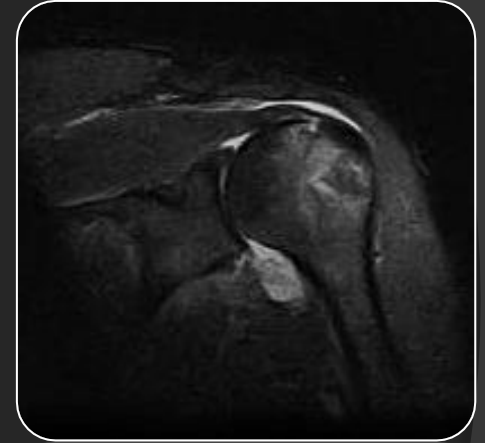
Shoulder: Greater Trochanter Fracture



FSE PD - Coronal

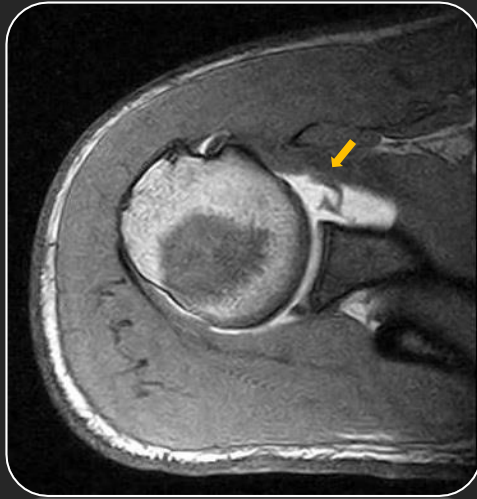

X-Bone T2 (Fat Suppression Echo) -
Axial

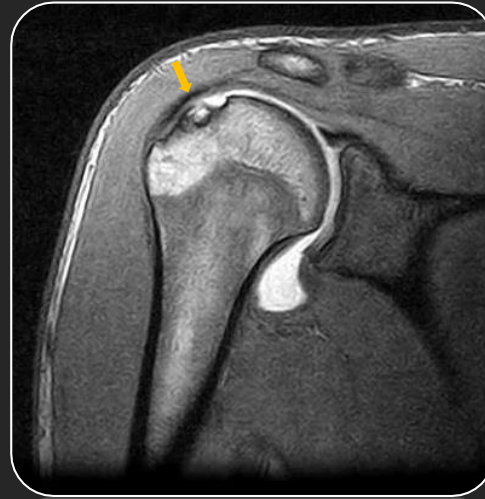

FSTIR - Coronal

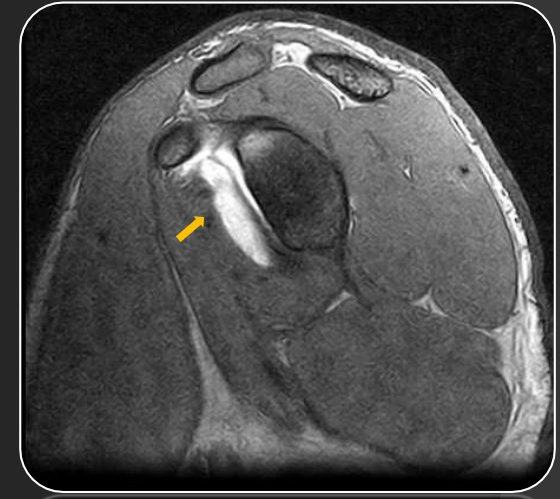Shoulder: Bankart Lesion + Hill Sachs (CM)



3D SHARC (CM) - Axial

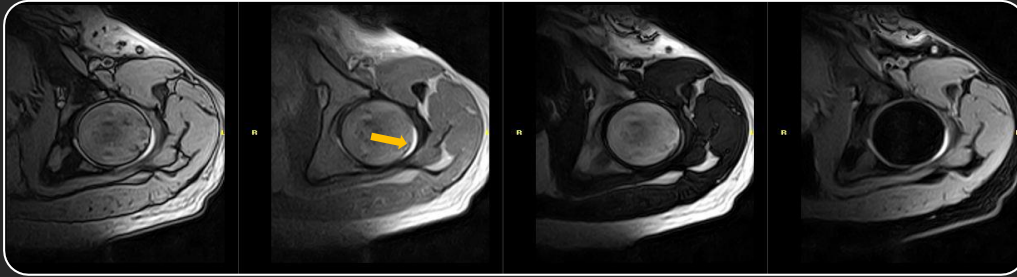


3D SHARC (CM) - Coronal

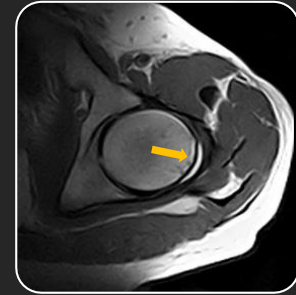


3D SHARC (CM) - Sagittal

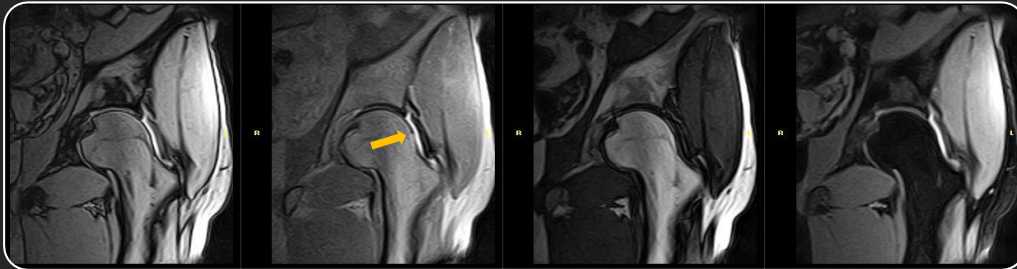
Hip: Labrum Lesion (CM)



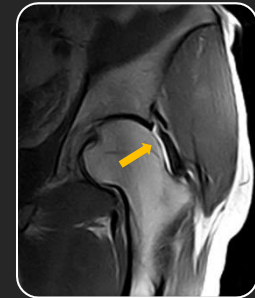X-Bone T2 - Axial



SE T1 (CM) - Axial

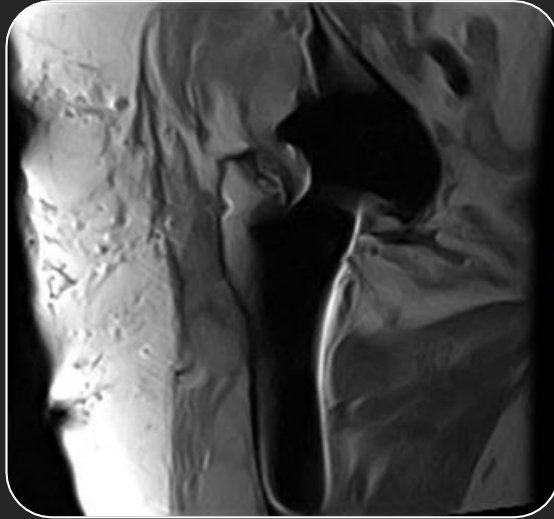


X-Bone T2 - Coronal

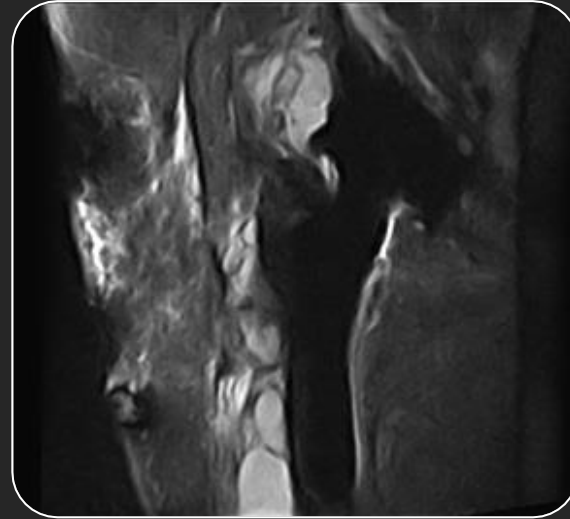


SE T1 (CM) - Coronal

Hip: Replacement Prosthesis w/ MAR

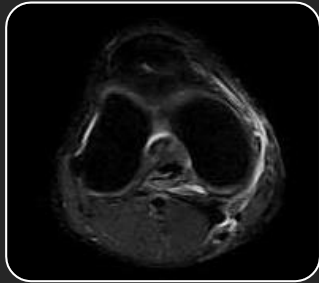


SE T1 (MAR) - Coronal

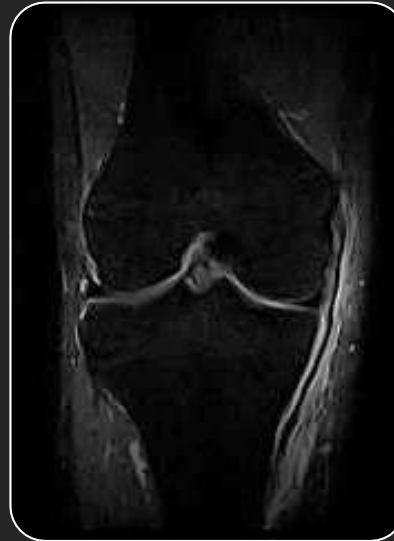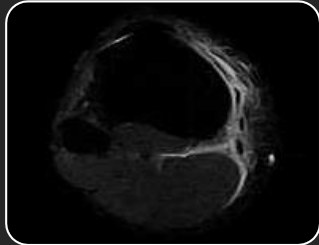


FSTIR (MAR) - Coronal

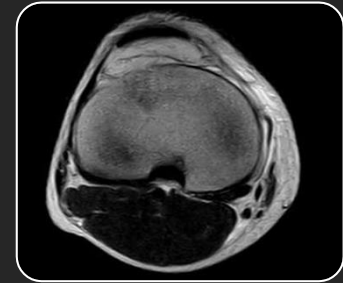Knee: MCL Tear + Pes Anserinus



FSTIR - Axial

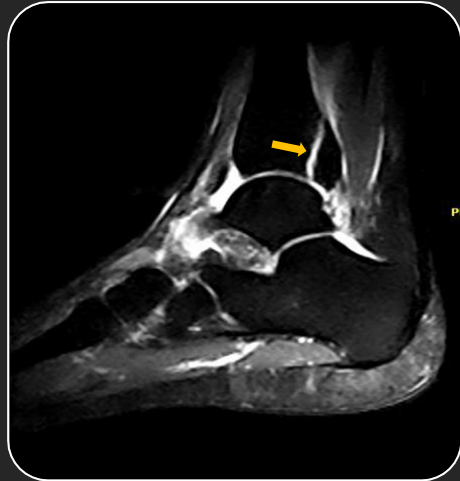

FSTIR - Coronal

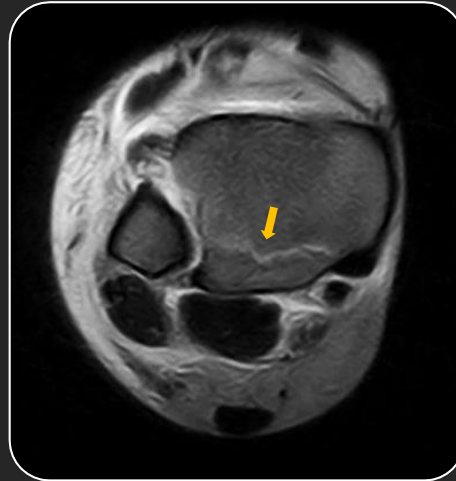

FSE T2 - Axial

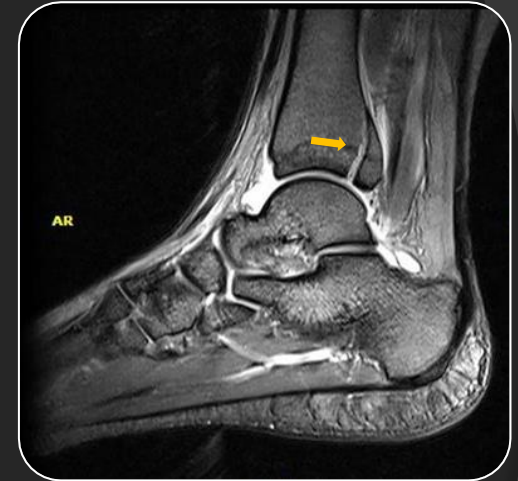Ankle: Tibial Fracture



GE STIR - Sagittal

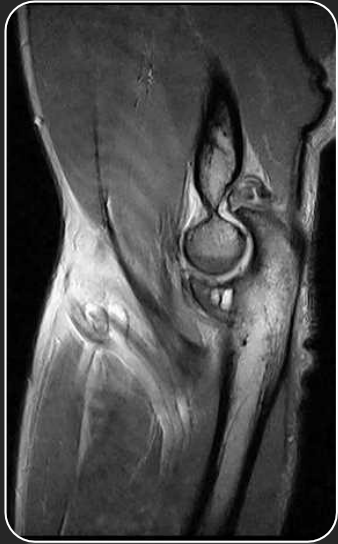

FSE T2 - Axial

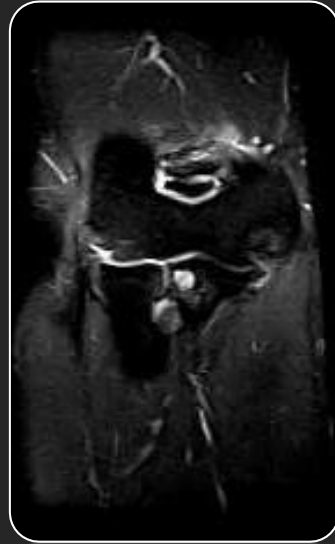


GE T2 - Sagittal

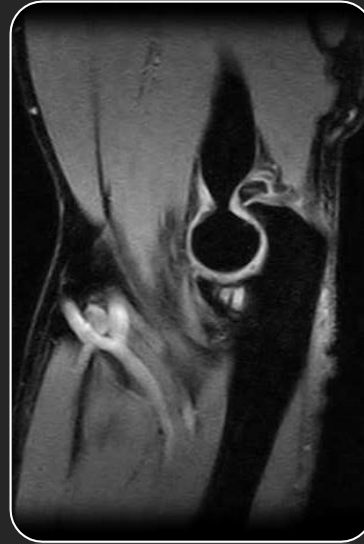
Elbow: Old Fracture



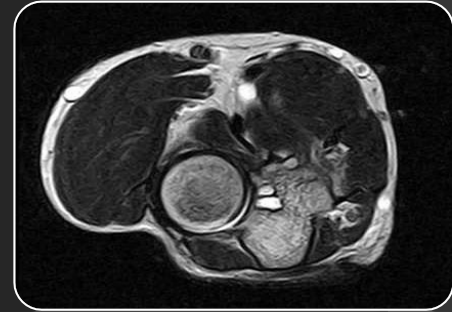GE T2 - Sagittal



FSTIR - Coronal

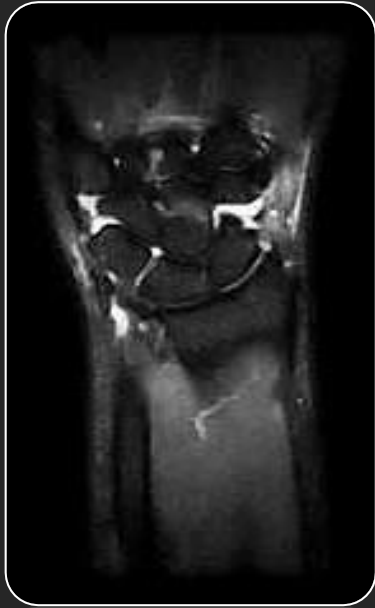

X-Bone T2 (Fat Suppression Echo)
- Sagittal

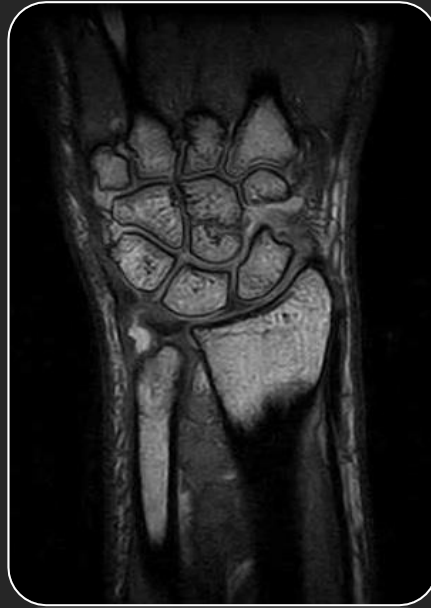

FSE T2 - Axial

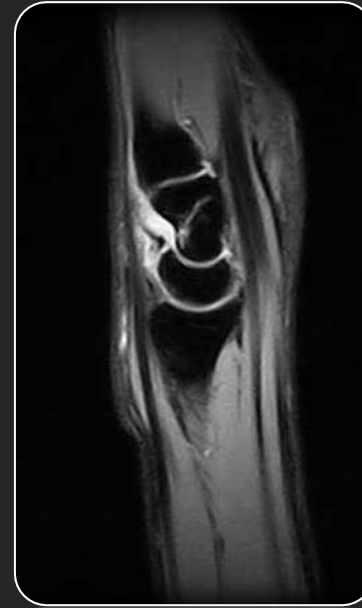Wrist: Capitate Fracture



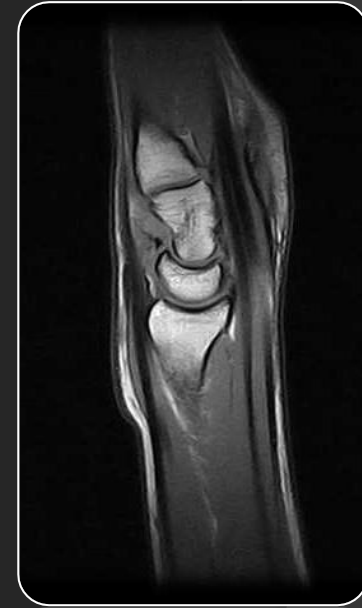GE STIR - Coronal



3D SHARC ISO - Coronal

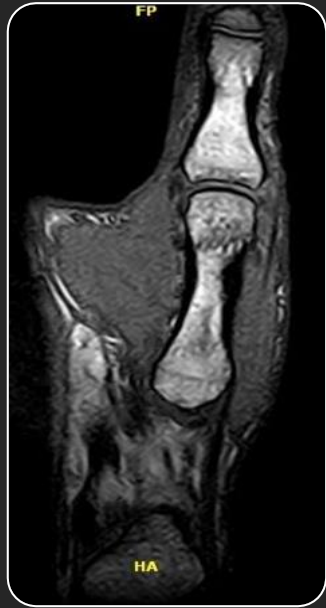

X-Bone T2 (Fat Suppression Echo)
- Sagittal

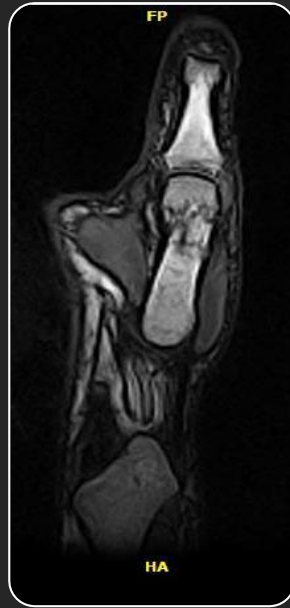


SE T1 - Sagittal

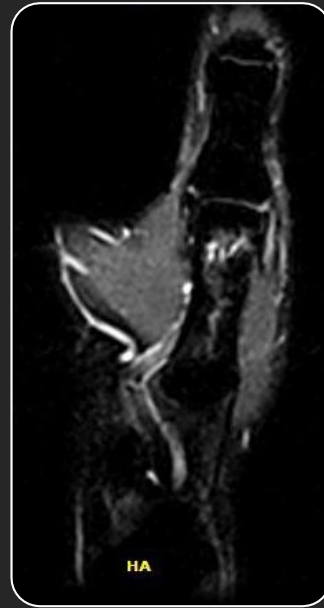
Hand: Phalangeal Fracture



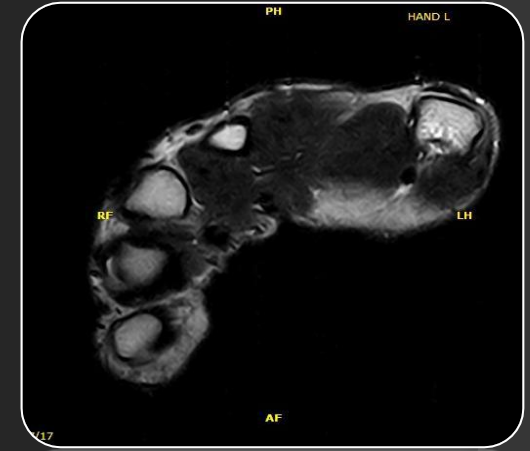
3D SHARC - Coronal



3D SST1 - Coronal

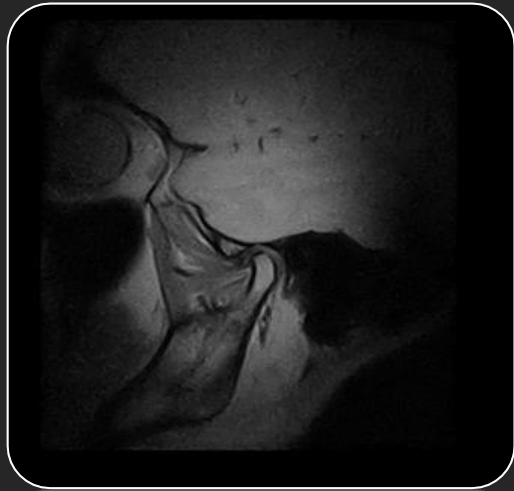

STIR - Coronal

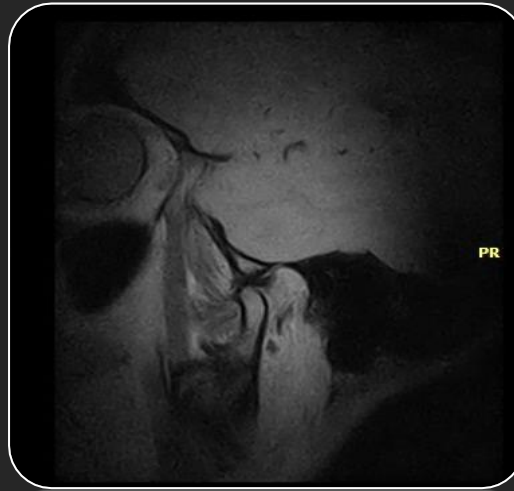


FSE T2 - Axial

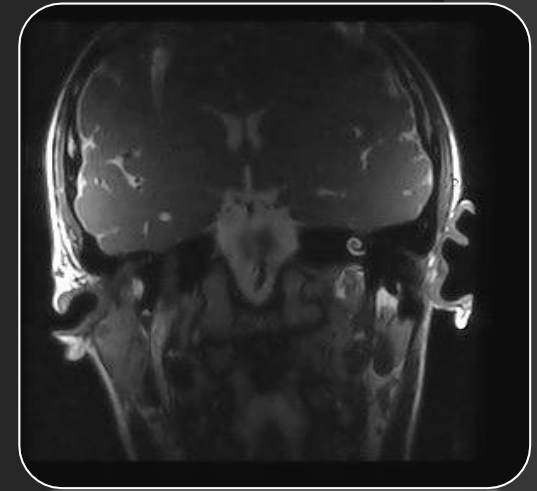
TMJ: Open&Closed Mouth



FSE PD – Closed Mouth

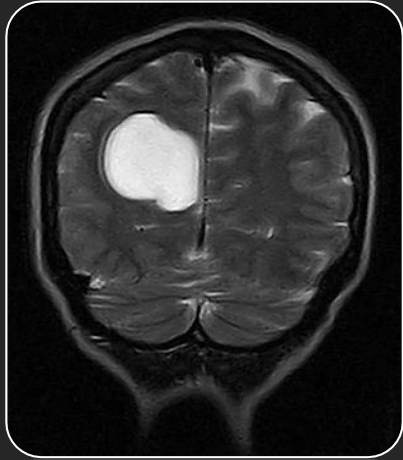


FSE PD – Open Mouth

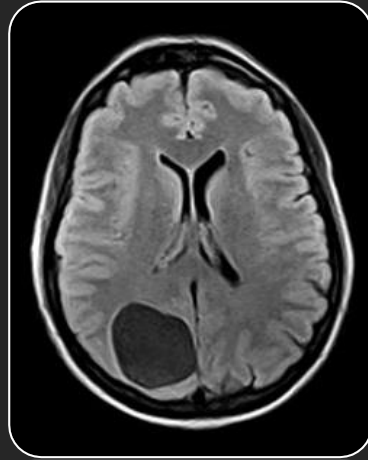


3D HYCE - Coronal

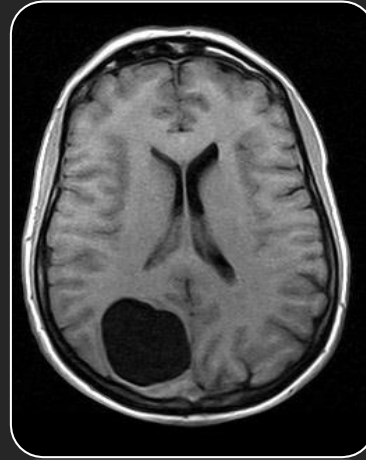
Brain: Neuroganglion Cyst



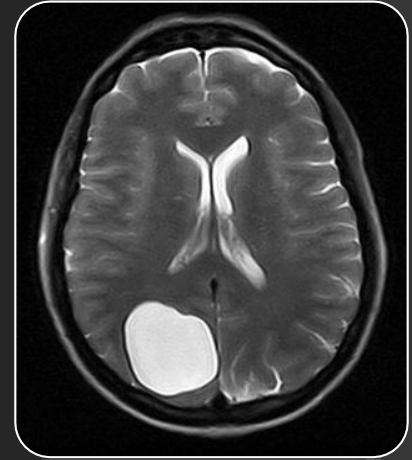FSE T2 - Coronal



FLAIR T2 - Axial

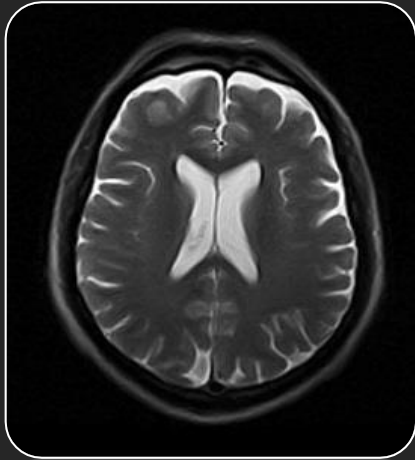


3D SST1 - Axial

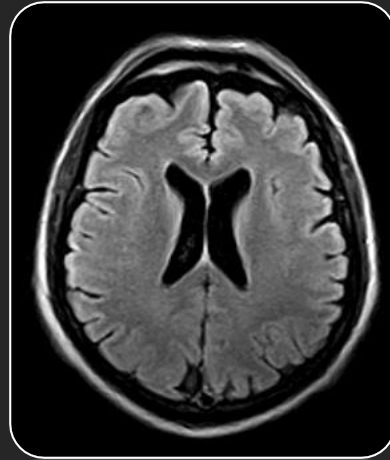


FSE T2 - Axial

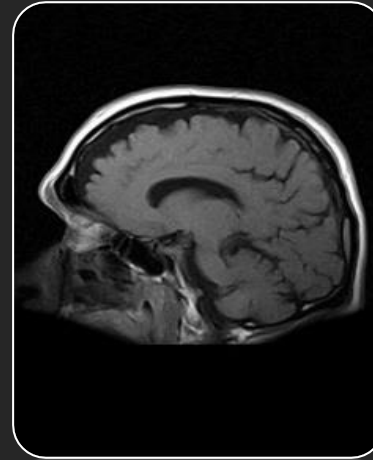
Brain: Focal Cerebral Atrophy



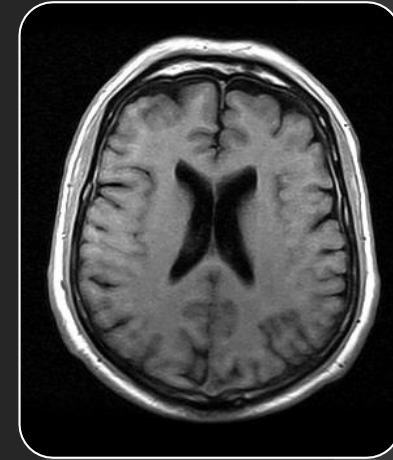
FSE T2 - Axial



FLAIR T2 - Axial

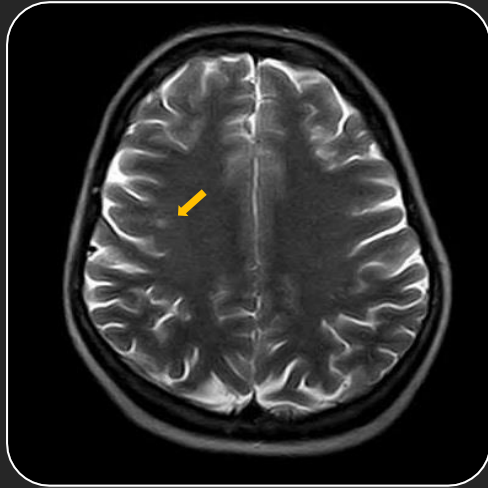


SE T1 - Sagittal

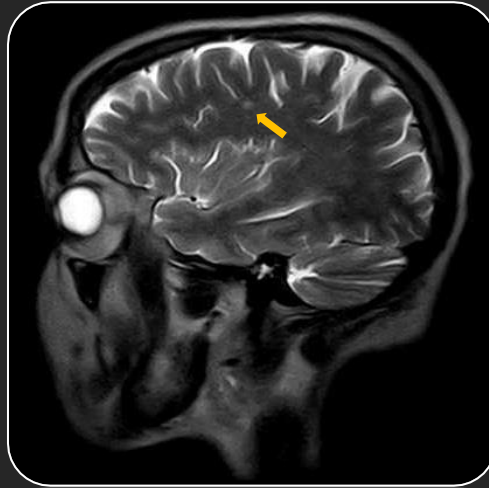


3D SST1 - Axial

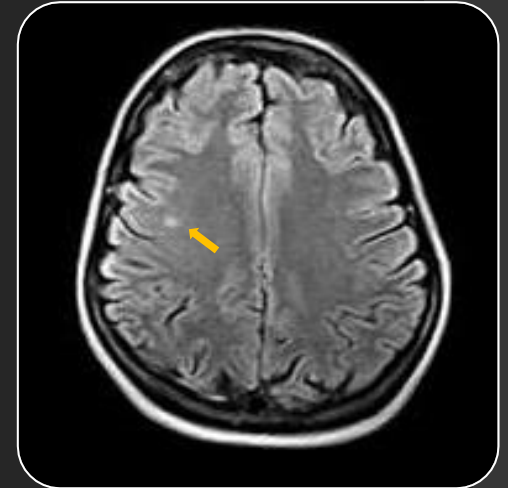
Brain: Lacunar Ischemic




FSE T2 – Axial



FSE T2 – Sagittal



FLAIR - Axial

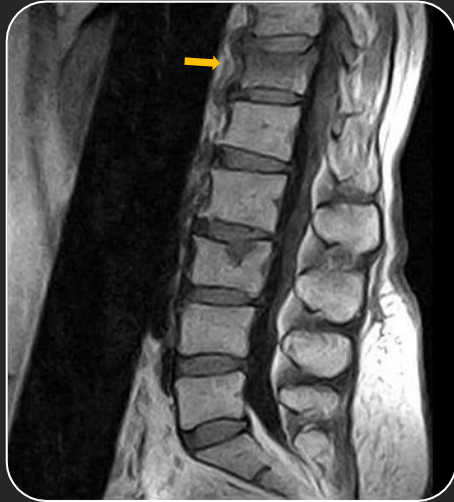


eScan brio
eXP Technology

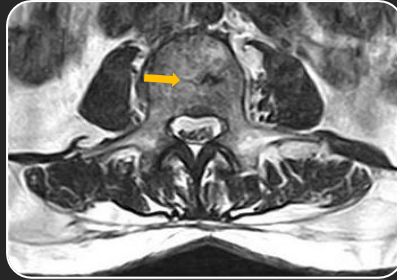
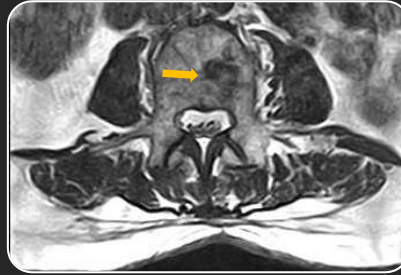
Changing the perspective in MRI



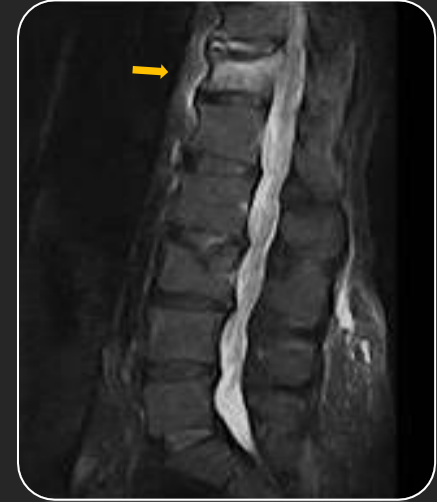L-Spine: Vertebral Fracture



SE T1 - Sagittal

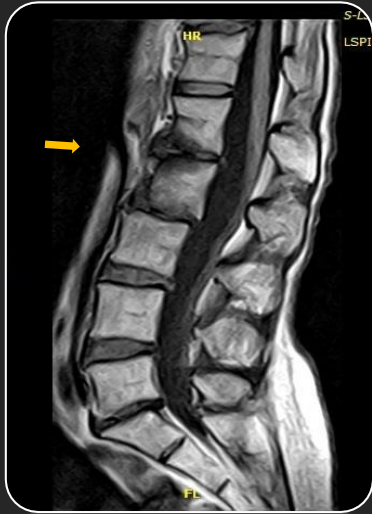

3D HYCE ISO - Axial

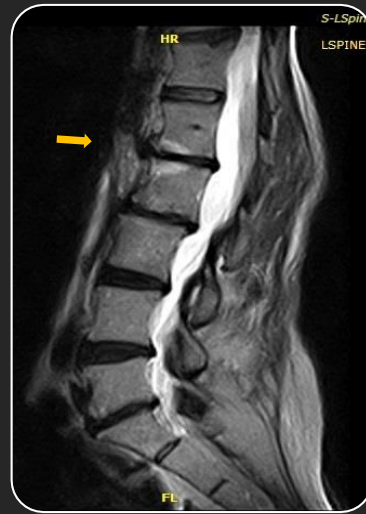
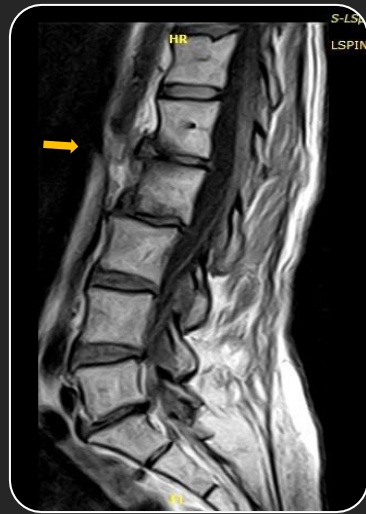
FSTIR - Sagittal

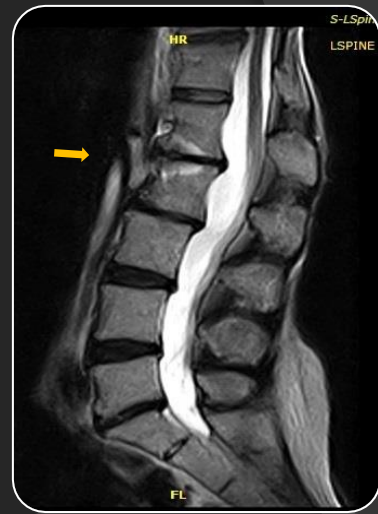L-Spine: Disc Degeneration (Modic I)



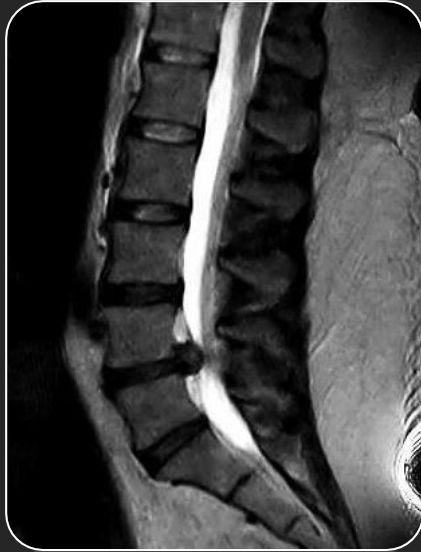SE T1 - Sagittal



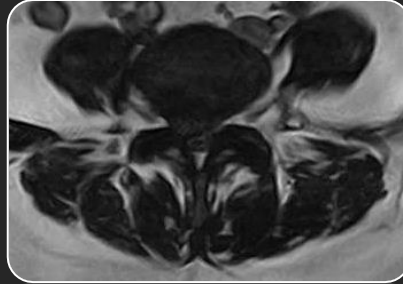
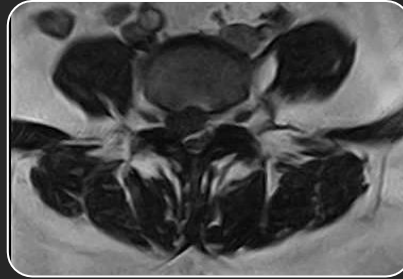
FSE T2 - Sagittal



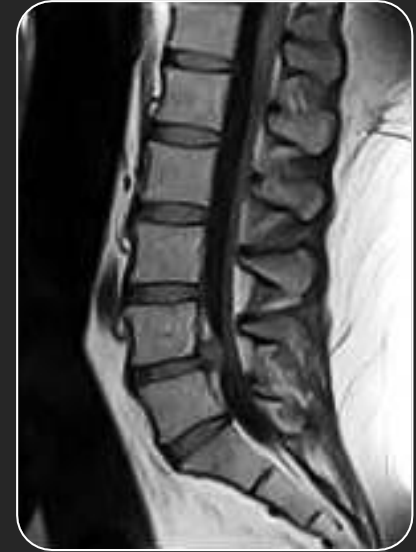L-Spine: Disc Herniation (Obese Patient)



FSE T2 - Sagittal

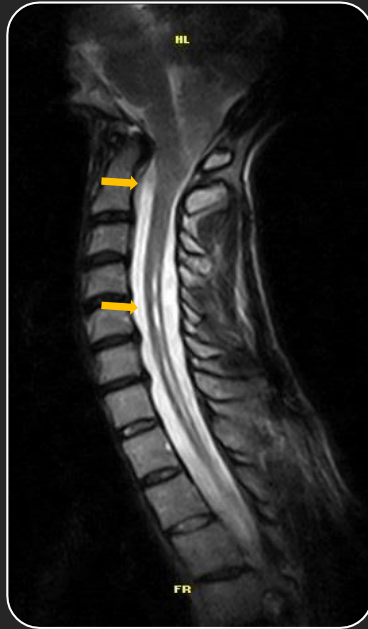

3D HYCE ISO - Axial

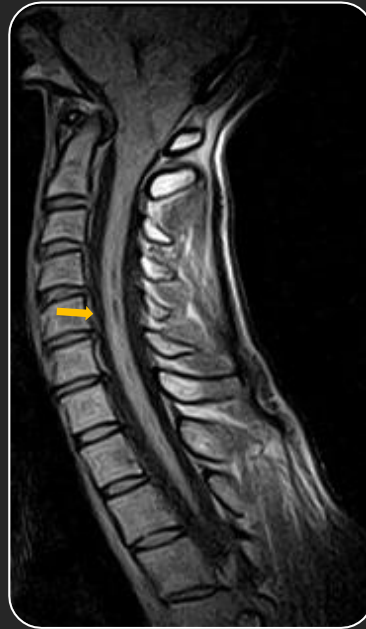

SE T1 - Sagittal

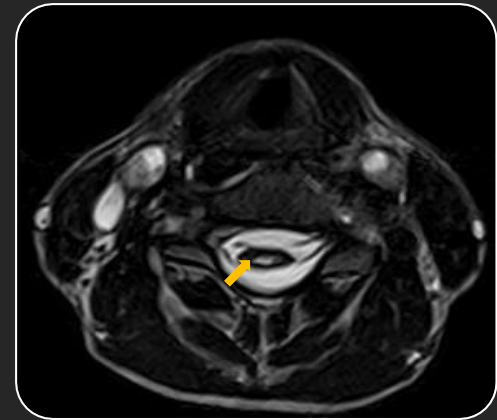
C-Spine: Arnold Chiari + Syringomyelia



FSE T2 - Sagittal

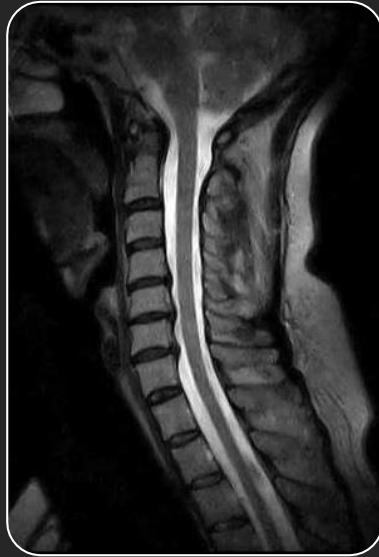

SE T1 - Sagittal

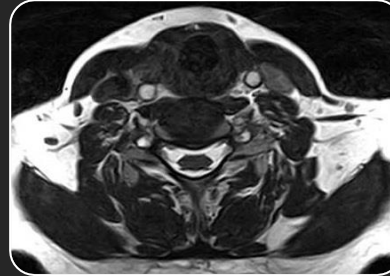
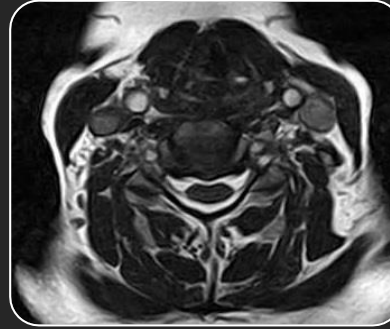


3D HYCE ISO - Axial

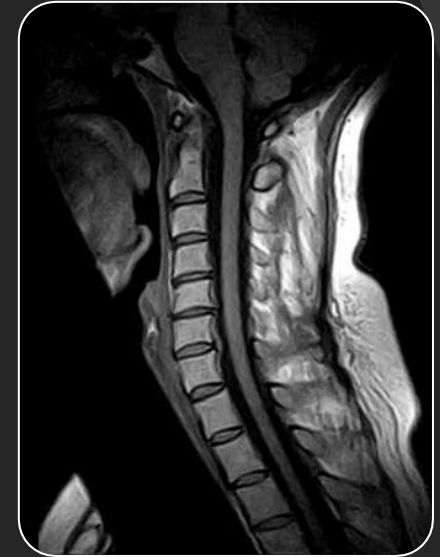C-Spine: Bulging Disc



FSE T2 - Sagittal

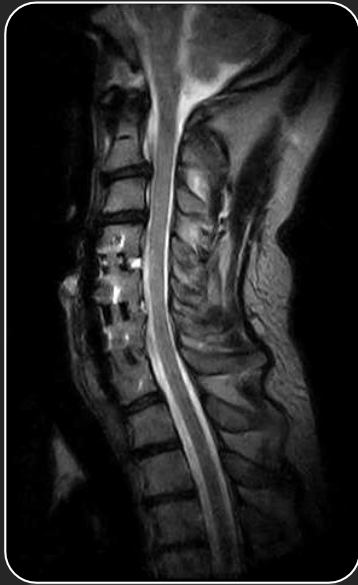

3D HYCE ISO - Axial

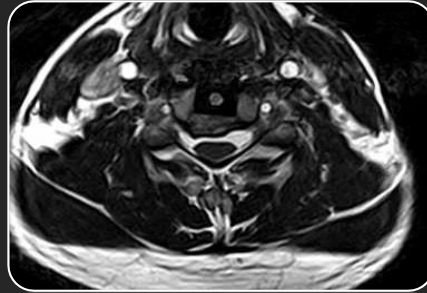
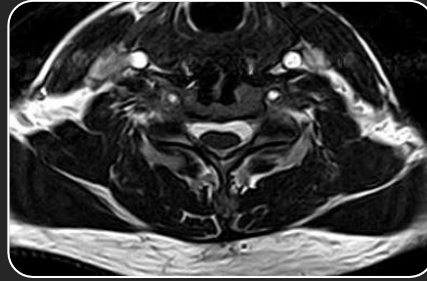


SE T1 - Sagittal

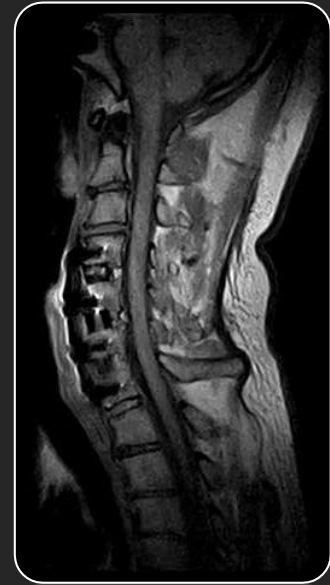C-Spine: Postsurgical Fixation (MAR)



FSE T2 - Sagittal

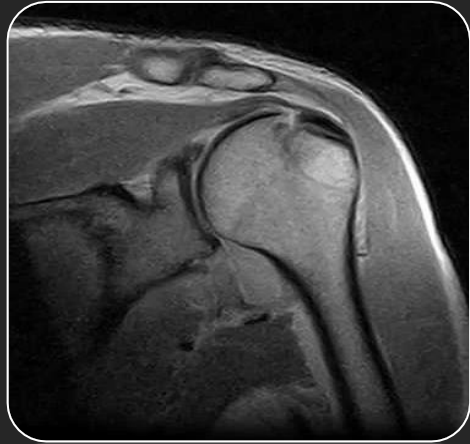

3D HYCE ISO - Axial

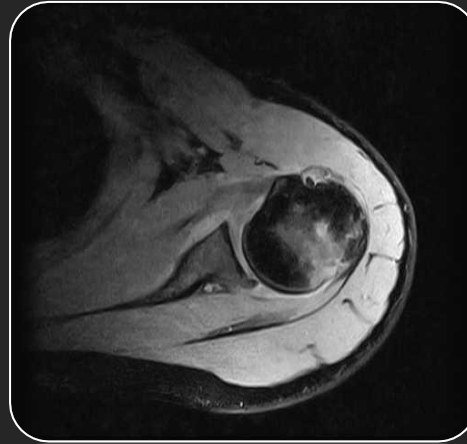


SE T1 - Sagittal

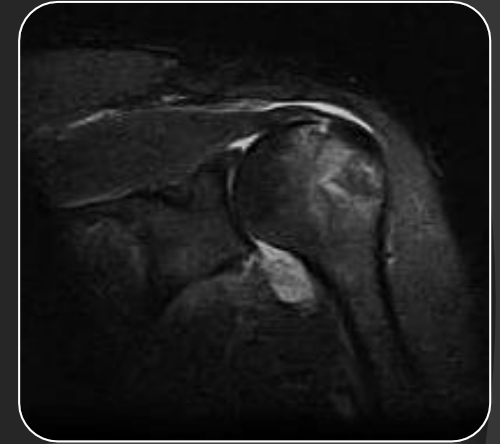
Shoulder: Greater Trochanter Fracture



FSE PD - Coronal

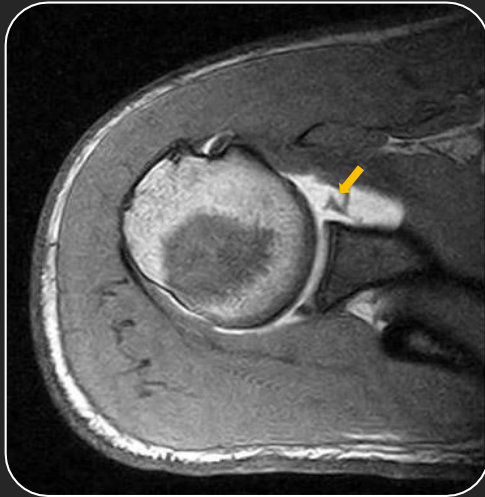

X-Bone T2 (Fat Suppression Echo) -
Axial

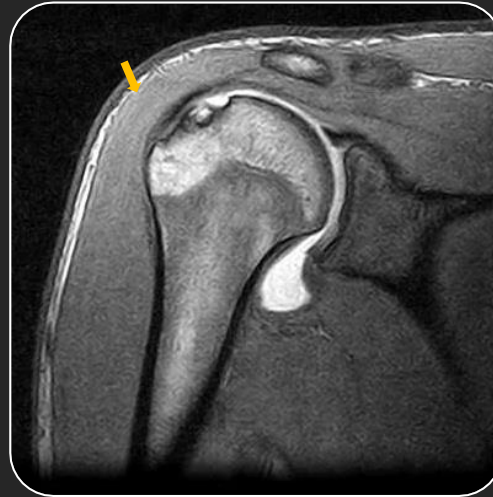

FSTIR - Coronal

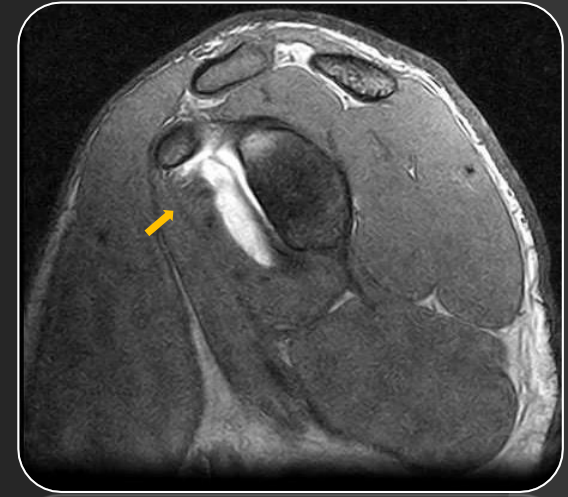Shoulder: Bankart Lesion + Hill Sachs (CM)



3D SHARC (CM) - Axial

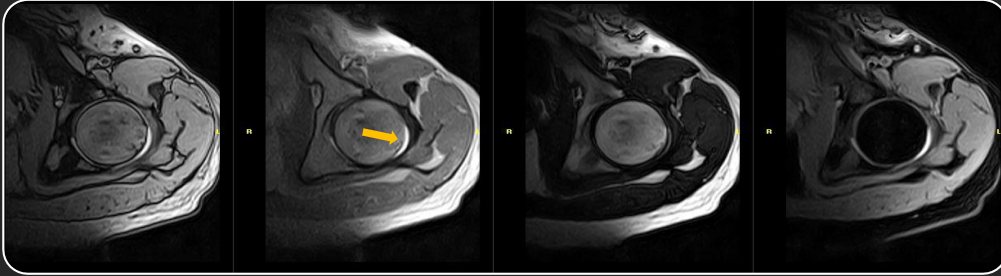


3D SHARC (CM) - Coronal

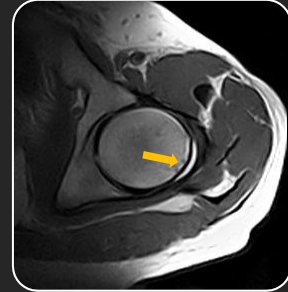

3D SHARC (CM) - Sagittal

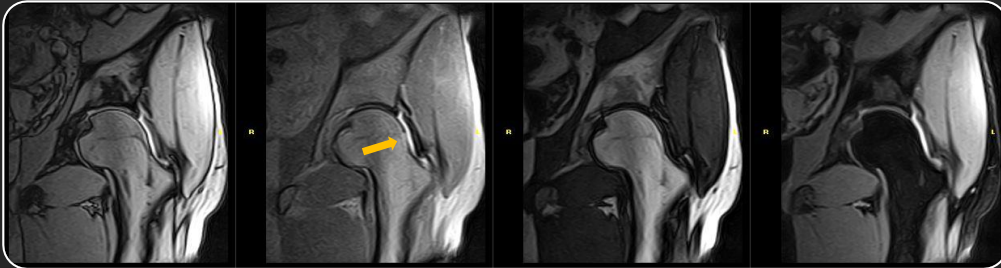
Hip: Labrum Lesion (CM)



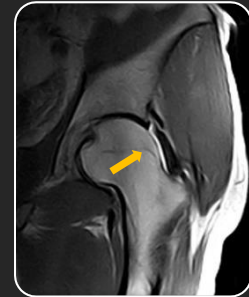
X-Bone T2 - Axial



SE T1 (CM) - Axial

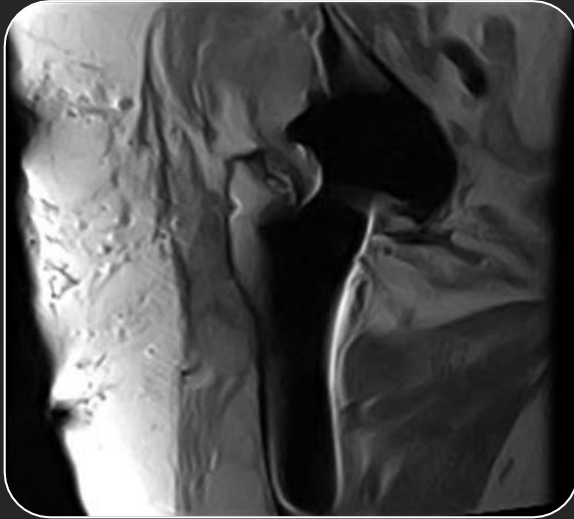


X-Bone T2 - Coronal

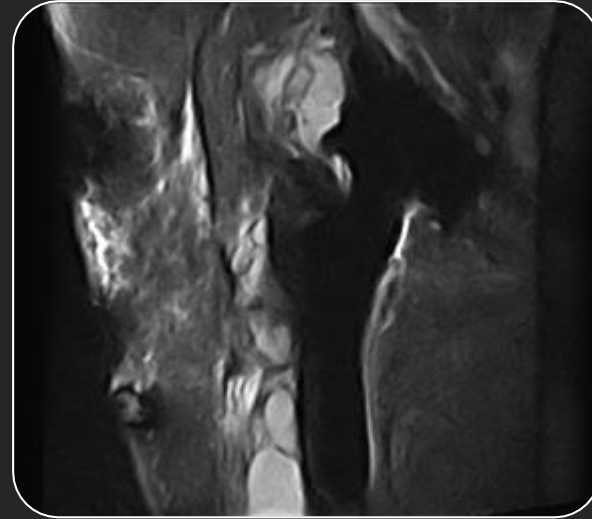


SE T1 (CM) - Coronal

Hip: Replacement Prosthesis w/ MAR

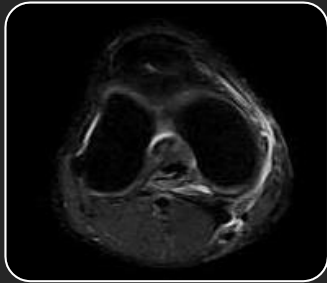


SE T1 (MAR) - Coronal

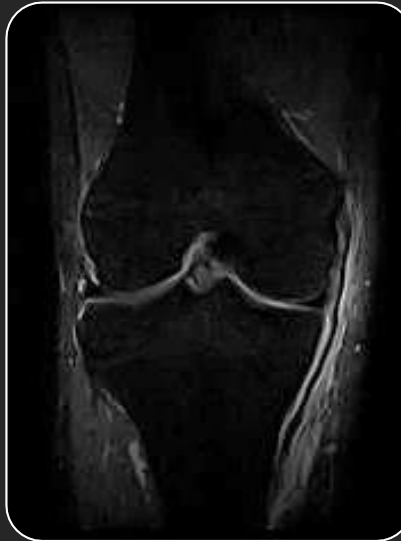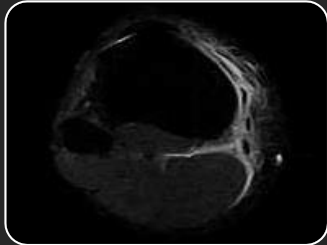


FSTIR (MAR) - Coronal

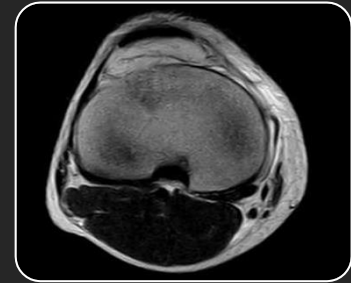Knee: MCL Tear + Pes Anserinus



FSTIR - Axial

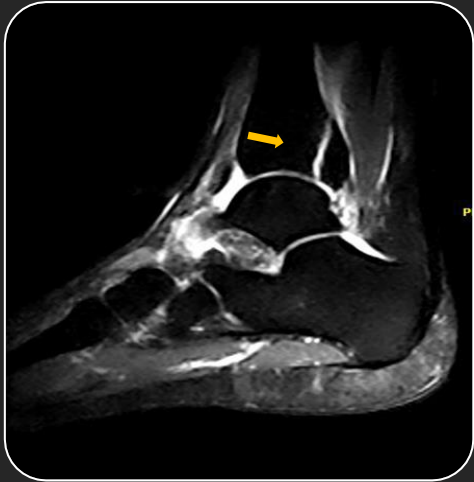

FSTIR - Coronal

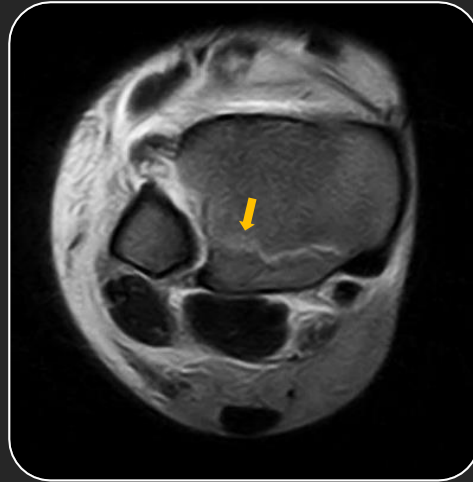

FSE T2 - Axial

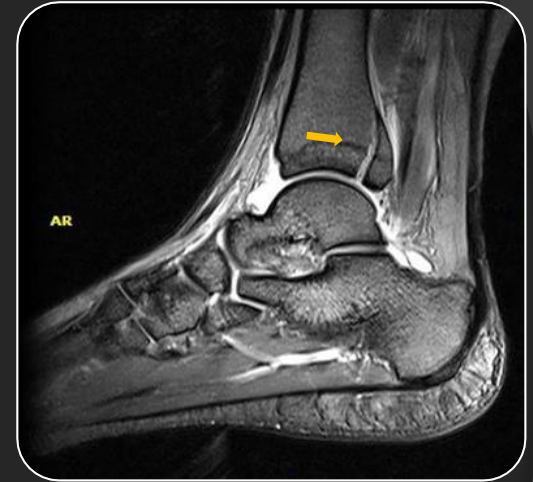Ankle: Tibial Fracture



GE STIR - Sagittal

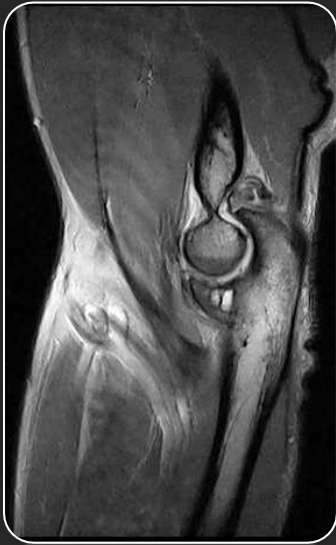

FSE T2 - Axial

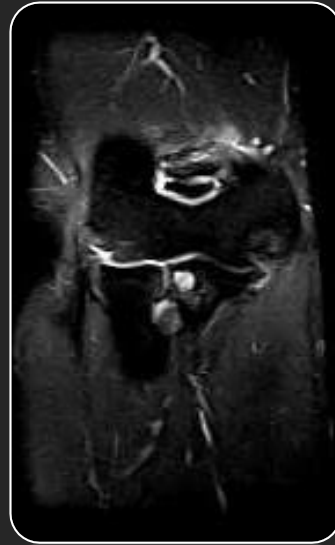


GE T2 - Sagittal

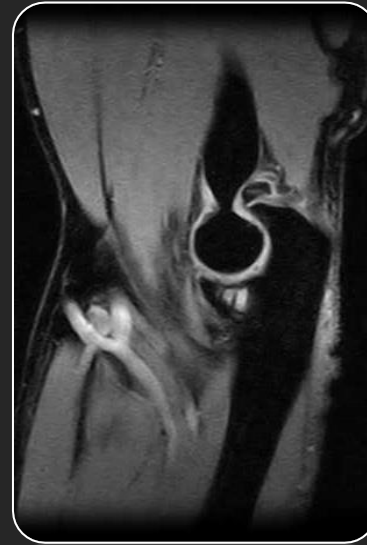
Elbow: Old Fracture



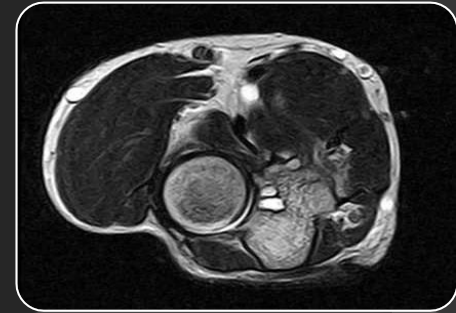GE T2 - Sagittal



FSTIR - Coronal



X-Bone T2 (Fat Suppression Echo)
- Sagittal



FSE T2 - Axial

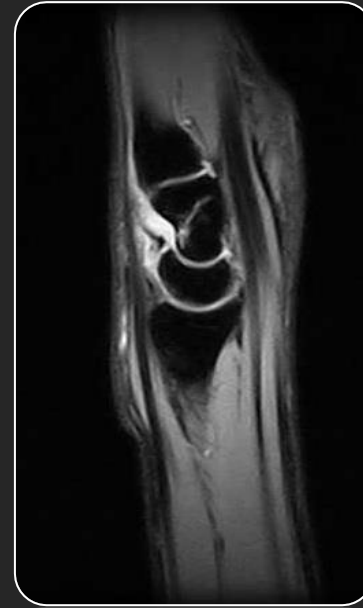Wrist: Capitate Fracture



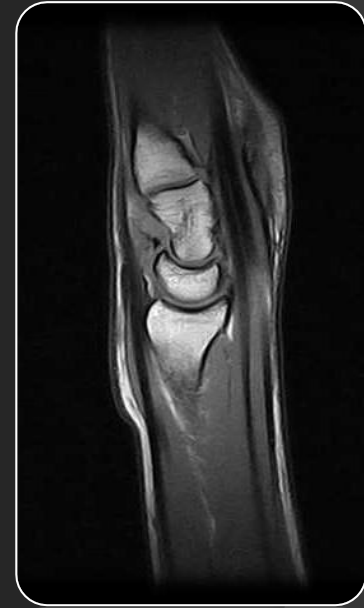GE STIR - Coronal



3D SHARC ISO - Coronal

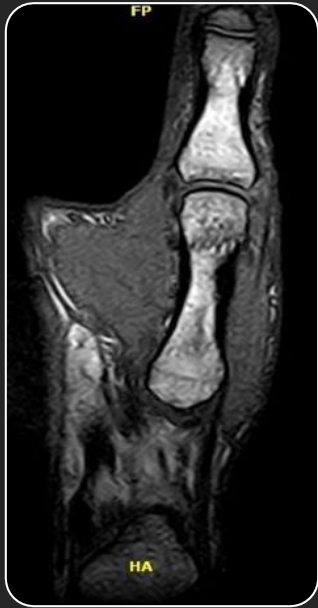

X-Bone T2 (Fat Suppression Echo)
- Sagittal

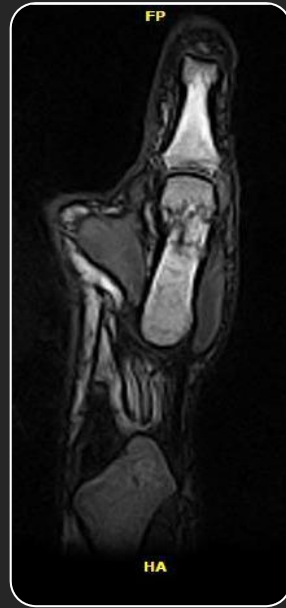


SE T1 - Sagittal

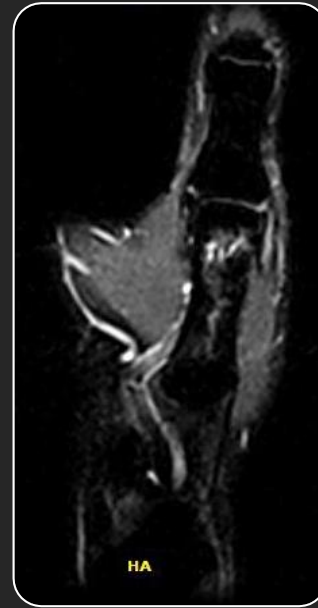
Hand: Phalangeal Fracture



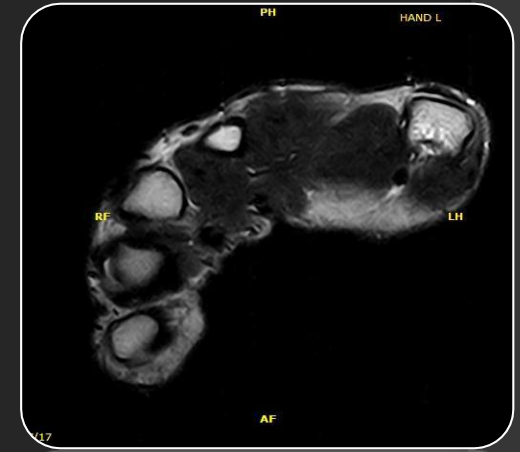
3D SHARC - Coronal



3D SST1 - Coronal

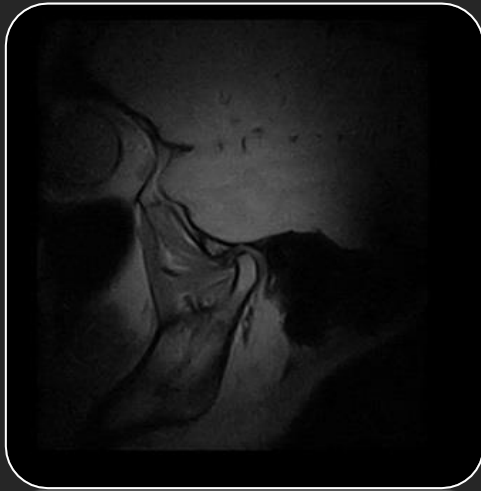

STIR - Coronal

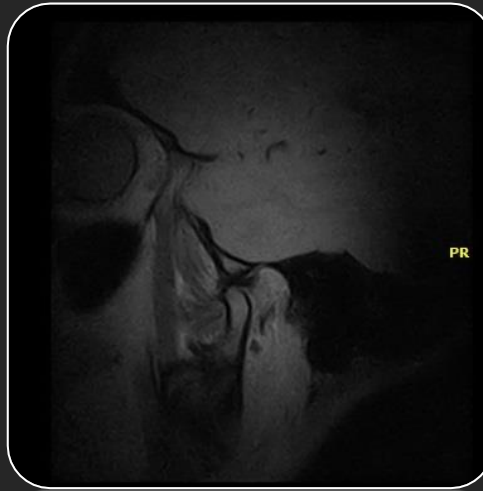


FSE T2 - Axial

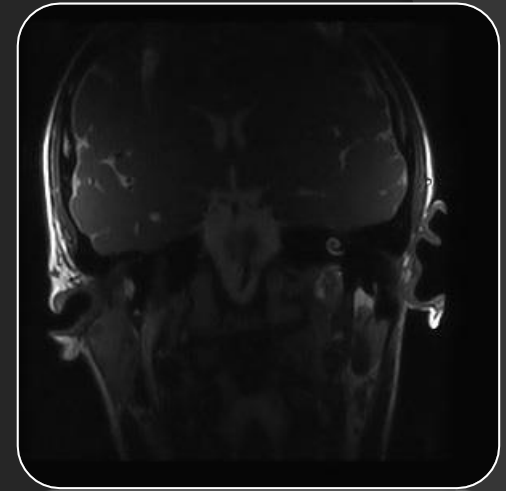
TMJ: Open&Closed Mouth



FSE PD – Closed Mouth

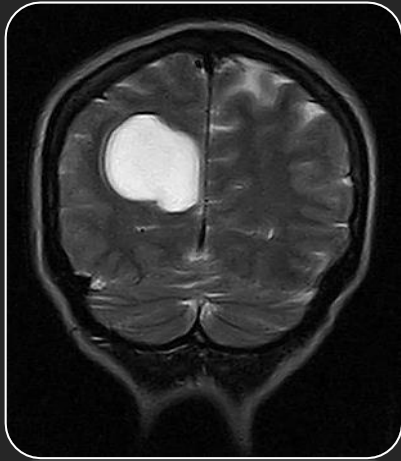


FSE PD – Open Mouth

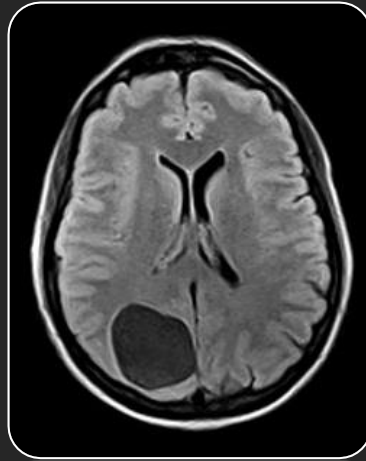


3D HYCE - Coronal

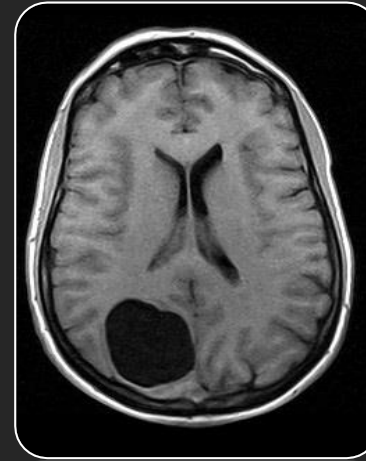
Brain: Neuroganglion Cyst



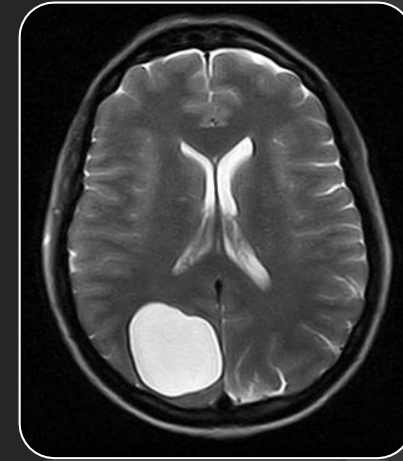
FSE T2 - Coronal



FLAIR T2 - Axial

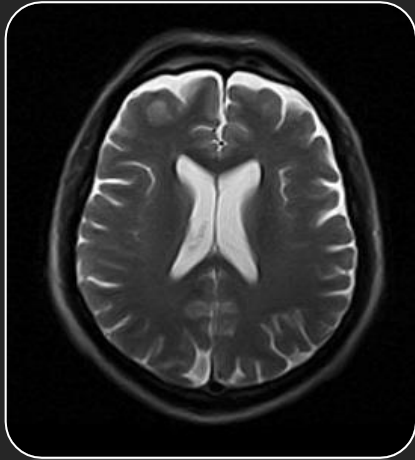


3D SST1 - Axial

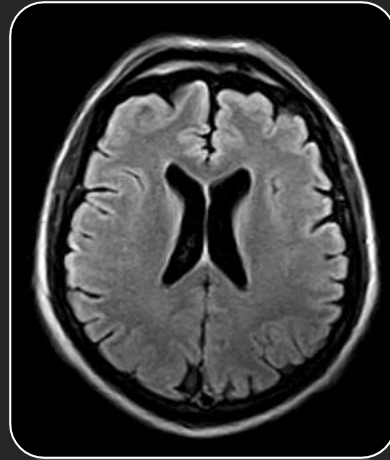


FSE T2 - Axial

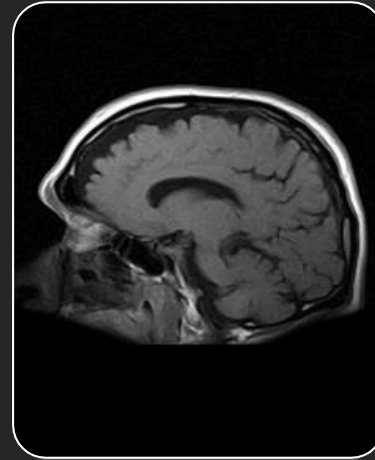
Brain: Focal Cerebral Atrophy



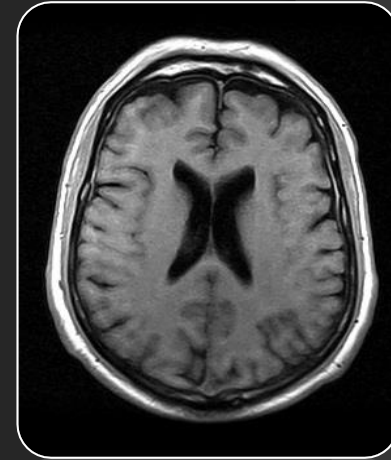
FSE T2 - Axial



FLAIR T2 - Axial

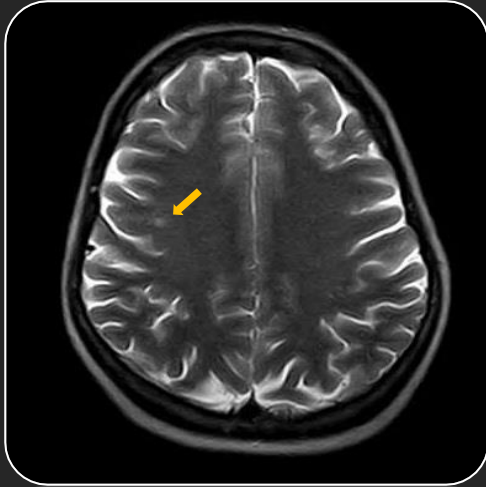


SE T1 - Sagittal

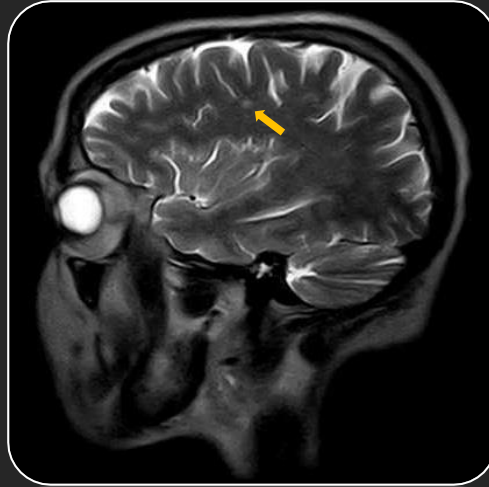


3D SST1 - Axial

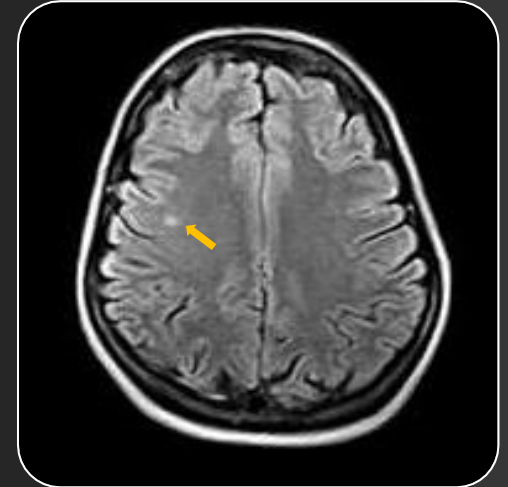
Brain: Lacunar Ischemic



FSE T2 – Axial

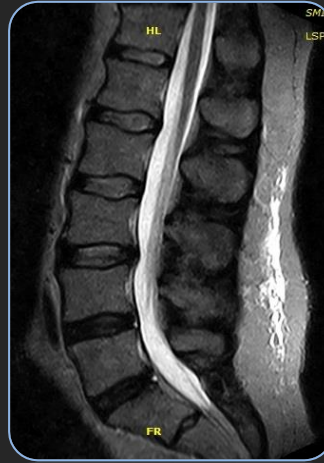

FSE T2 – Sagittal

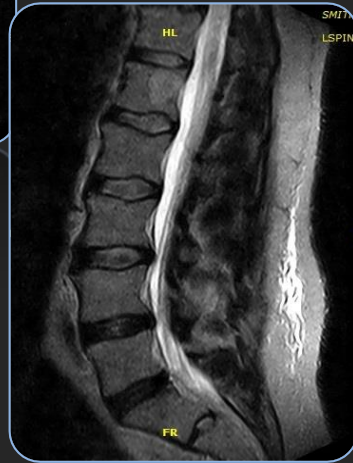

FLAIR - Axial

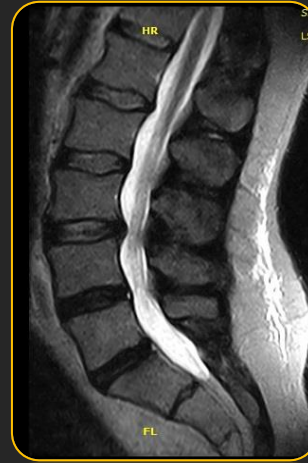L-Spine: Disc WB Modifications



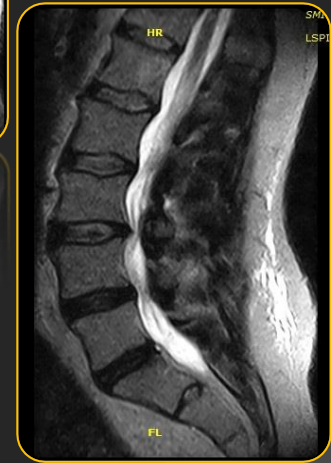Supine



FSE T2
Sagittal



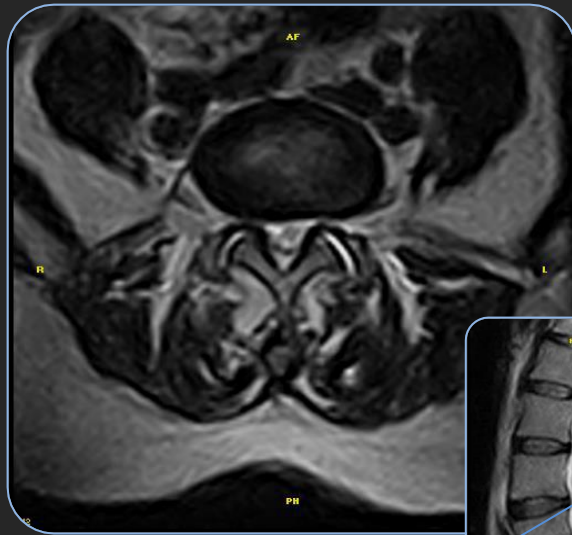
Weight Bearing



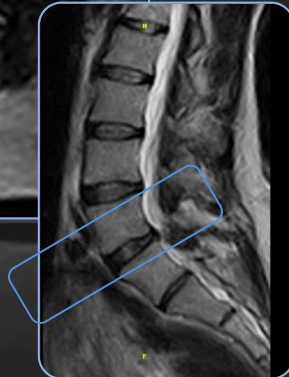FSE T2
Sagittal

L-Spine: Facet Joint Instability (WB)

 Supine

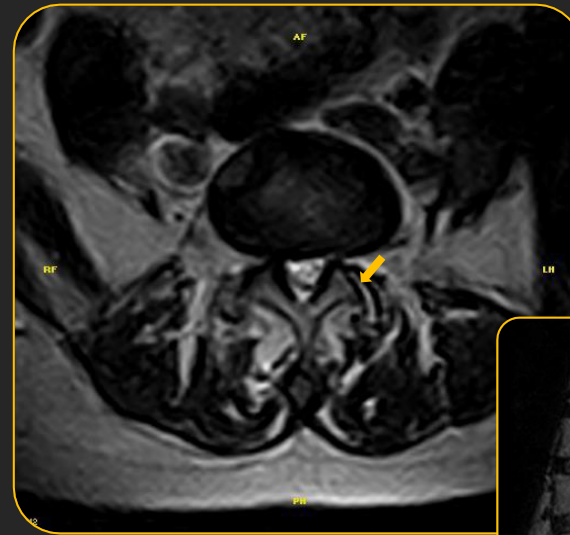


FSE T2 - Axial

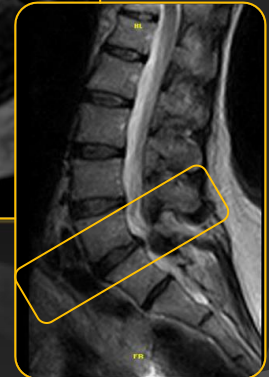


FSE T2 - Sagittal

 Weight Bearing



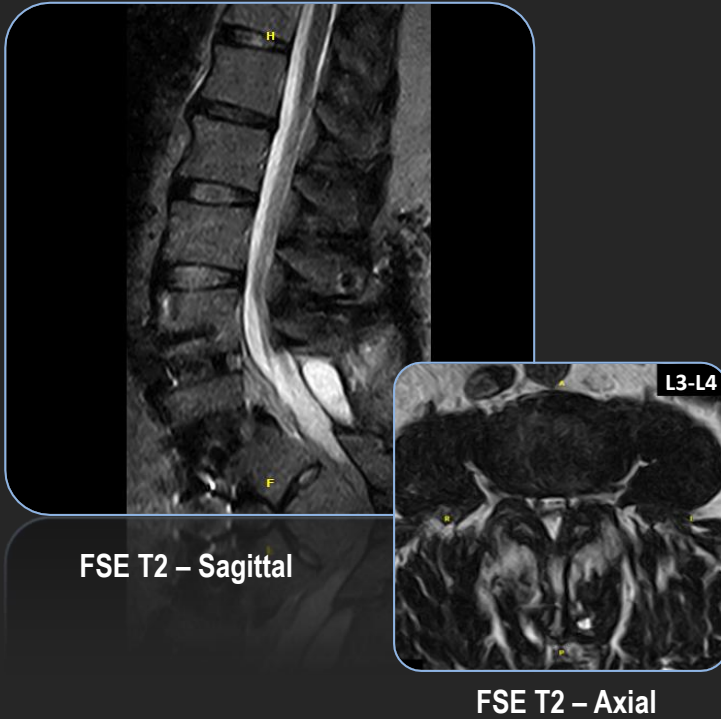
FSE T2 - Axial



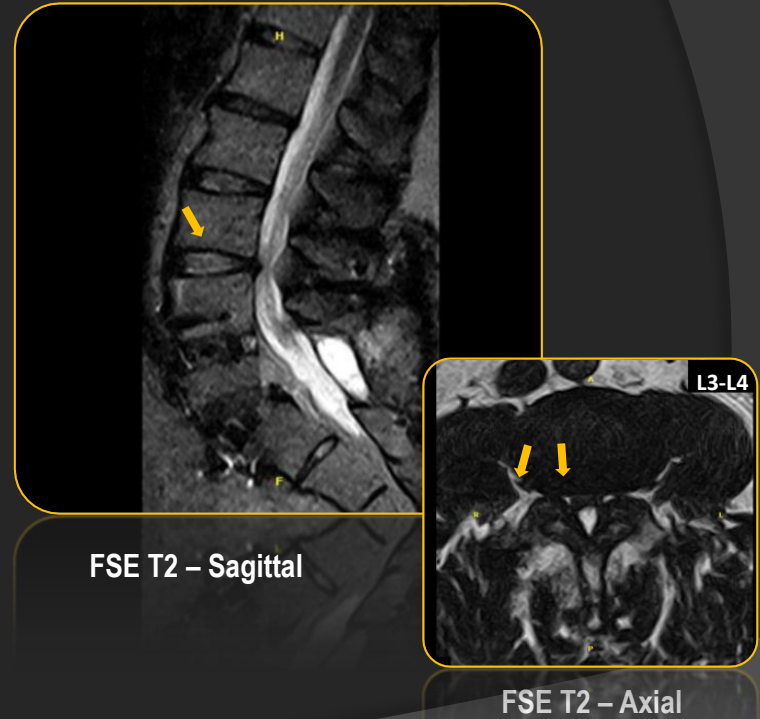
FSE T2 - Sagittal

L-Spine: Post-Surgery (WB)

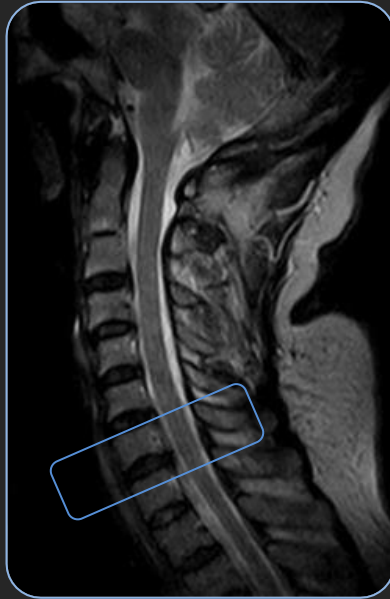
 Supine



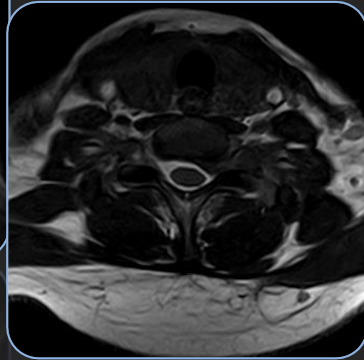
 Weight Bearing



C-Spine: Disc Protrusion (WB)

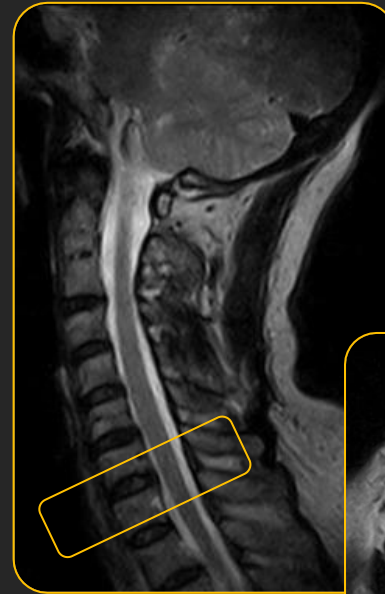

Supine

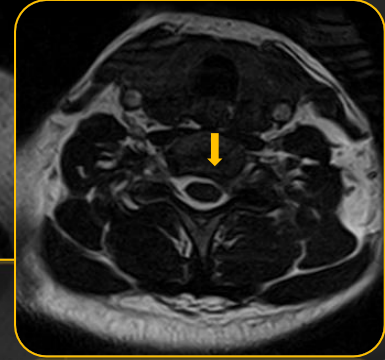


3D HYCE – Axial

FSE T2 – Sagittal



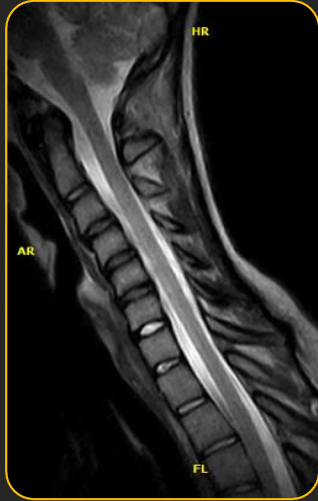Weight Bearing



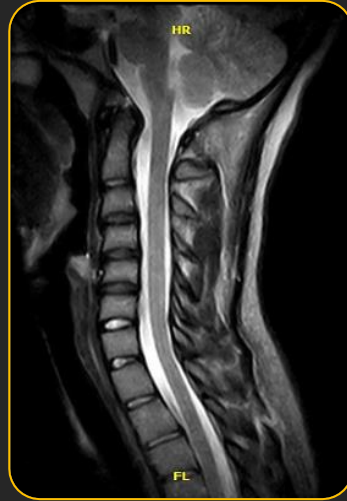3D HYCE – Axial

FSE T2 – Sagittal

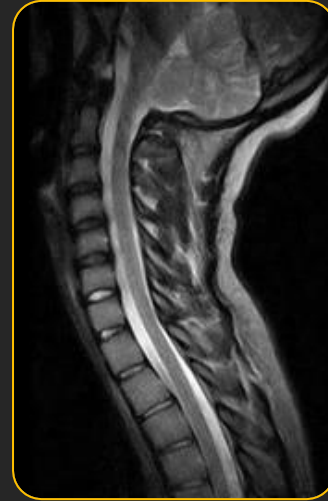C-Spine: Flexion & Extension



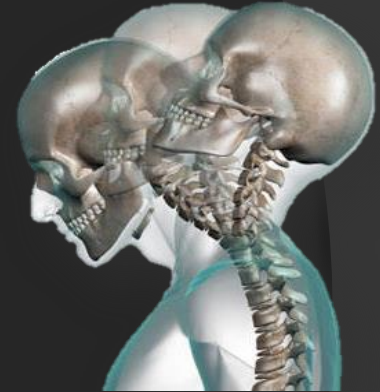FSE T2 – Flexion



FSE T2 – Neutral Position



FSE T2 - Extension

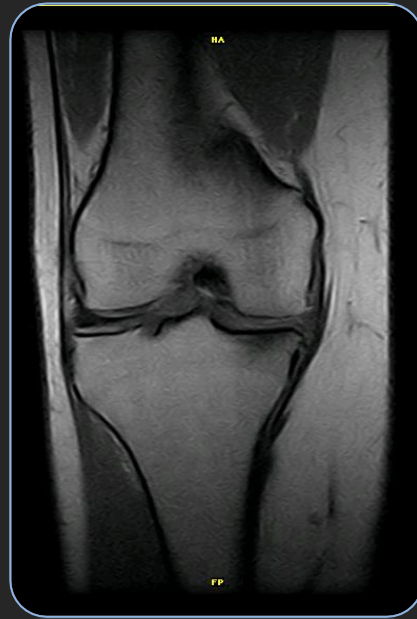

Weight Bearing

Knee: Overloading and Ligament Laxity



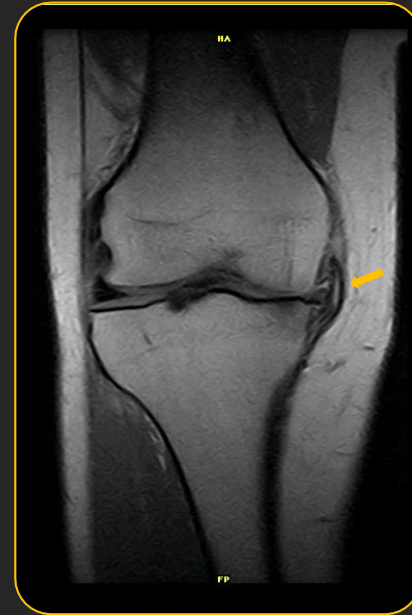
Supine



SE T1 – Coronal

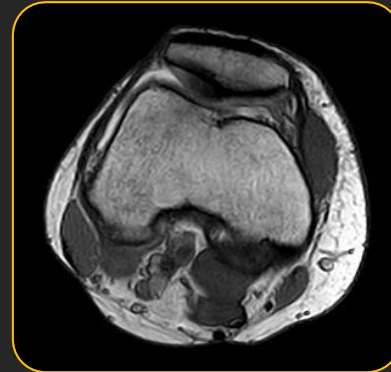
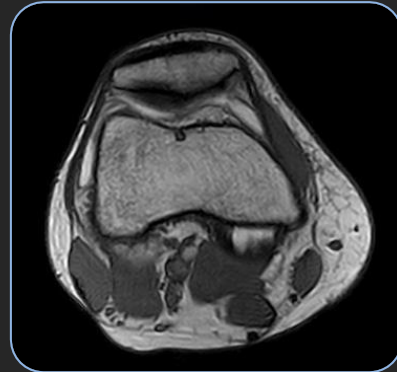


Weight Bearing

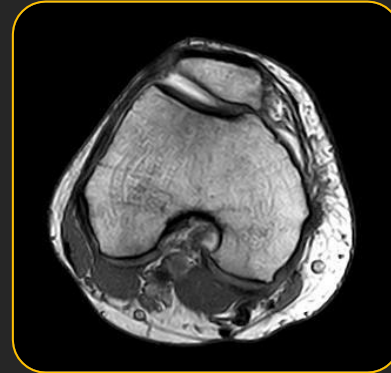
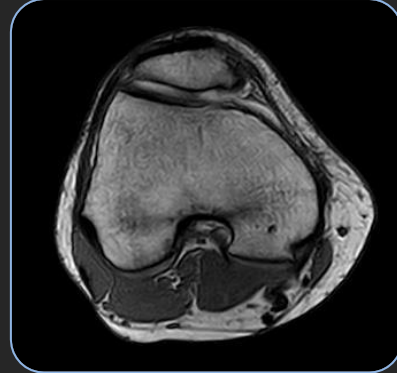


SE T1 – Coronal

Knee: Medial Impingement Femoro-Patellar Joint



Supine



Weight Bearing

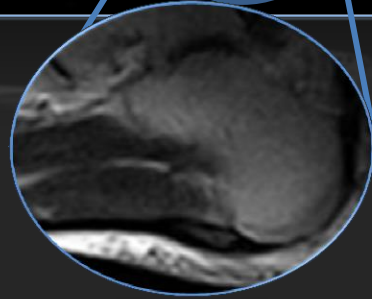
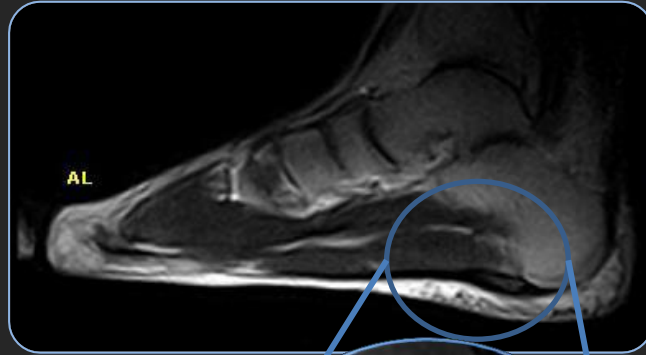
SE T1 - Axial

SE T1 - Axial

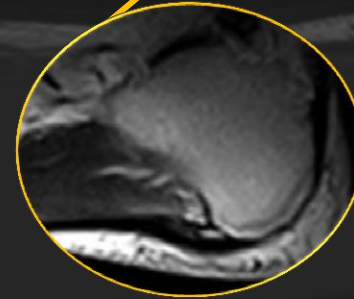
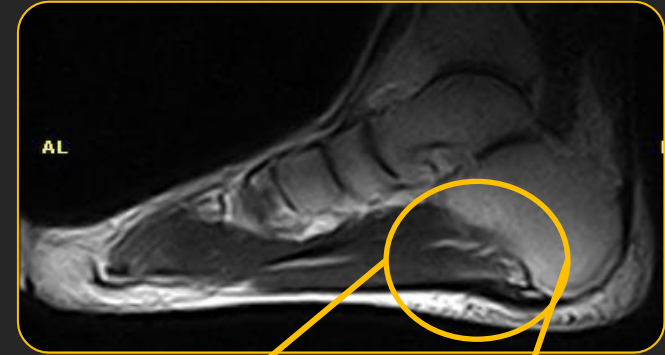Ankle: Plantar Fasciitis Tear



Supine

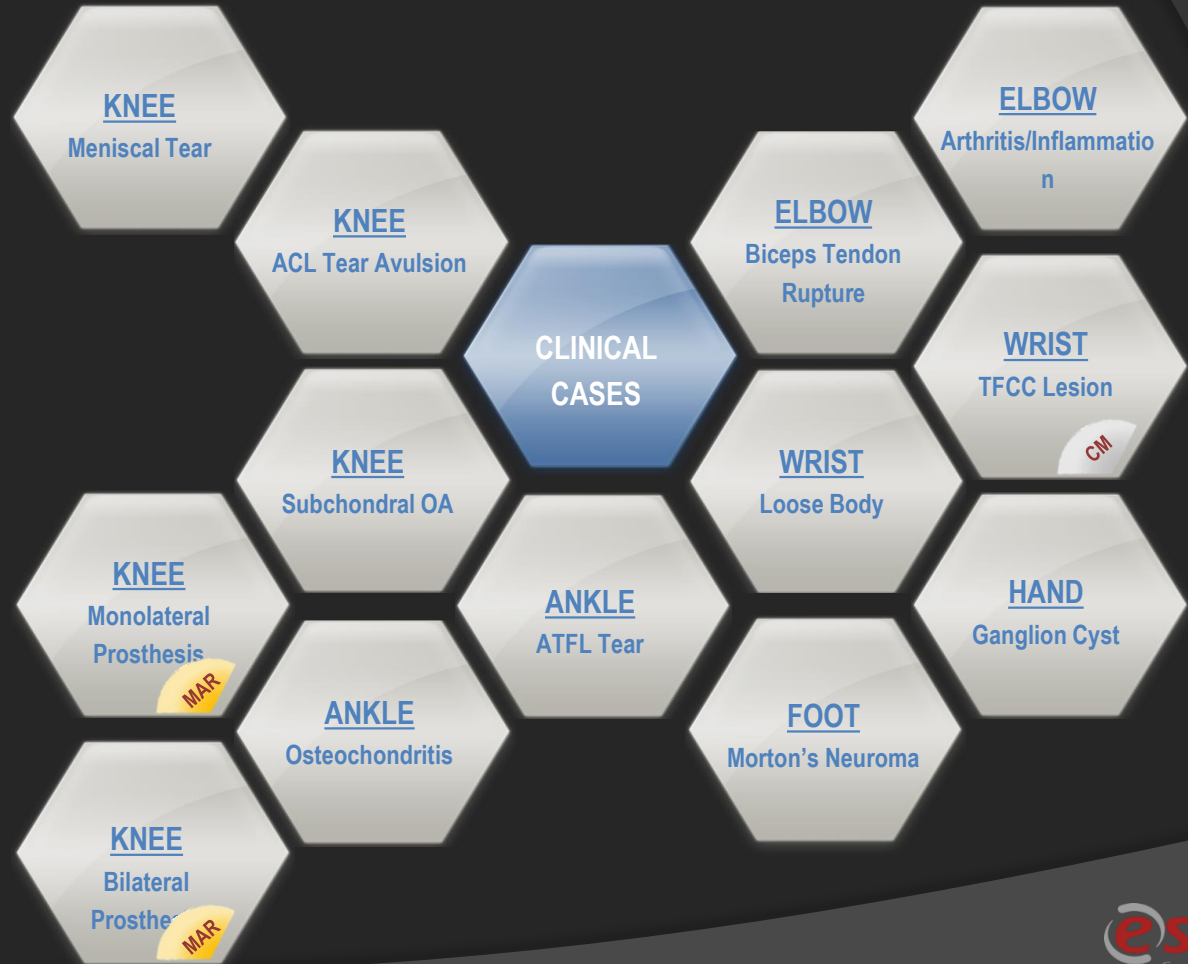

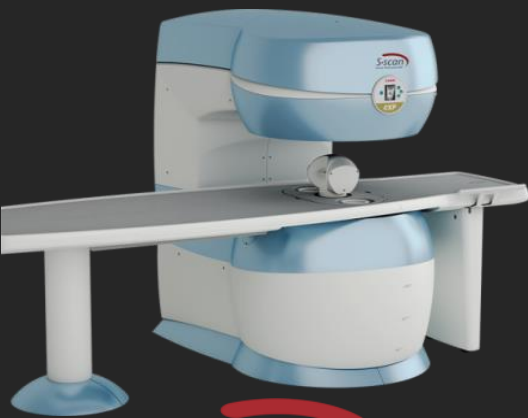Weight Bearing





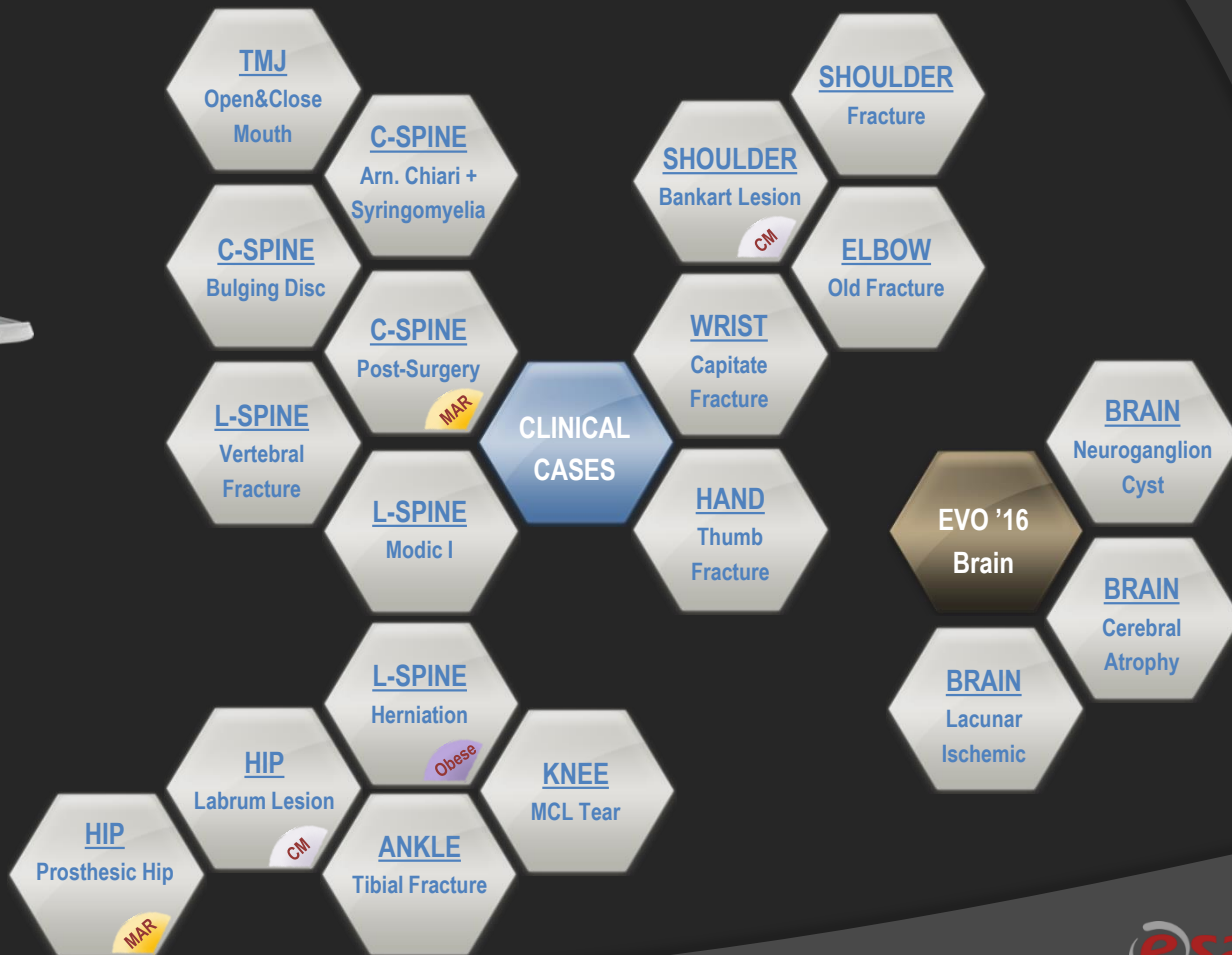Take Pride in Performance






S-scan
eXP
Technology

**Top Performance
In Action**





scan brio

eXP
Technology

The Key to
Confidence

