

# CLINICAL CASES


July 2016



O-scan  
eXP  
Technology



S-scan  
eXP  
Technology



G-scan brio  
eXP  
Technology



KNEE  
Meniscal Tear

ELBOW  
Arthritis/Inflammation

KNEE  
ACL Tear Avulsion

ELBOW  
Biceps Tendon  
Rupture

CLINICAL  
CASES

WRIST  
TFCC Lesion

KNEE  
Subchondral OA

WRIST  
Loose Body

CM

KNEE  
Monolateral  
Prosthesis

ANKLE  
ATFL Tear

HAND  
Ganglion Cyst

MAR

ANKLE  
Osteochondritis

FOOT  
Morton's Neuroma

KNEE  
Bilateral Prosthesis

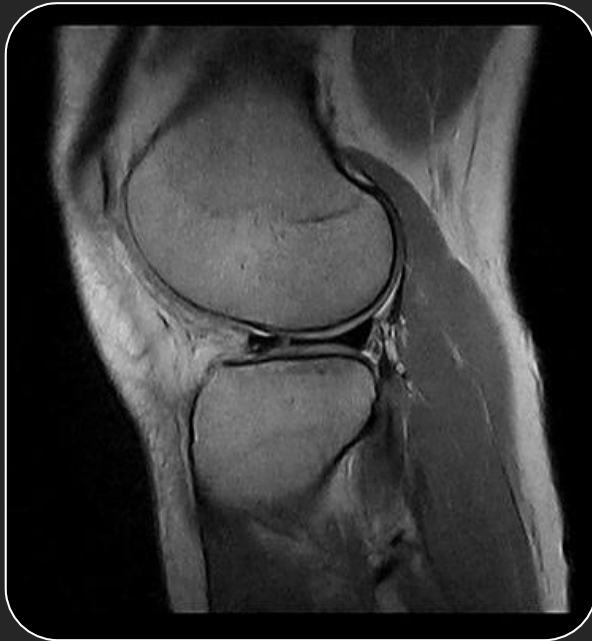MAR



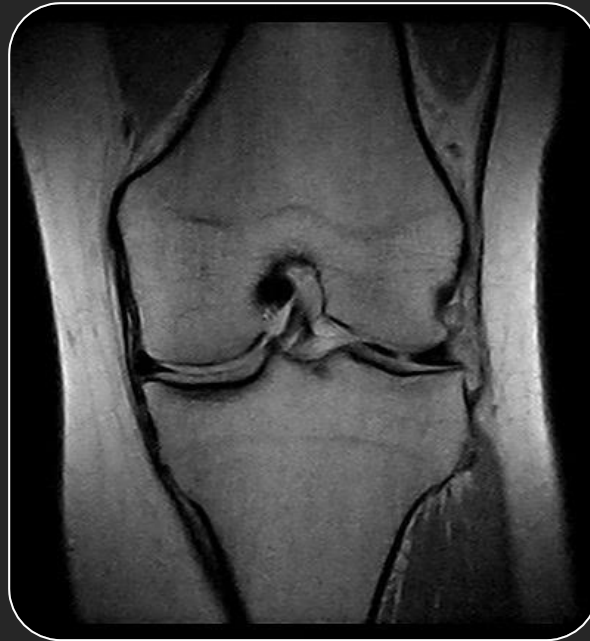Take Pride in  
Performance



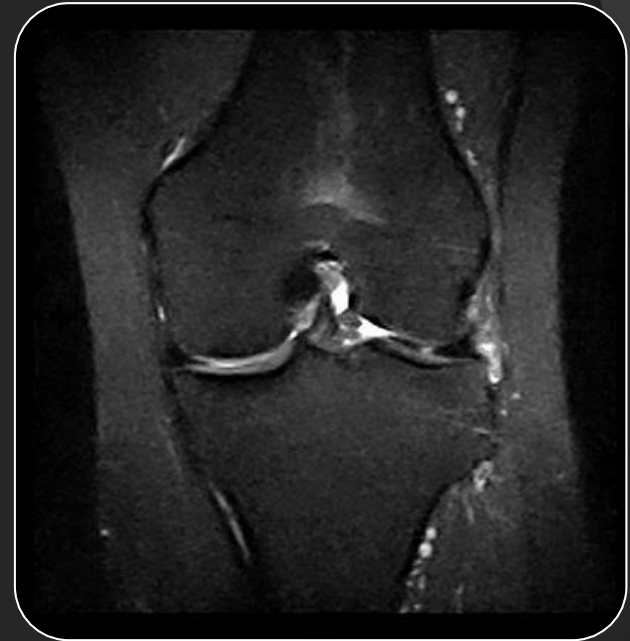# Knee: Meniscal Tear



FSE PD - Sagittal

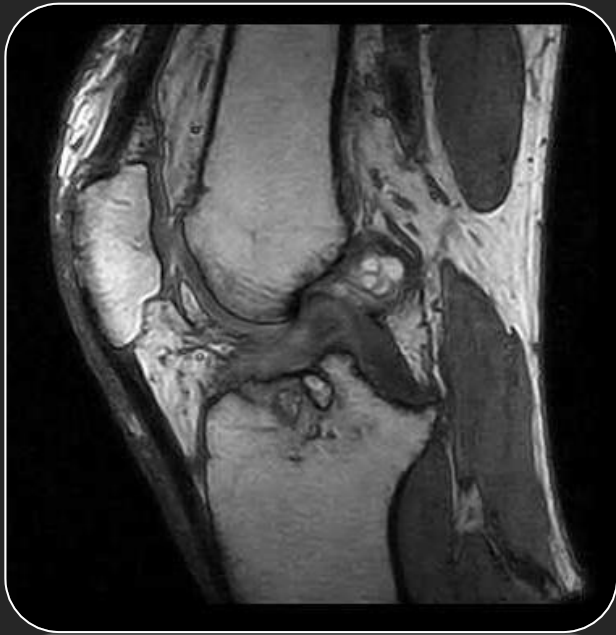

FSE PD - Coronal

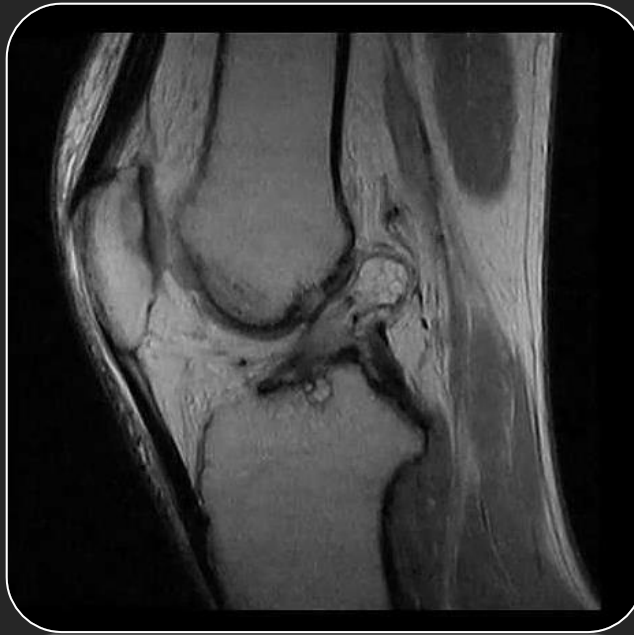

FSTIR - Coronal

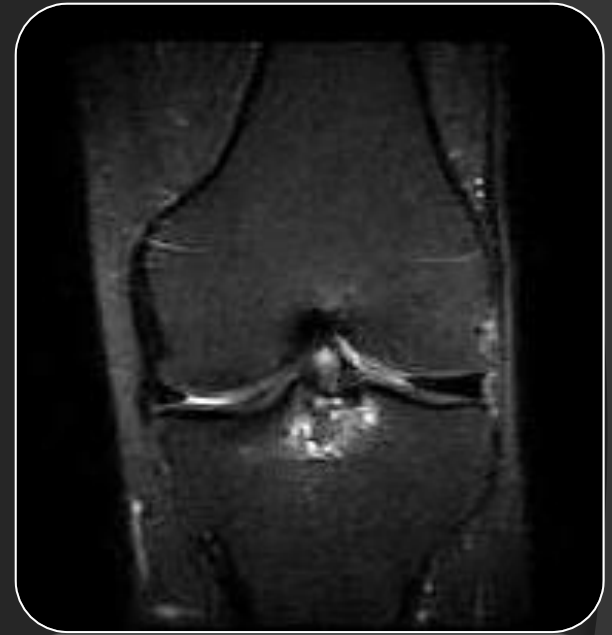# Knee: ACL Tibial Avulsion



3D SHARC ISO - Sagittal

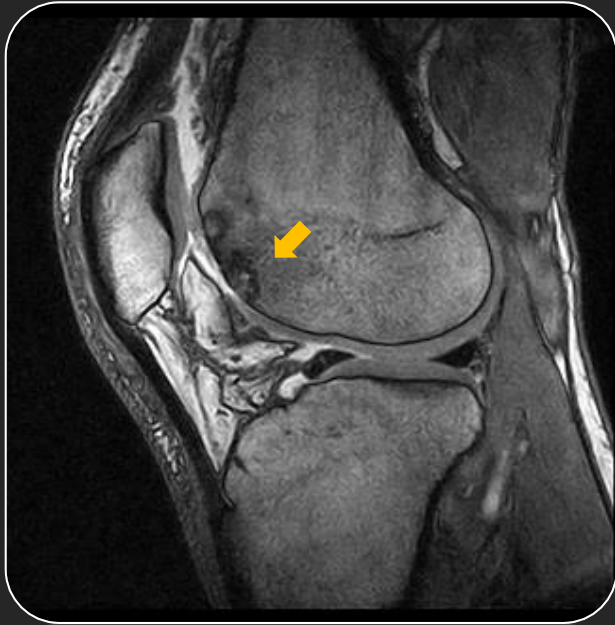


FSE PD - Sagittal

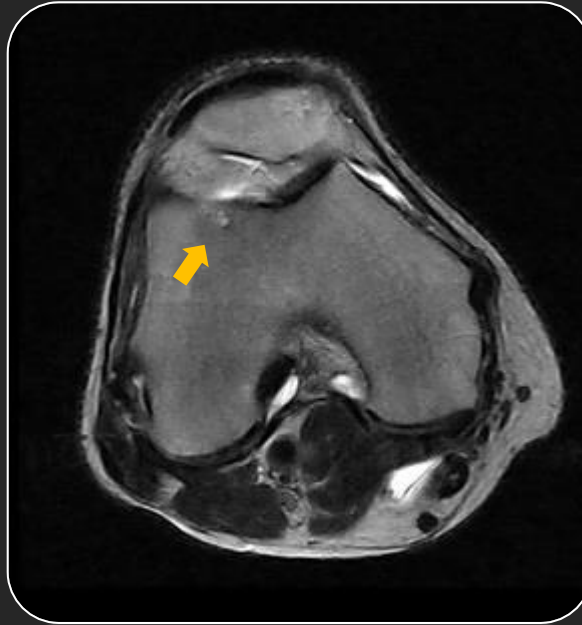

FSTIR - Coronal

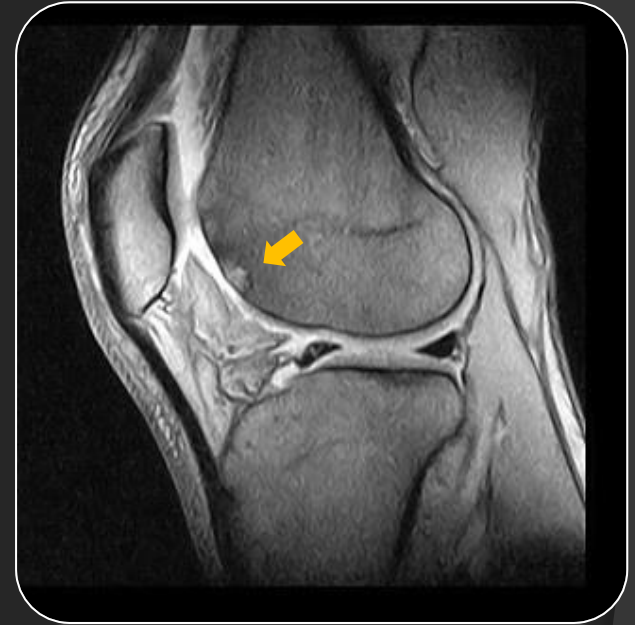# Knee: Subchondral OA



3D SHARC ISO - Sagittal

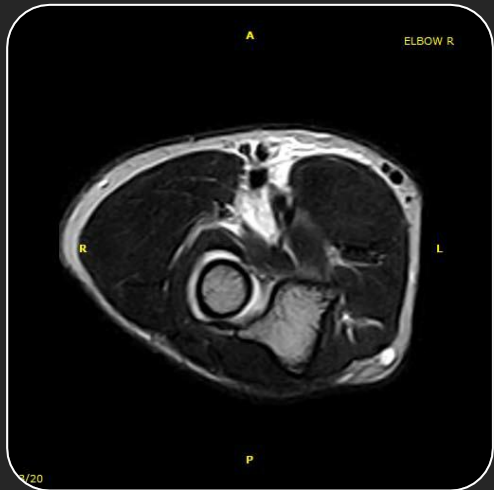

FSE T2 - Axial

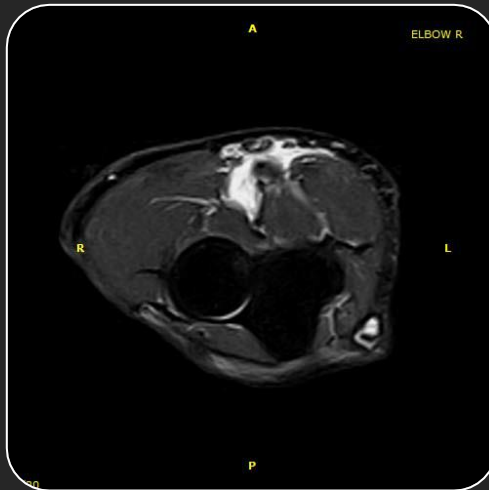


GE T2 - Sagittal

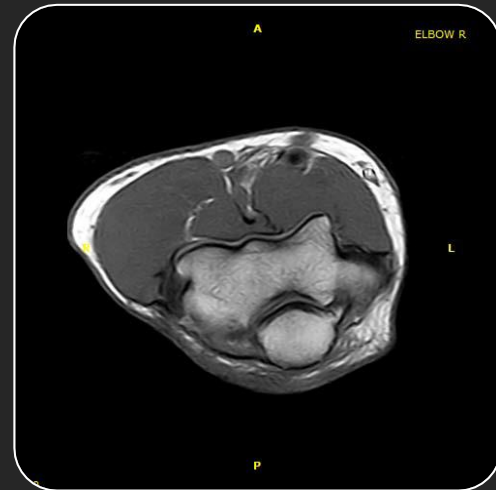
# Elbow: Biceps Tendon Rupture



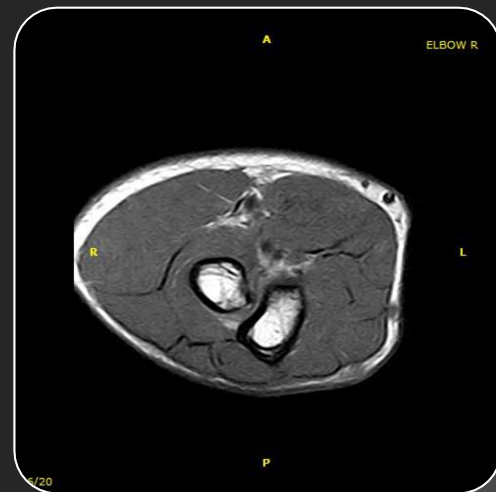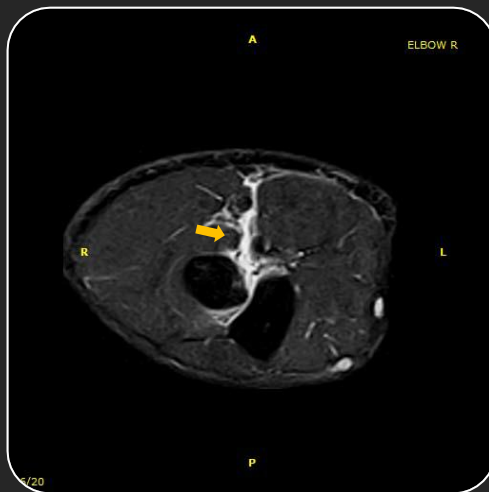
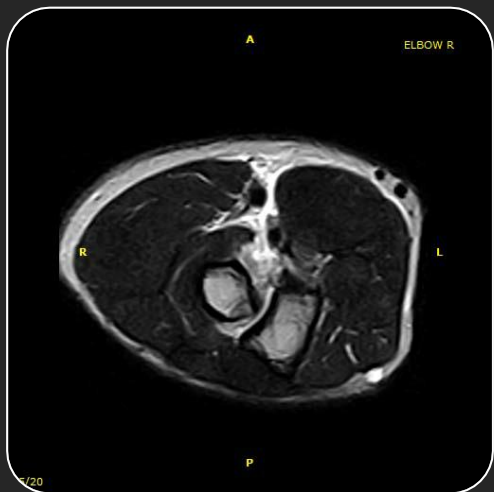
FSE T2 - Axial



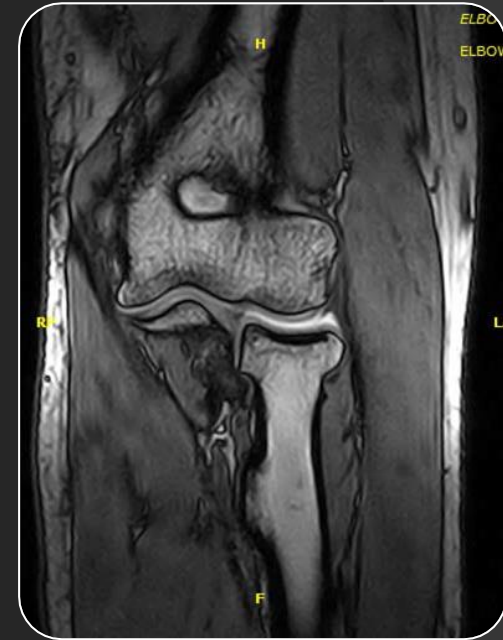
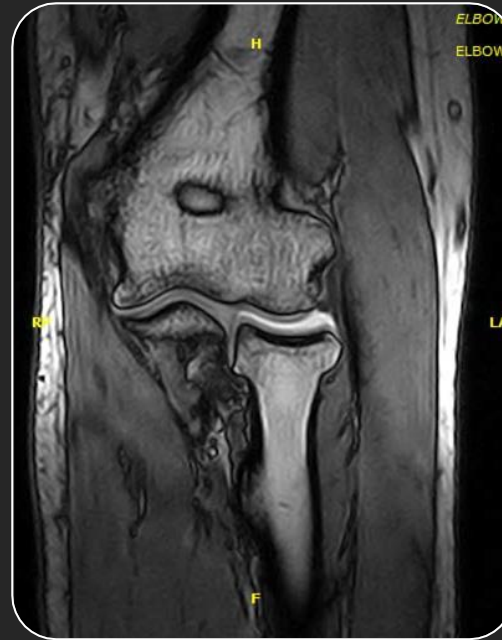
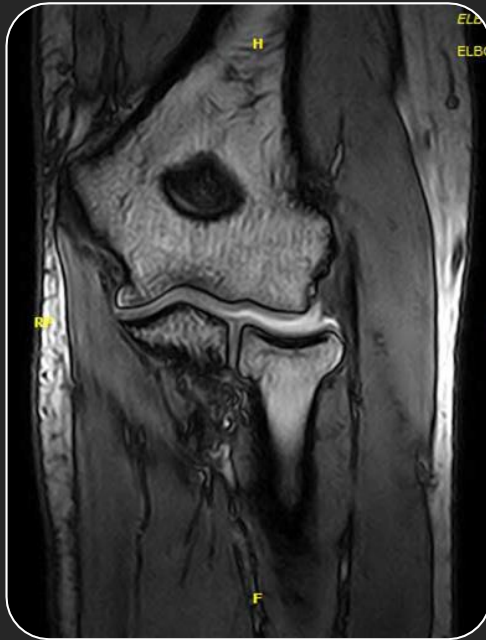
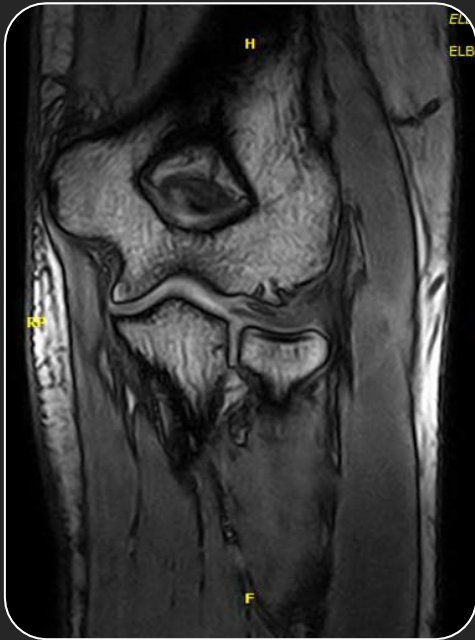GE STIR- Axial



SE T1 - Axial

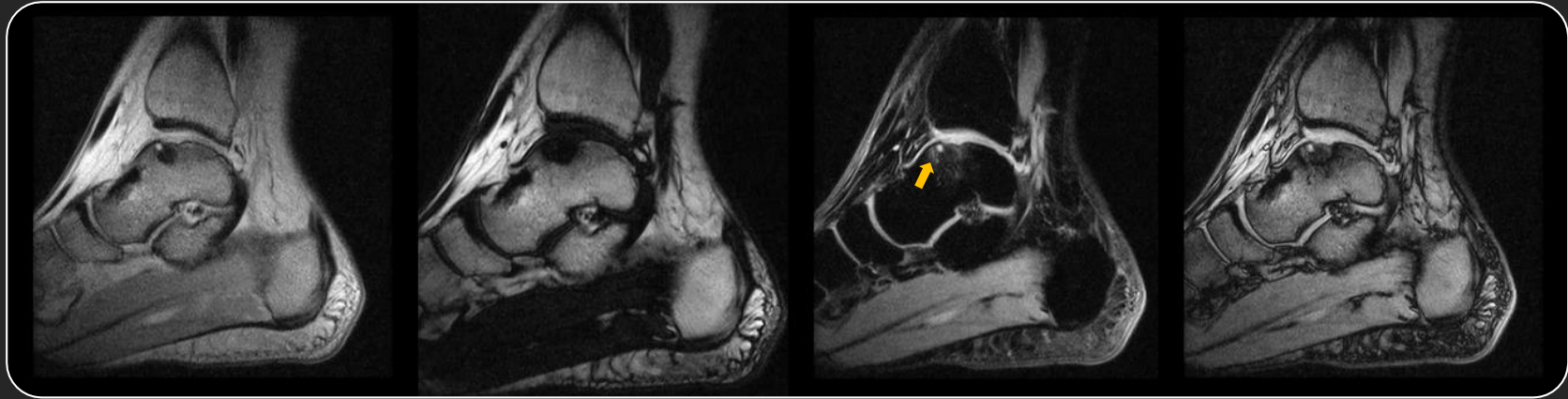

# Elbow: Arthritis & Inflammation

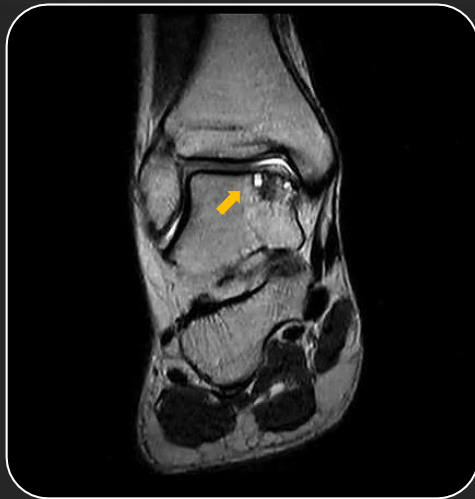

3D SHARC ISO - Coronal

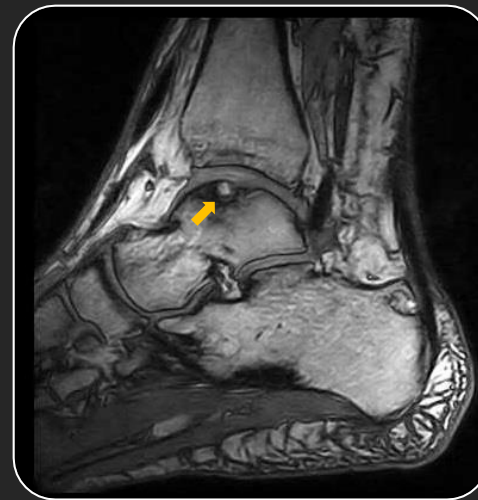# Ankle: Osteochondritis Dissecans



X-Bone T2 (4 echoes) - Sagittal



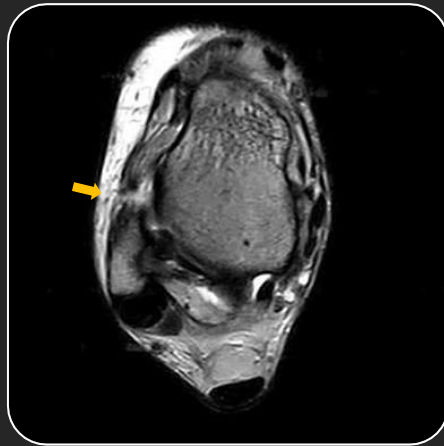
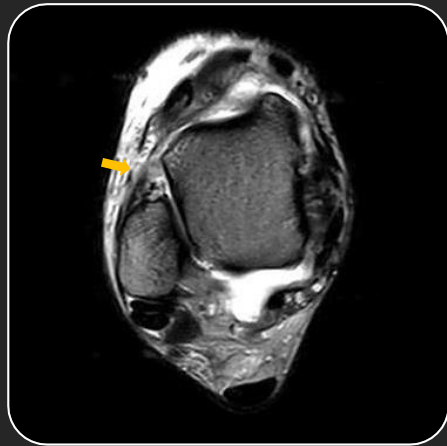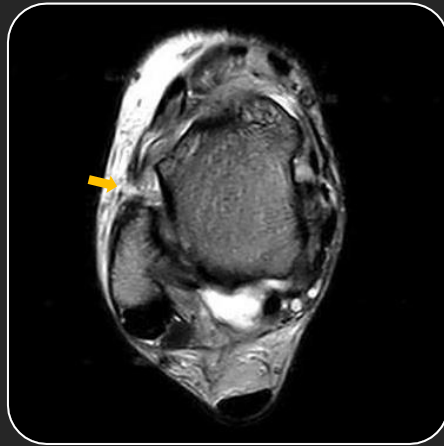
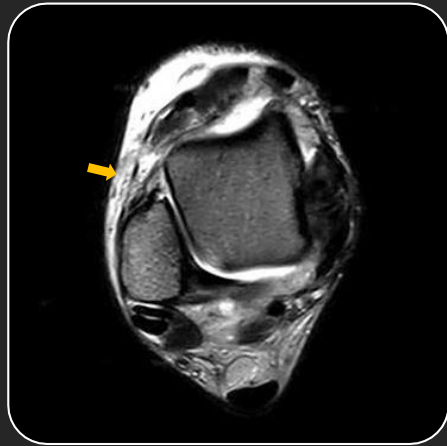FSE T2 - Coronal



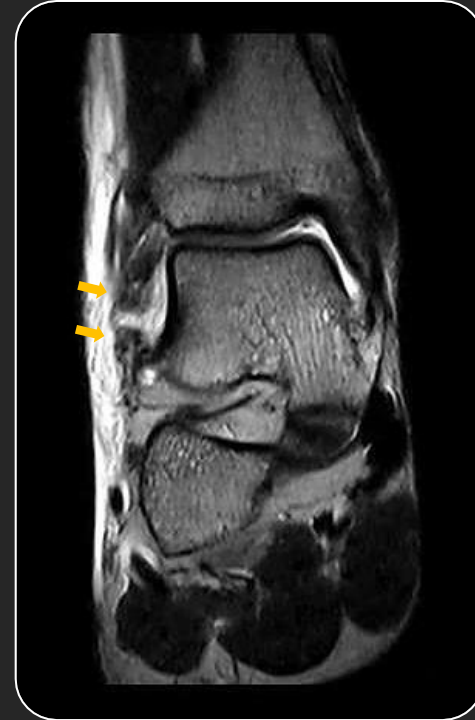3D SHARC ISO - Sagittal



# Ankle: ATFL Tear

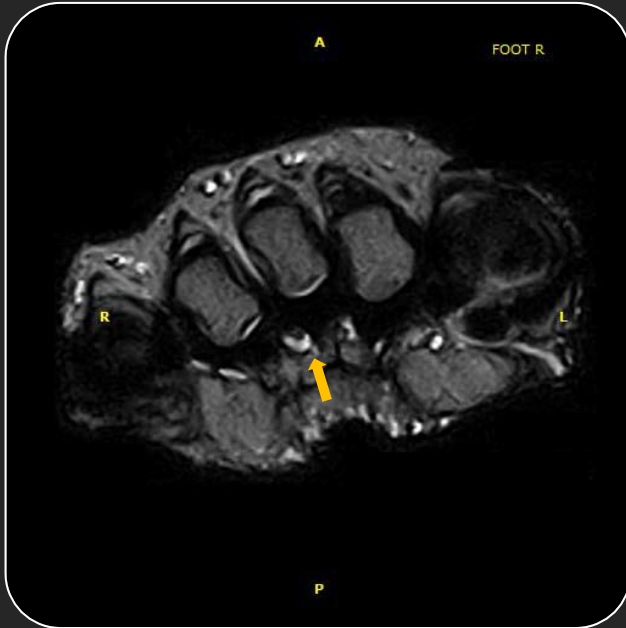


FSE T2 - Axial

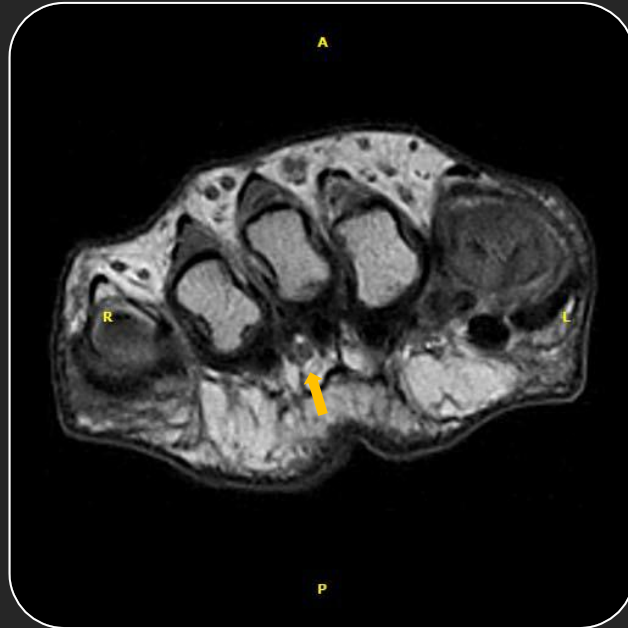


FSE T2 - Coronal

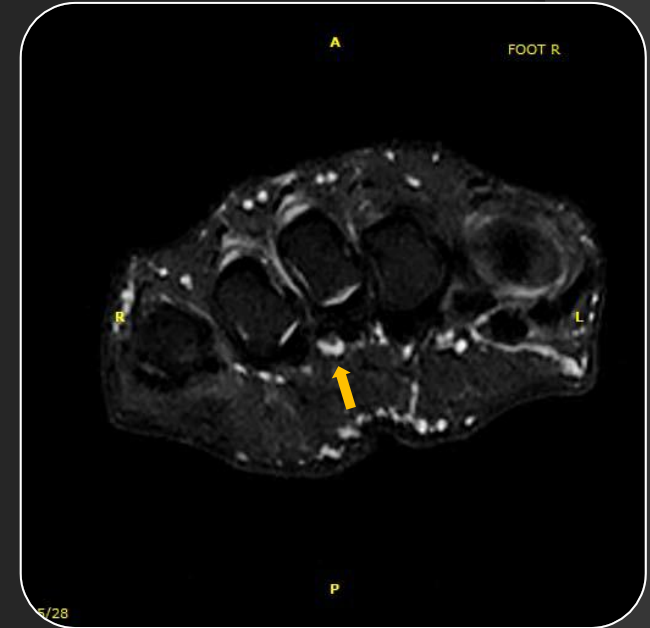
# Foot: Morton's Neuroma



FSE T2 - Axial

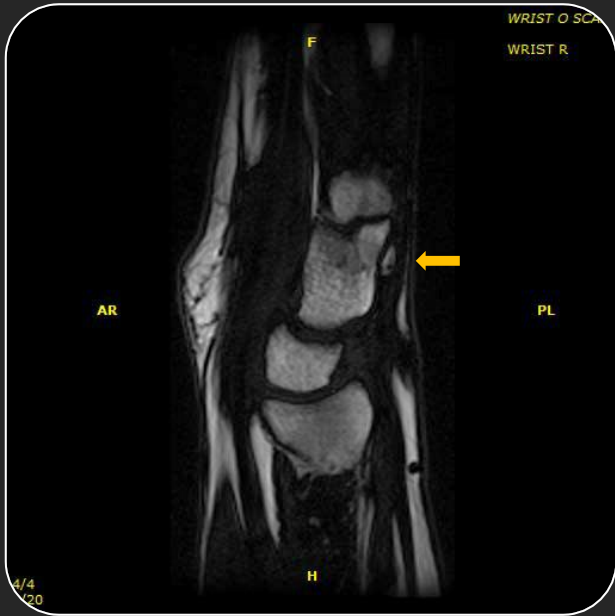


SE T1 - Axial

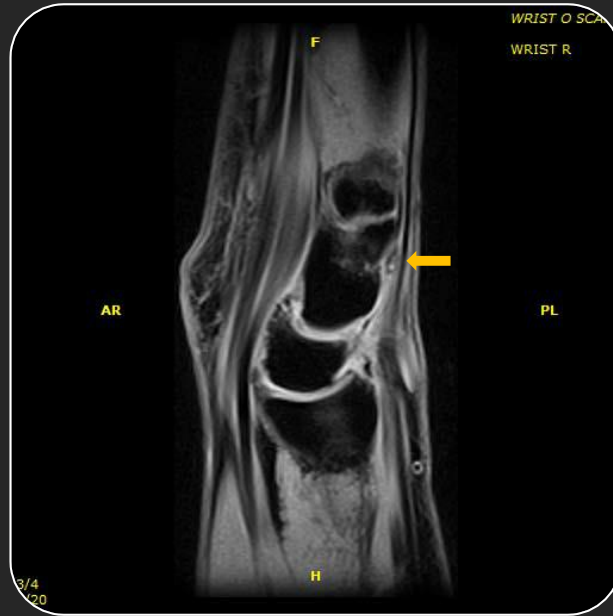


FSTIR - Axial

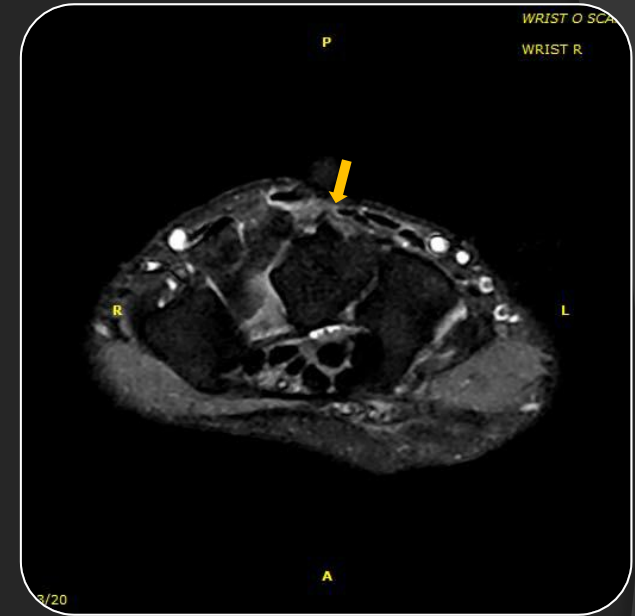
# Wrist: Loose Body



FSE T2 - Sagittal

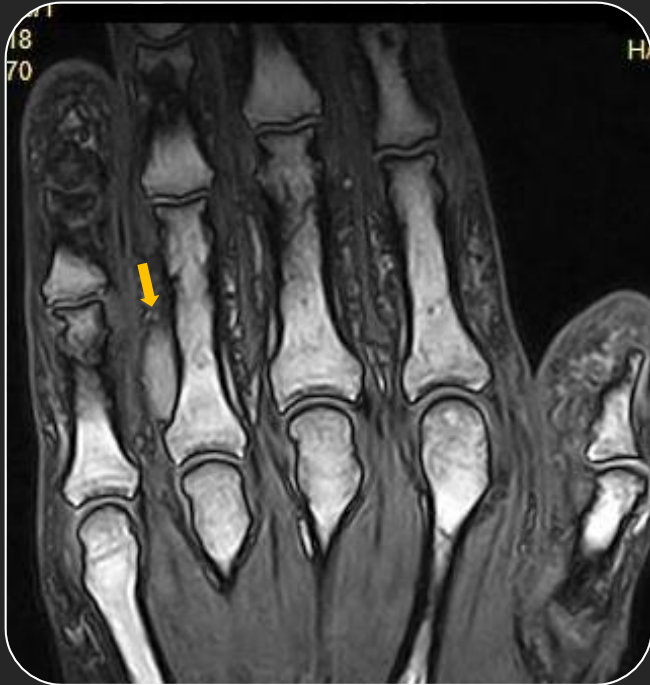


X-Bone T2 (Fat Suppression Echo) - Axial

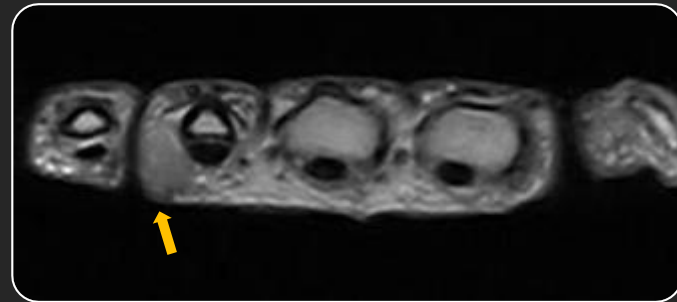
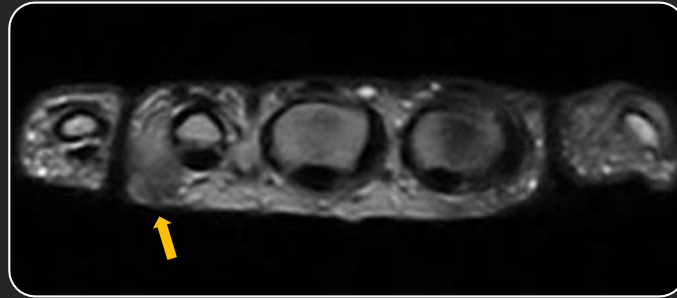


FSTIR - Axial

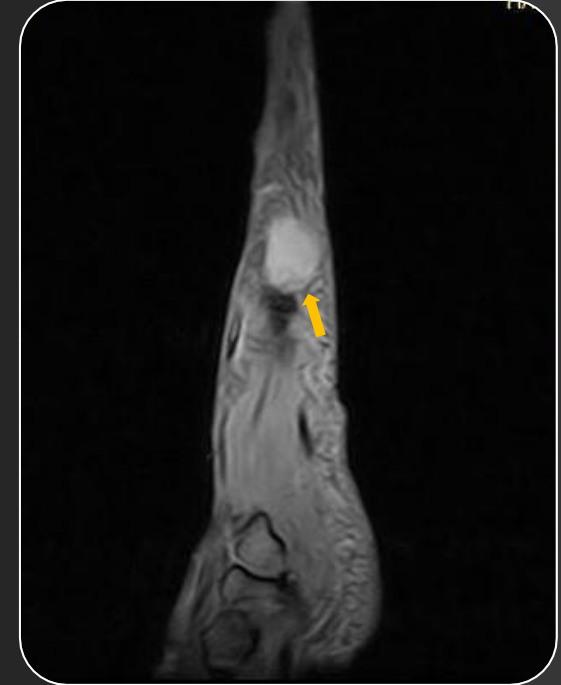
# Hand: Ganglion Cyst



3D SHARC ISO - Coronal

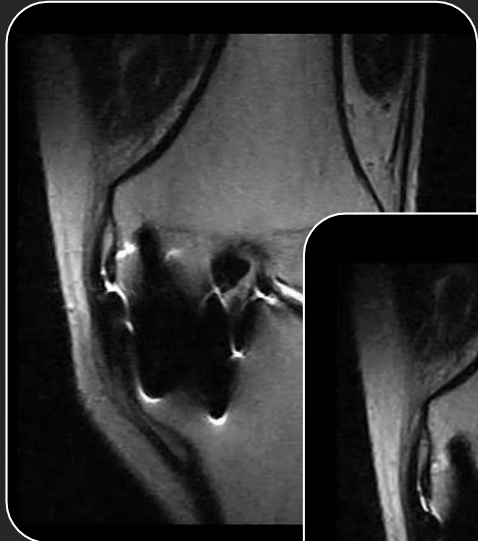


FSE PD-T2 - Axial

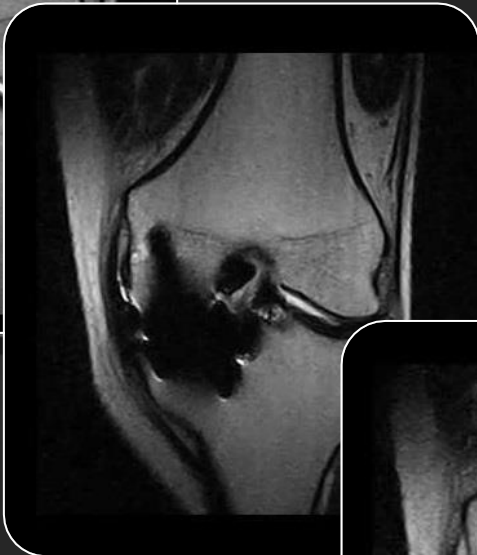


GE T2 - Sagittal

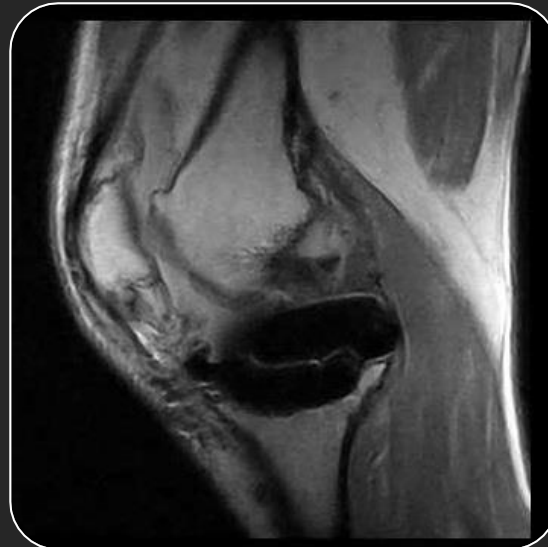# Knee: Monolateral Prosthesis w/ MAR



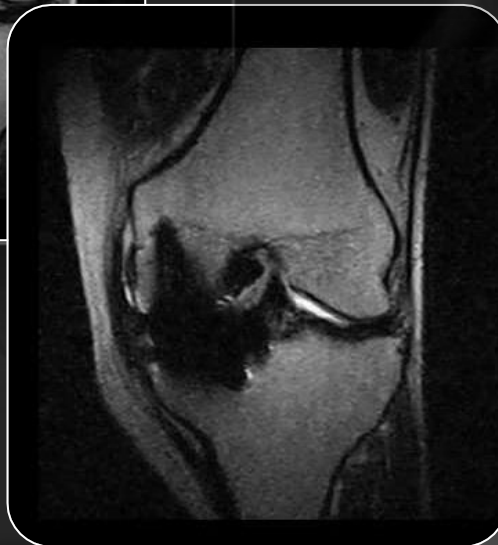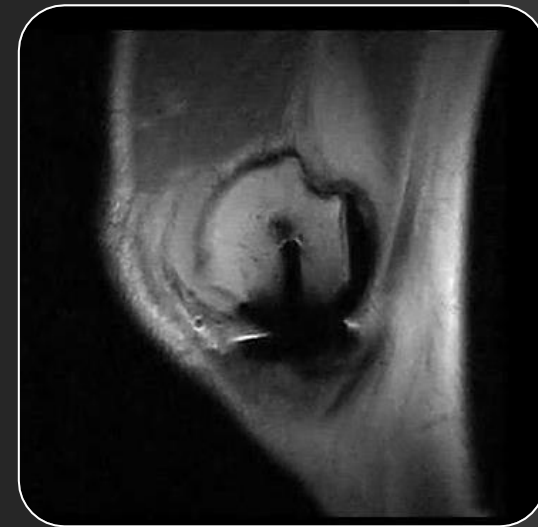FSE T2  
Coronal



FSE T2  
Coronal (MAR)

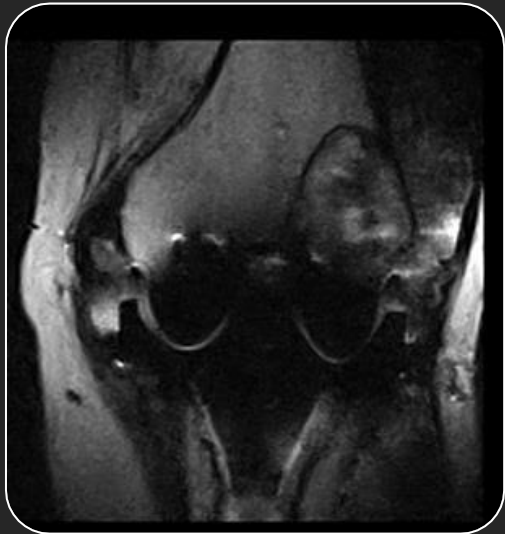

FSE PD  
Sagittal (X-MAR)

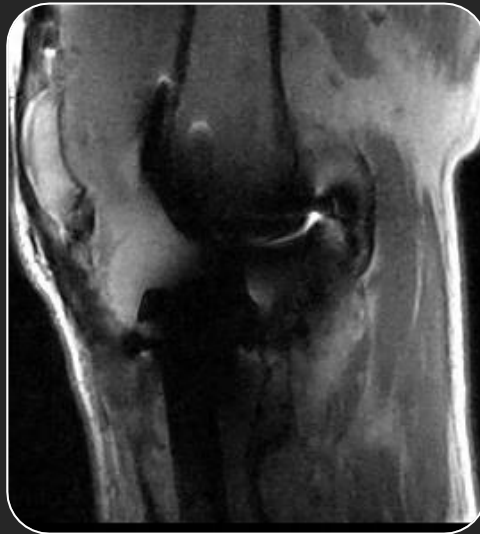

FSE T2  
Coronal (X-MAR)

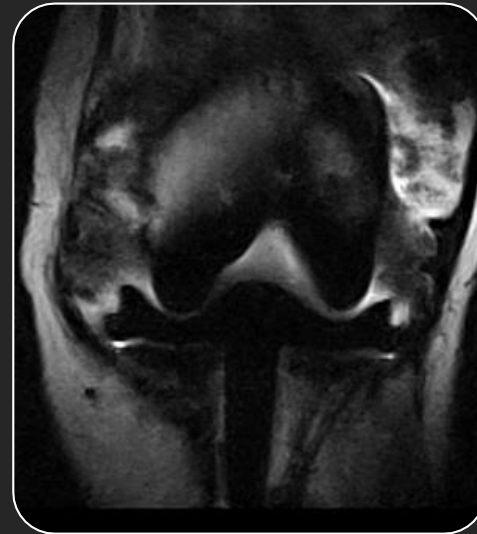# Knee: Total Knee Replacement



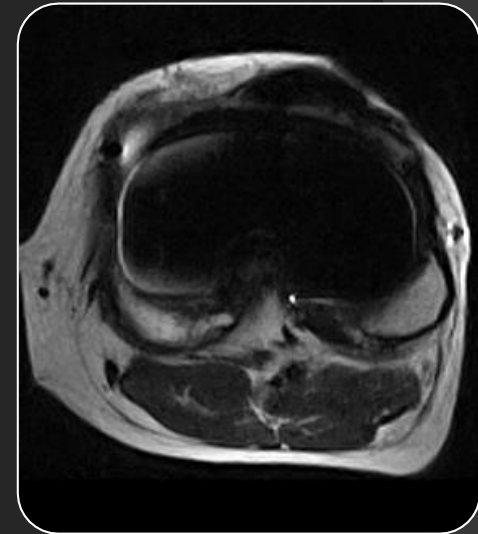
FSE T2 w/ MAR - Coronal



FSE PD w/ MAR - Sagittal

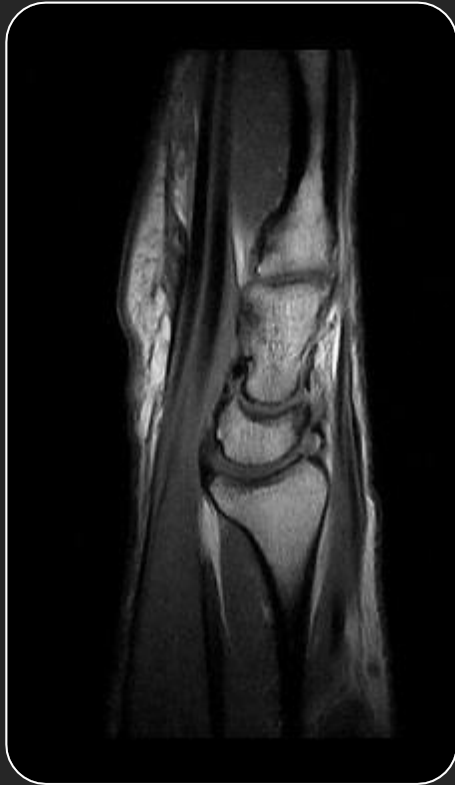

FSE T2 w/ MAR - Coronal

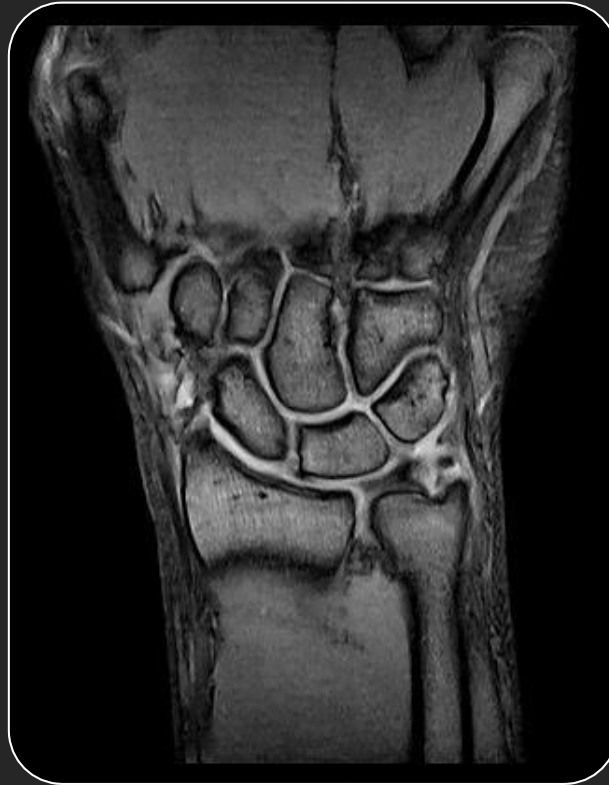

FSE T2 w/ MAR - Axial

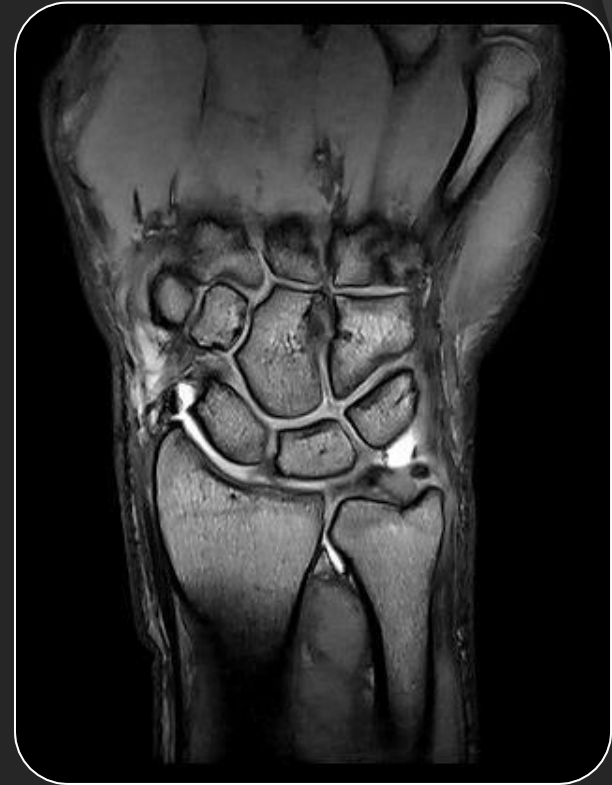# Wrist: TFCC Lesion w/ CM



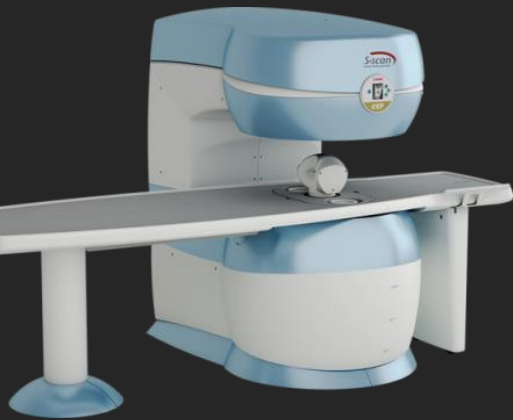
SE T1 - Sagittal



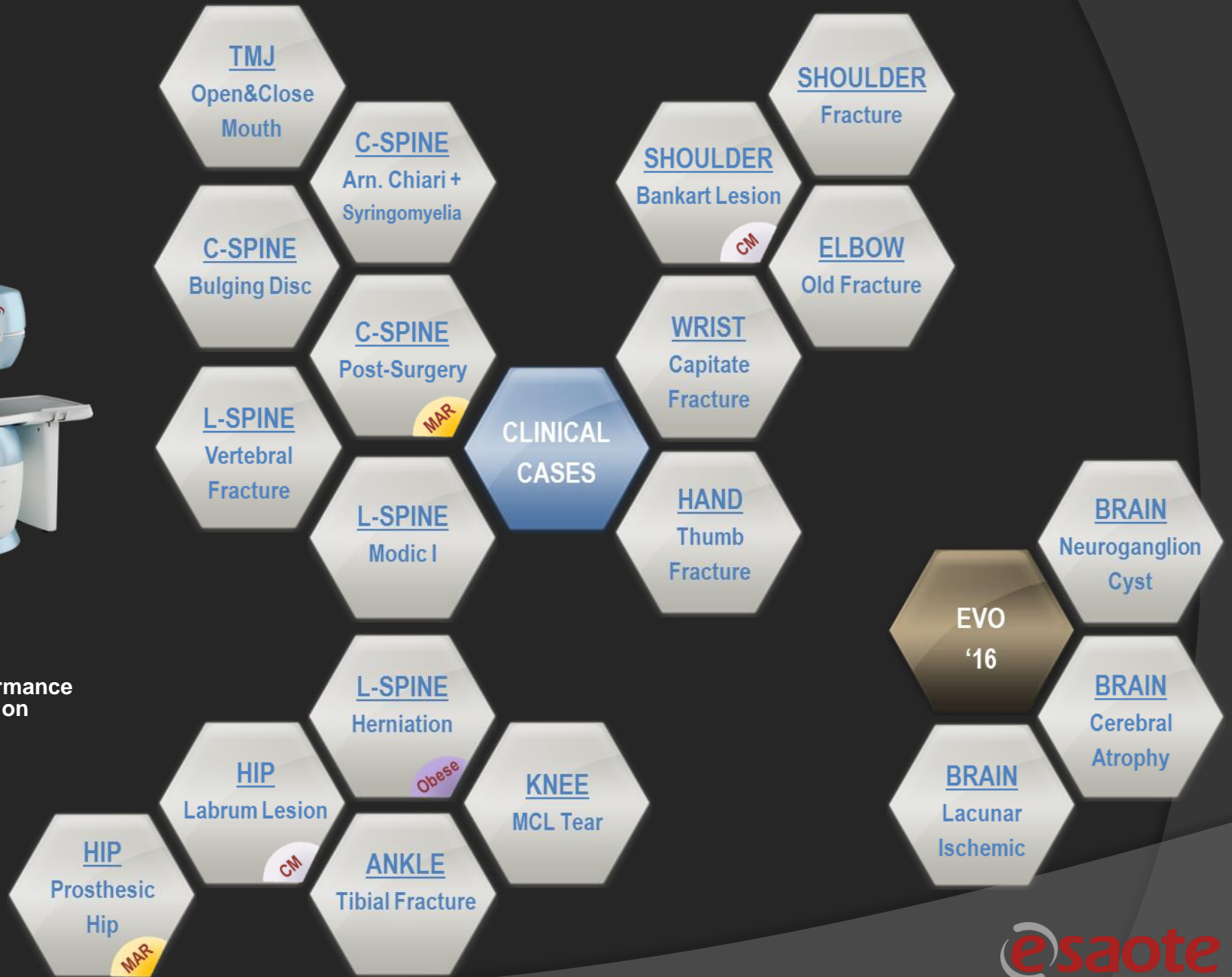GE T1 (pre-contrast) - Coronal



GE T1 (post-contrast) - Coronal

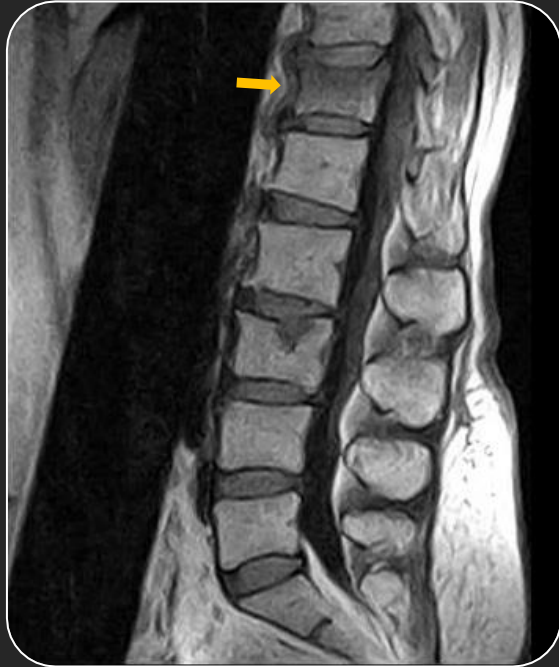


Top Performance  
In Action

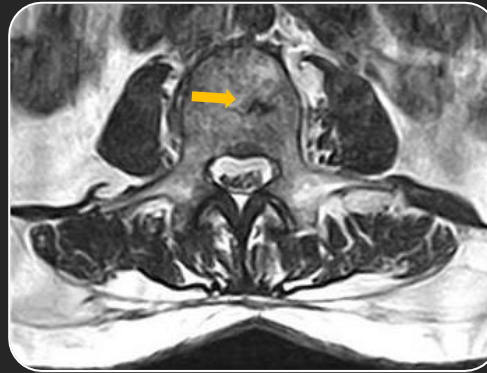
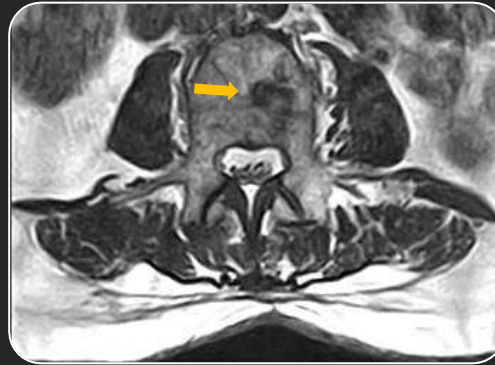




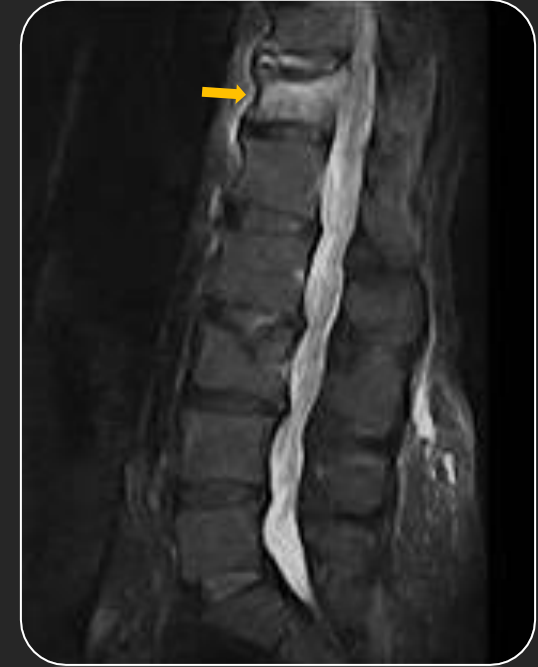# L-Spine: Vertebral Fracture



SE T1 - Sagittal

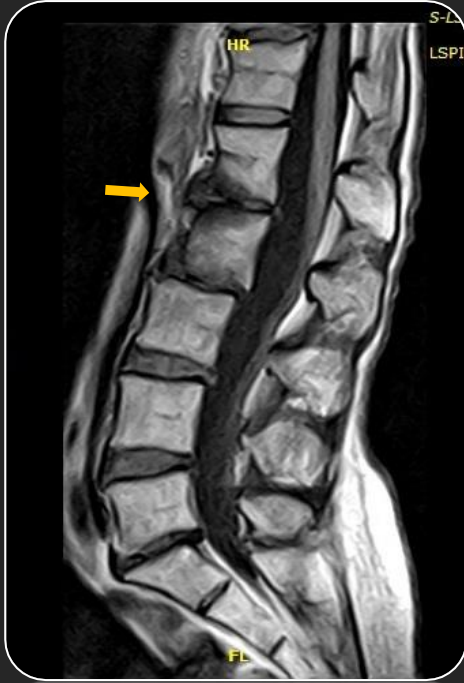

3D HYCE ISO - Axial

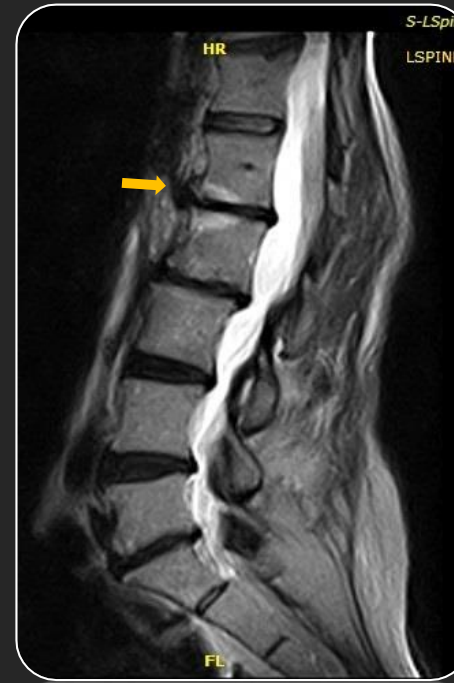
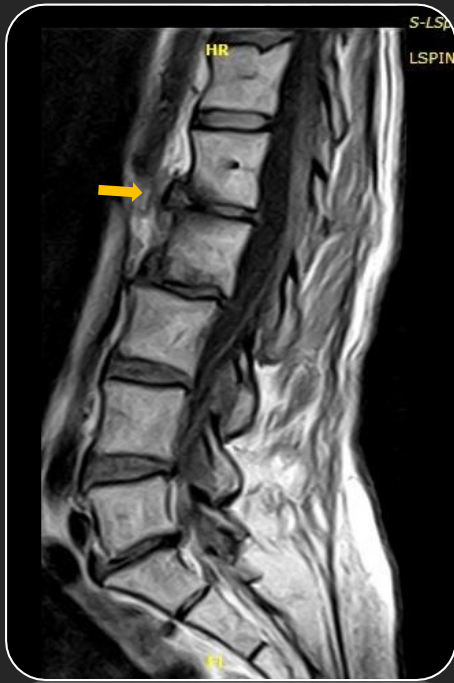
FSTIR - Sagittal

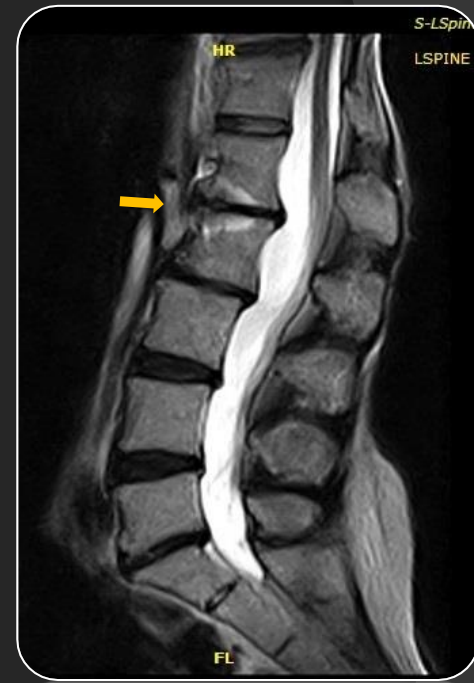# L-Spine: Disc Degeneration (Modic I)



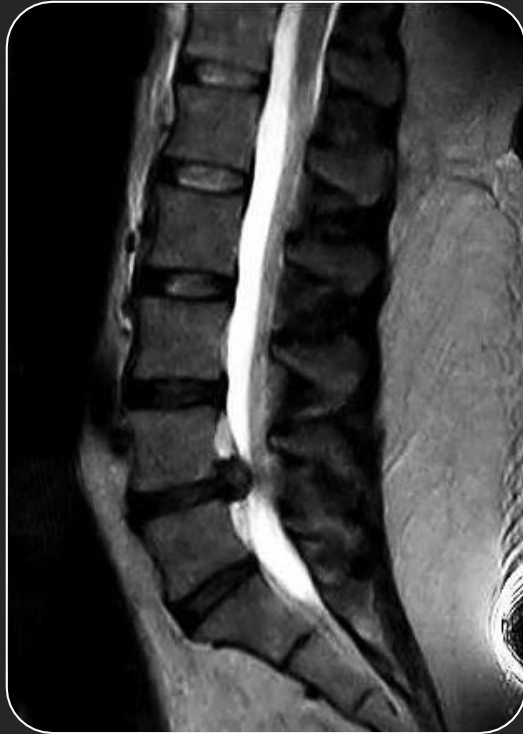SE T1 - Sagittal



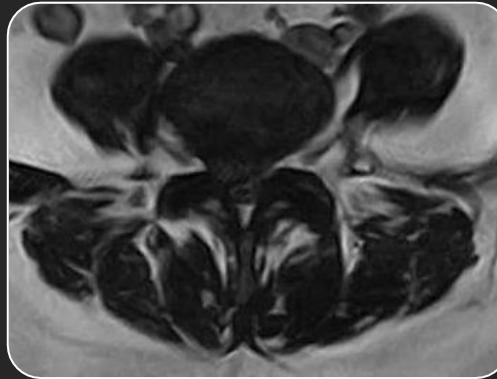
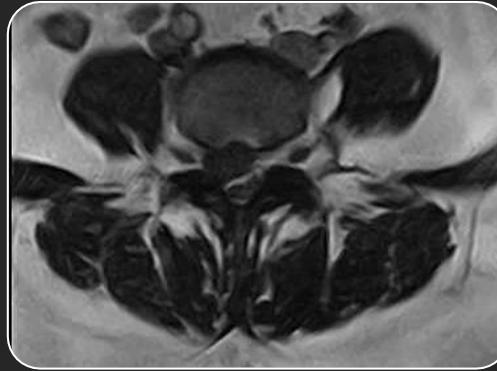
FSE T2 - Sagittal



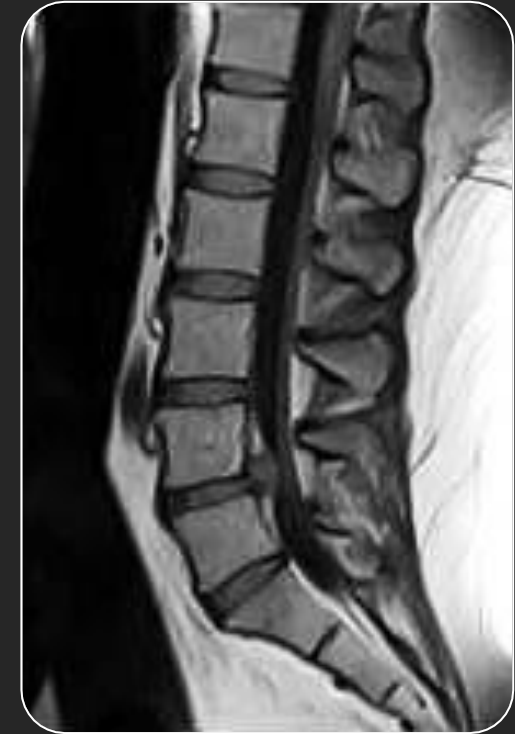# L-Spine: Disc Herniation (Obese Patient)



FSE T2 - Sagittal

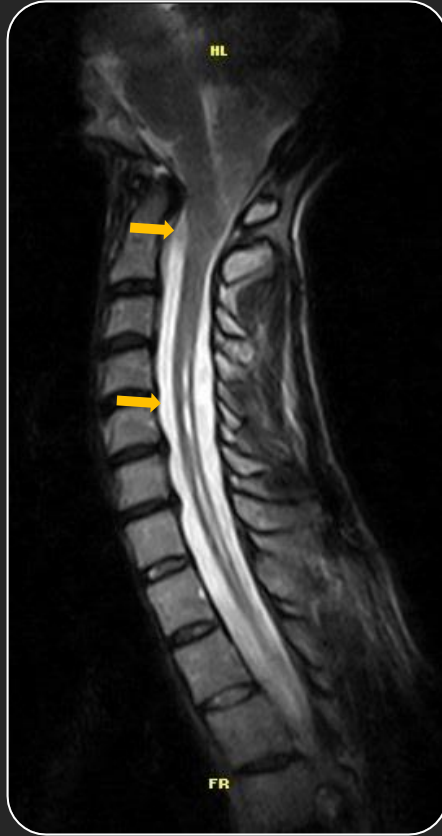


3D HYCE ISO - Axial

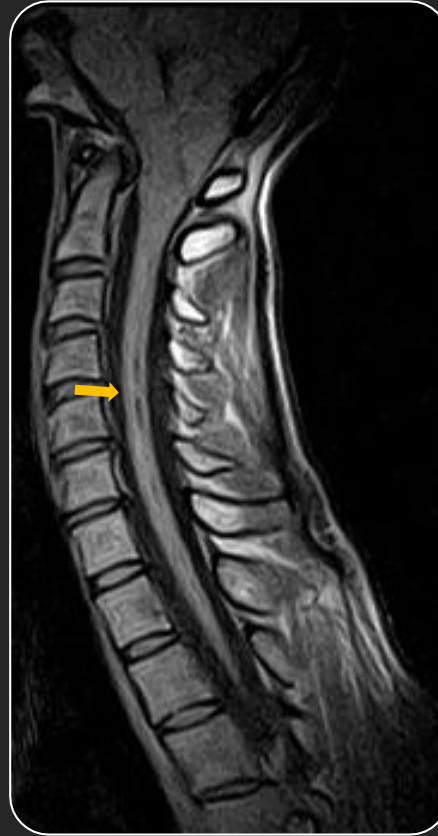

SE T1 - Sagittal

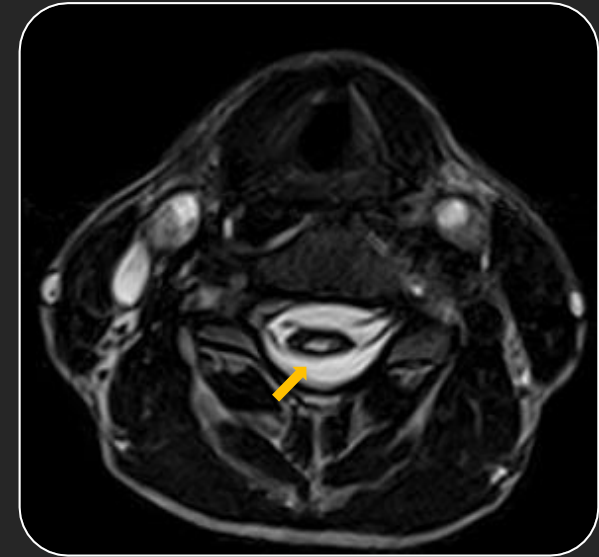
# C-Spine: Arnold Chiari + Syringomyelia



FSE T2 - Sagittal

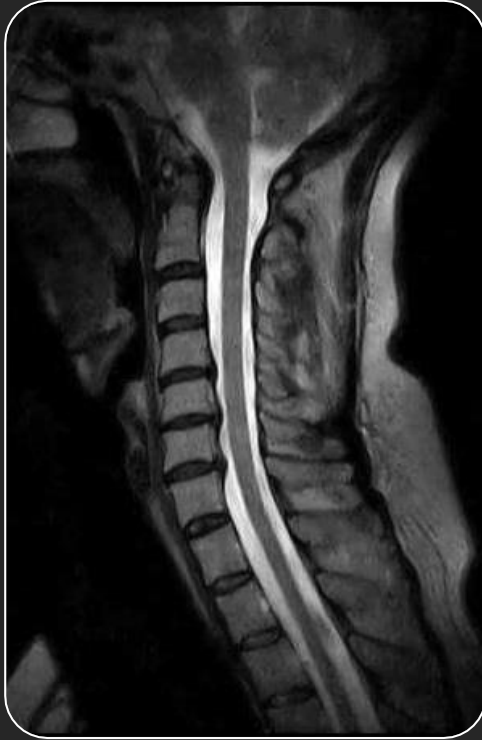

SE T1 - Sagittal

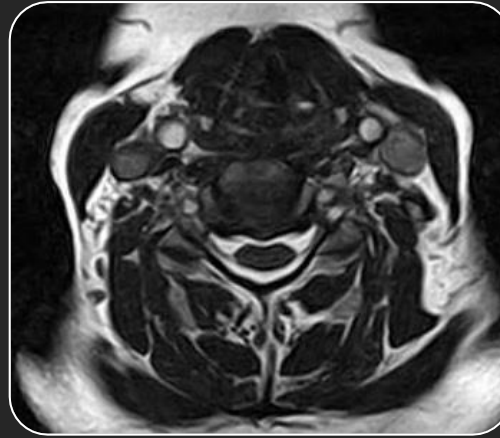

3D HYCE ISO - Axial

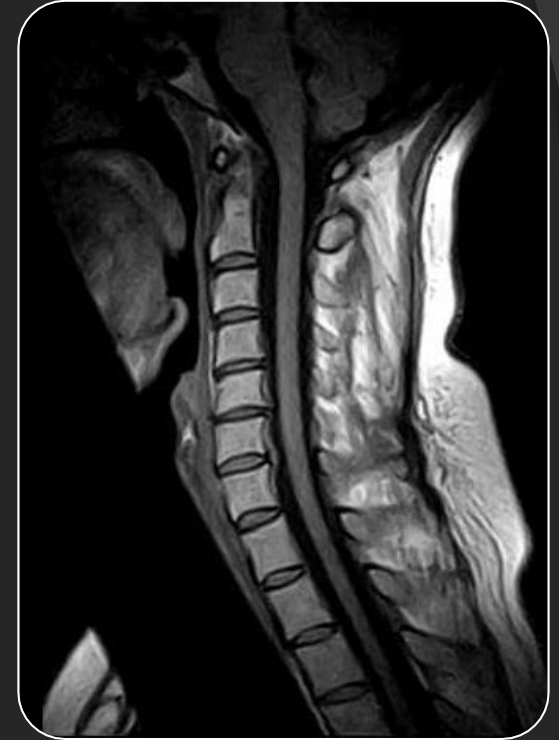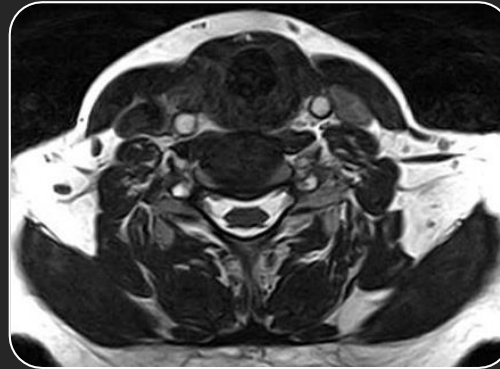
# C-Spine: Bulging Disc



FSE T2 - Sagittal

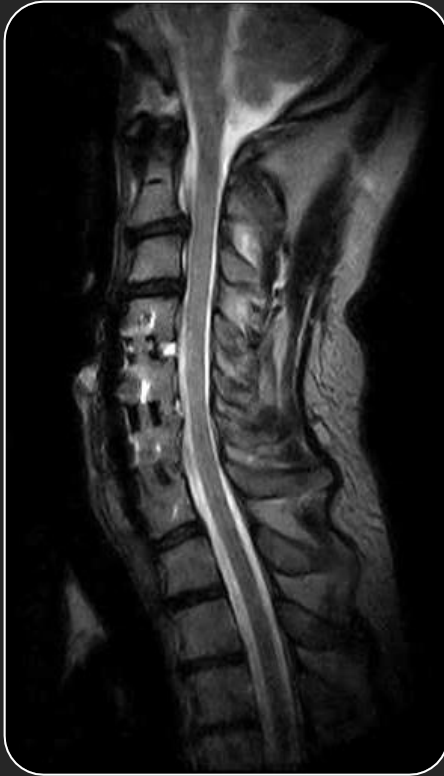

3D HYCE ISO - Axial

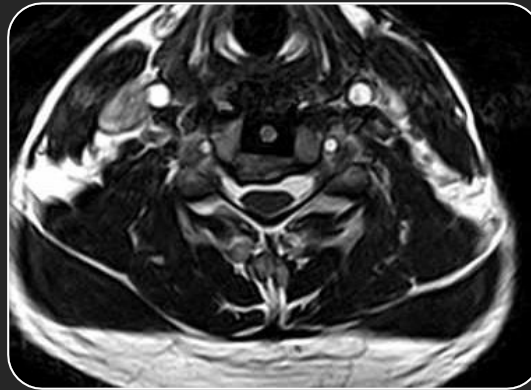
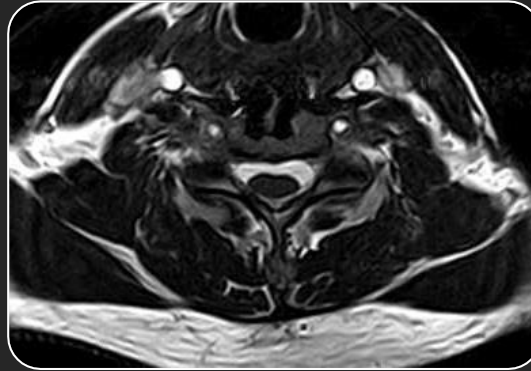


SE T1 - Sagittal

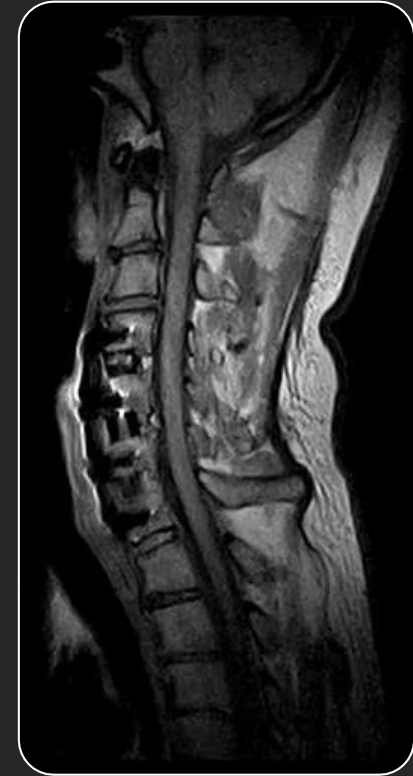# C-Spine: Postsurgical Fixation (MAR)



FSE T2 - Sagittal

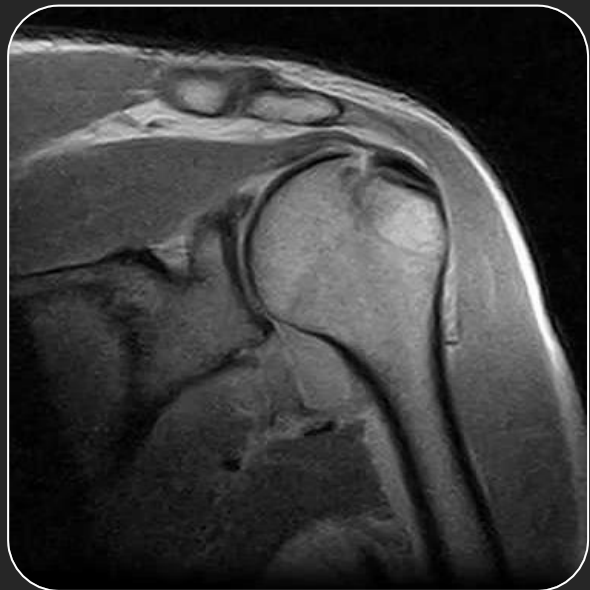

3D HYCE ISO - Axial

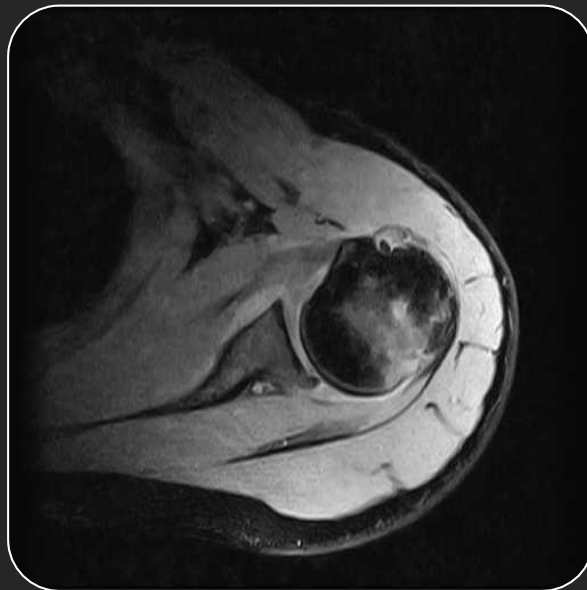


SE T1 - Sagittal

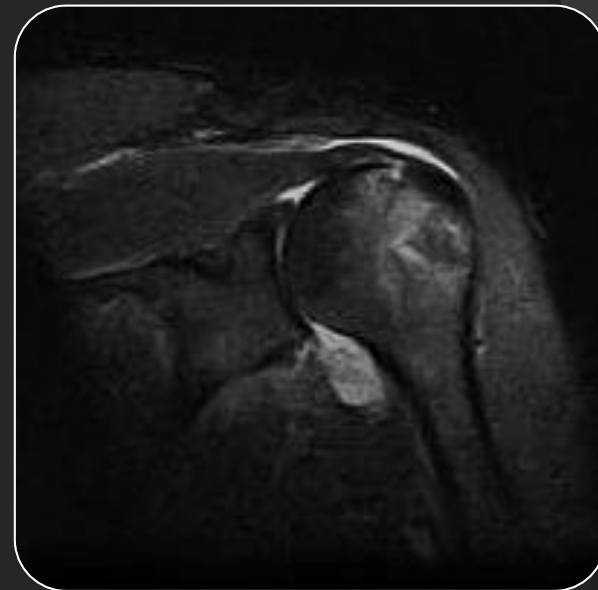
# Shoulder: Greater Trochanter Fracture



FSE PD - Coronal

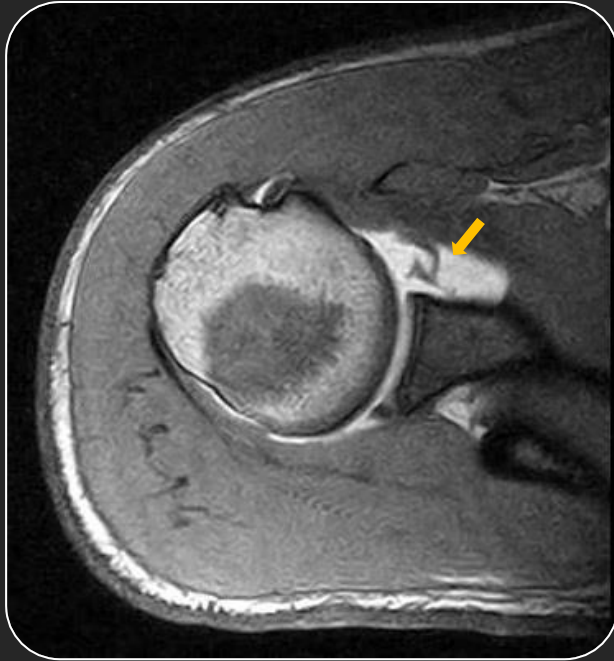

X-Bone T2 (Fat Suppression Echo) - Axial

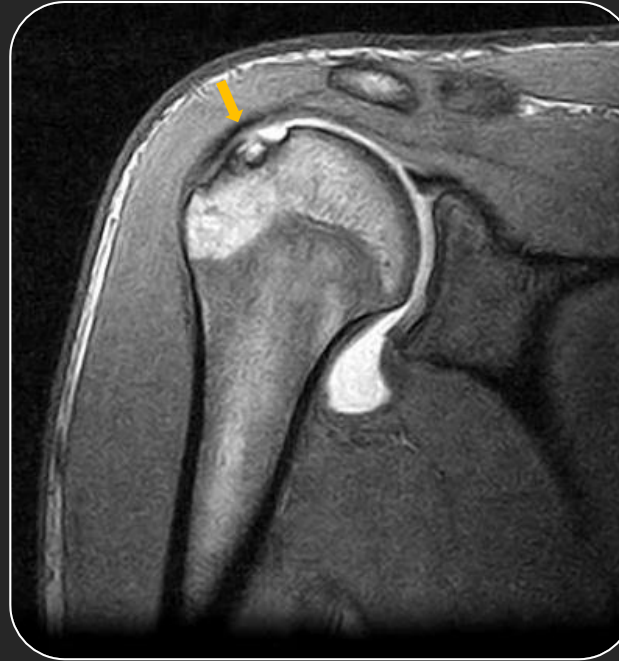


FSTIR - Coronal

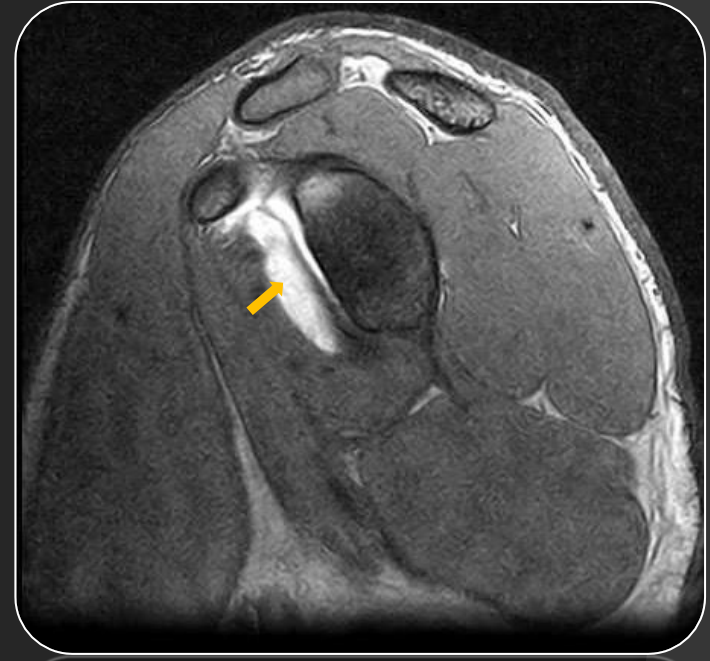# Shoulder: Bankart Lesion + Hill Sachs (CM)



3D SHARC (CM) - Axial



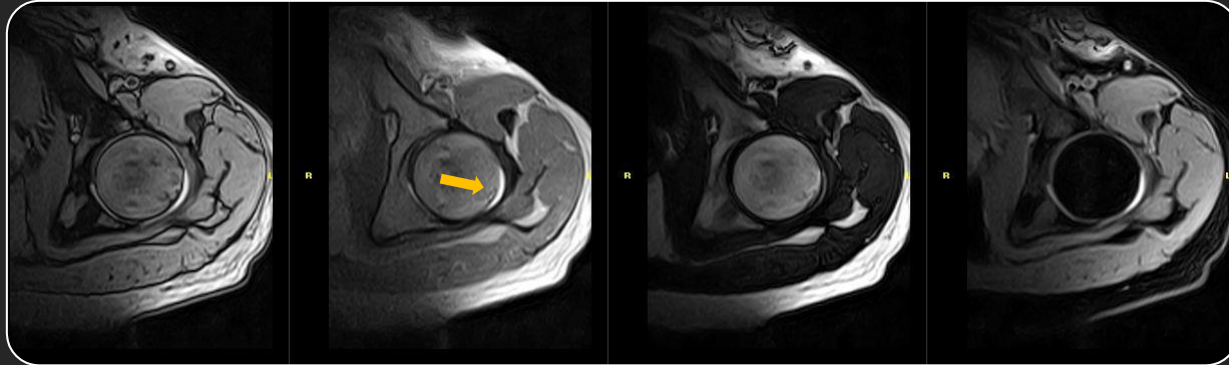
3D SHARC (CM) - Coronal



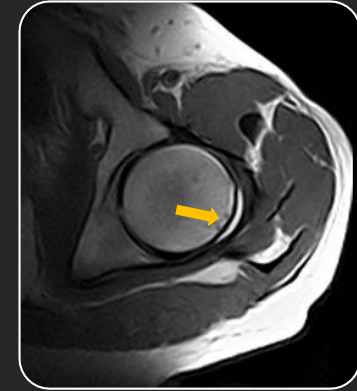3D SHARC (CM) - Sagittal



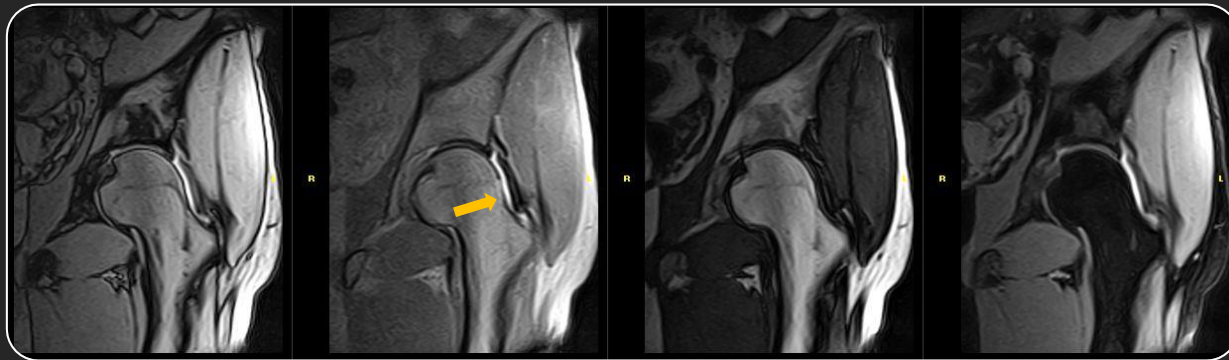
# Hip: Labrum Lesion (CM)



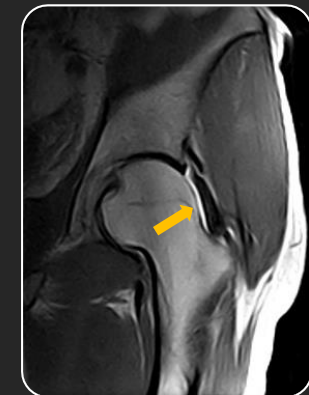
X-Bone T2 - Axial



SE T1 (CM) - Axial

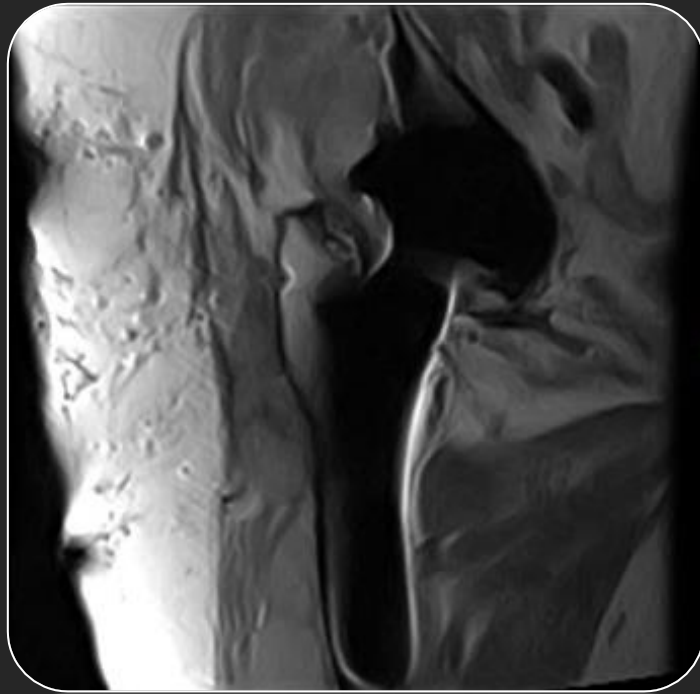


X-Bone T2 - Coronal

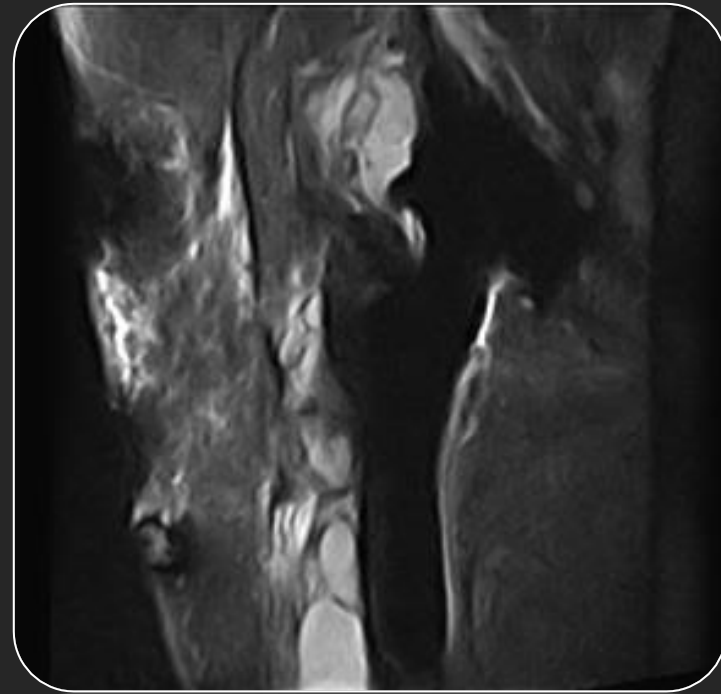


SE T1 (CM) - Coronal

# Hip: Replacement Prosthesis w/ MAR

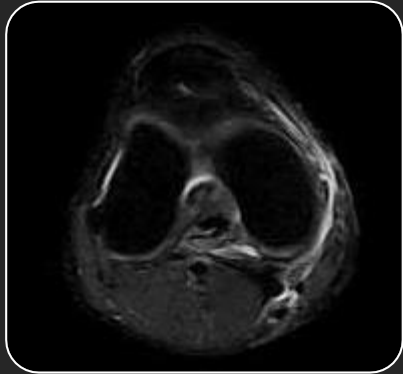


SE T1 (MAR) - Coronal

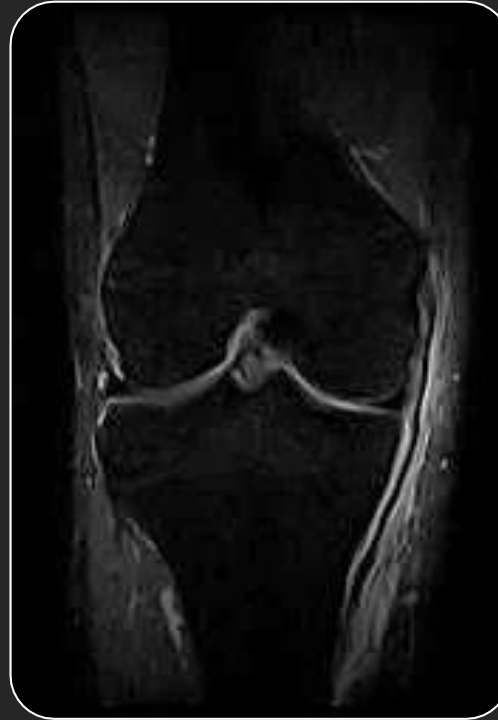

FSTIR (MAR) - Coronal

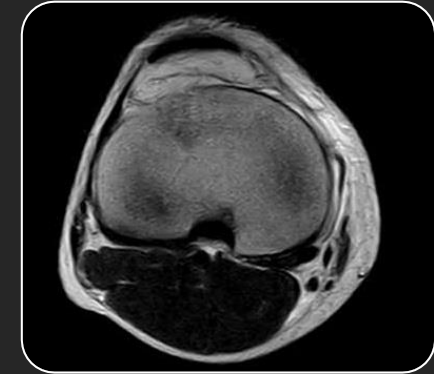# Knee: MCL Tear + Pes Anserinus



FSTIR - Axial

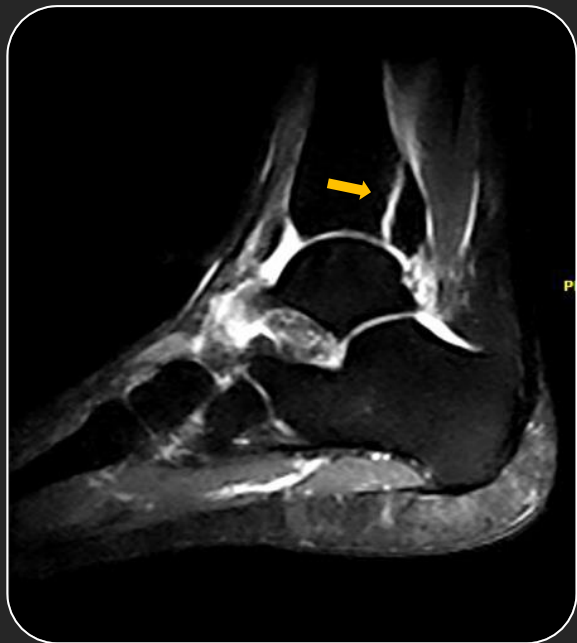

FSTIR - Coronal

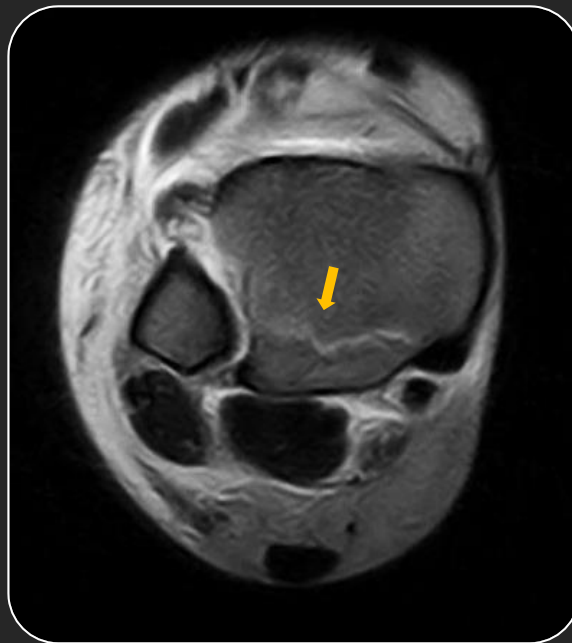


FSE T2 - Axial

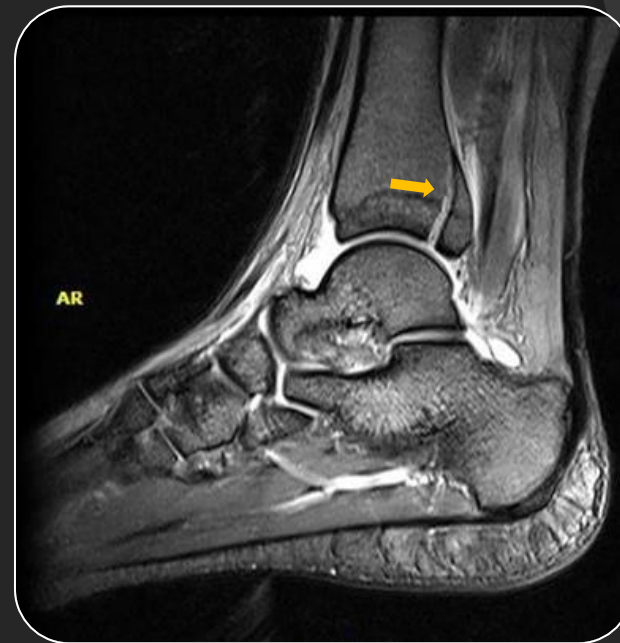# Ankle: Tibial Fracture



GE STIR - Sagittal

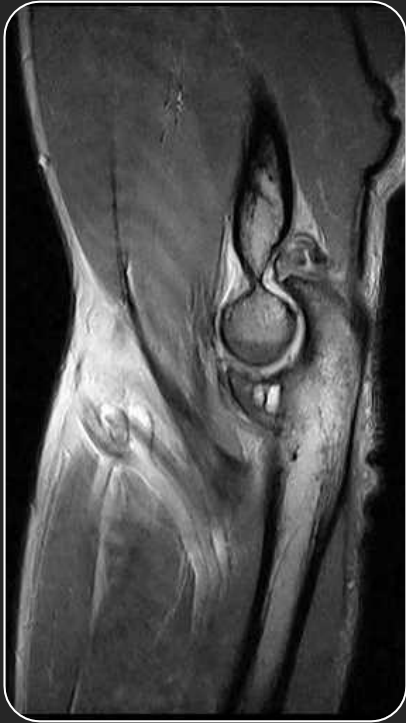

FSE T2 - Axial

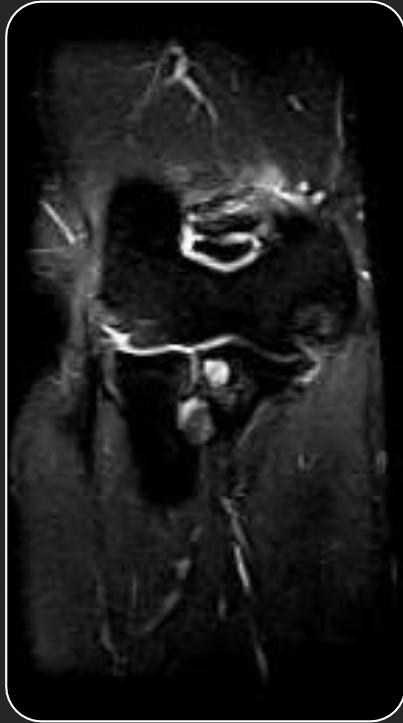


GE T2 - Sagittal

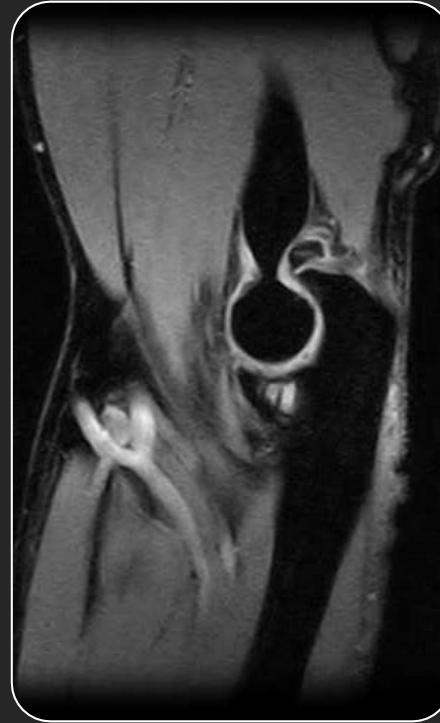
# Elbow: Old Fracture



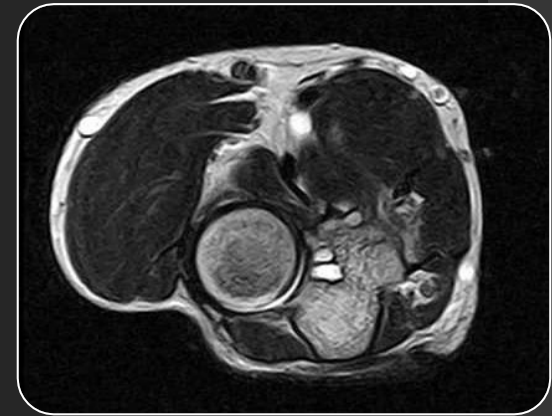GE T2 - Sagittal



FSTIR - Coronal

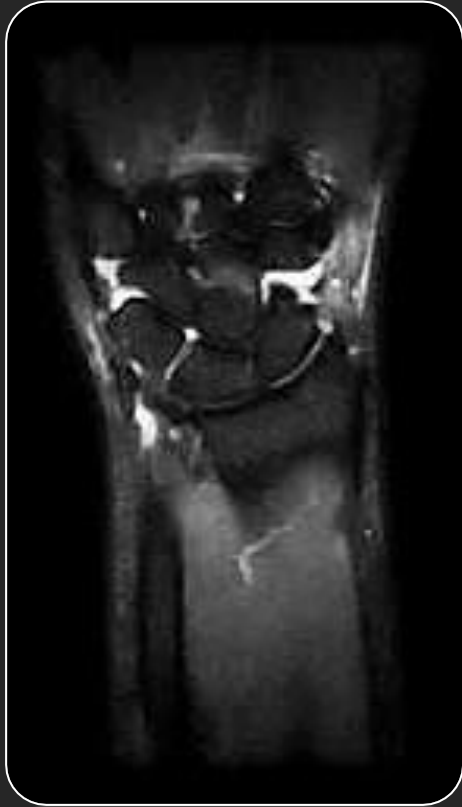

X-Bone T2 (Fat Suppression Echo)  
- Sagittal

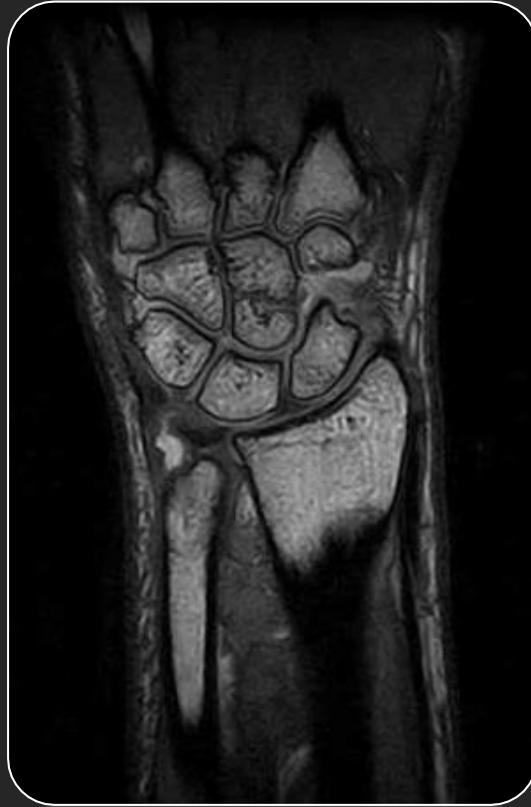

FSE T2 - Axial

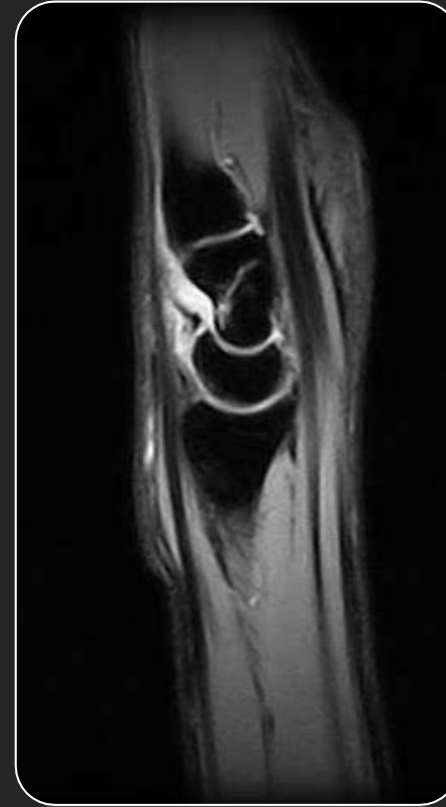
# Wrist: Capitate Fracture



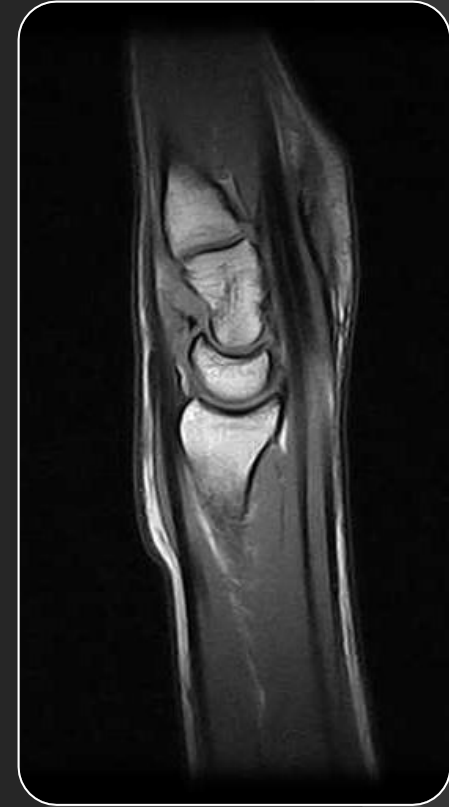GE STIR - Coronal



3D SHARC ISO - Coronal

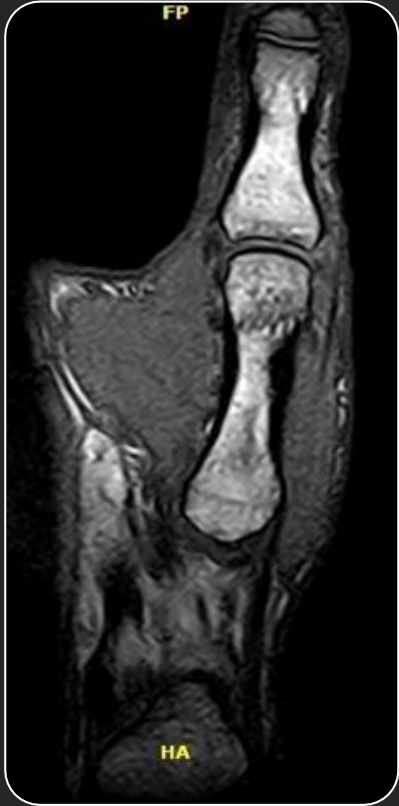

X-Bone T2 (Fat Suppression Echo)  
- Sagittal

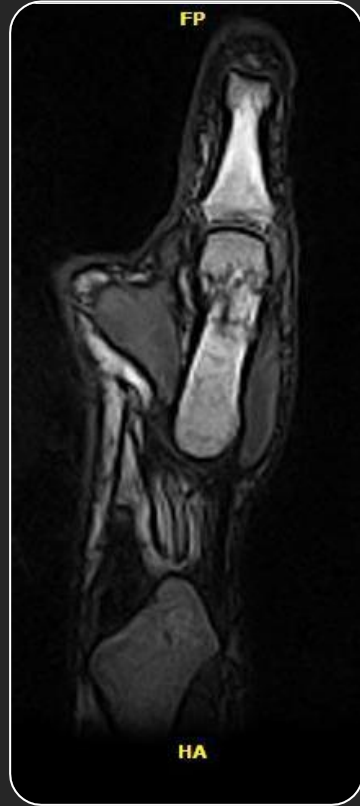

SE T1 - Sagittal

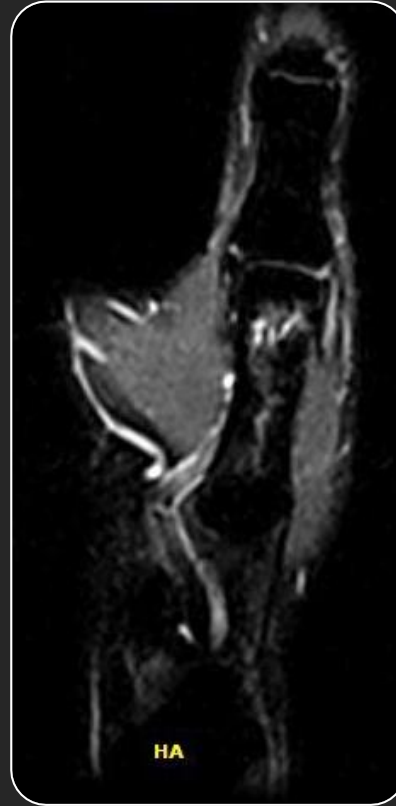
# Hand: Phalangeal Fracture



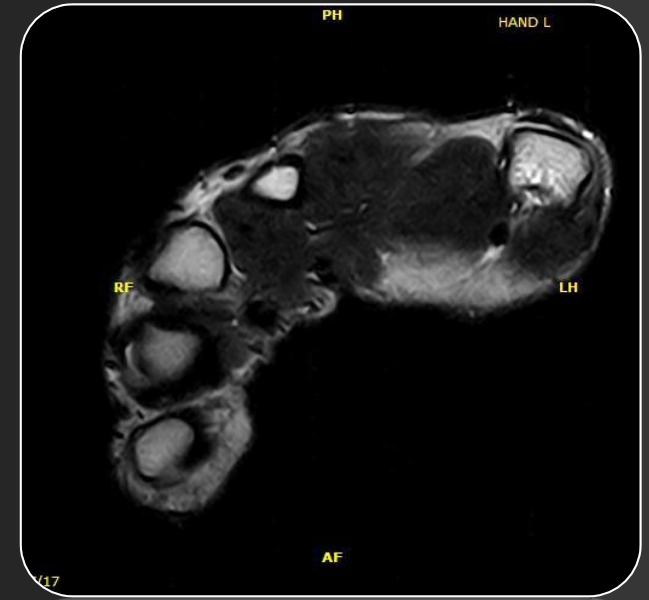3D SHARC - Coronal



3D SST1 - Coronal

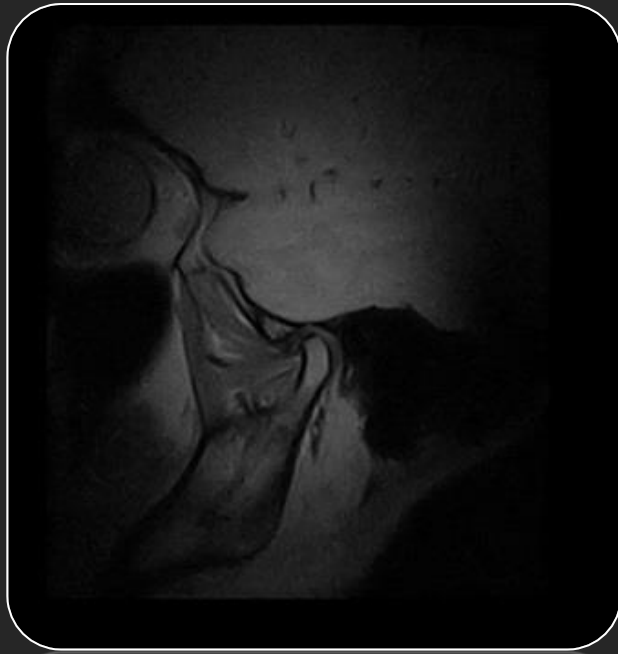


STIR - Coronal

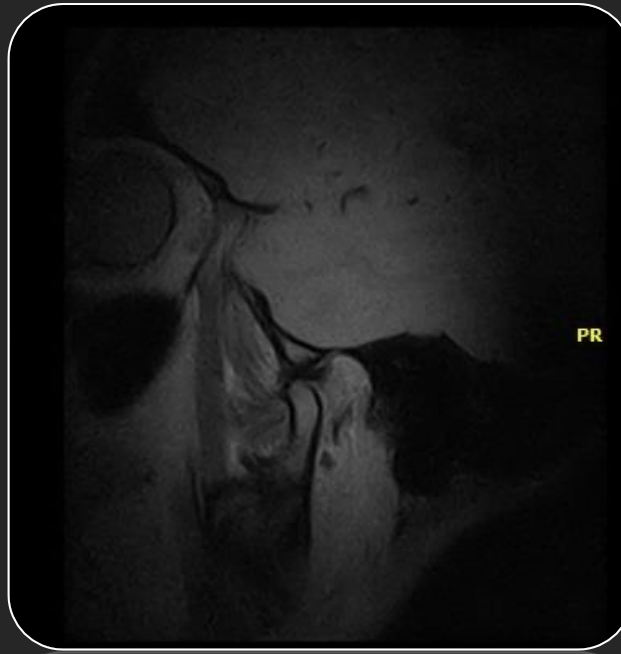


FSE T2 - Axial

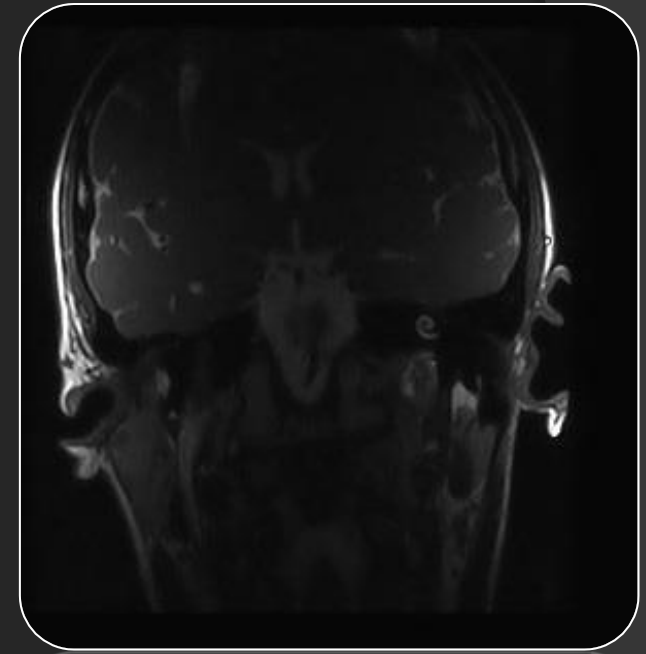
# TMJ: Open&Closed Mouth



FSE PD – Closed Mouth



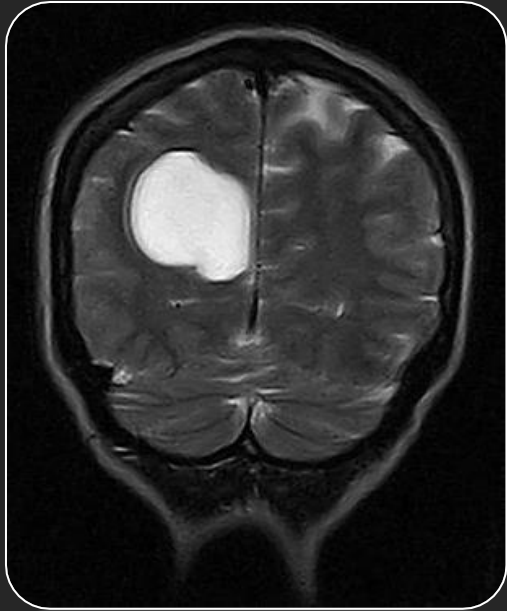FSE PD – Open Mouth



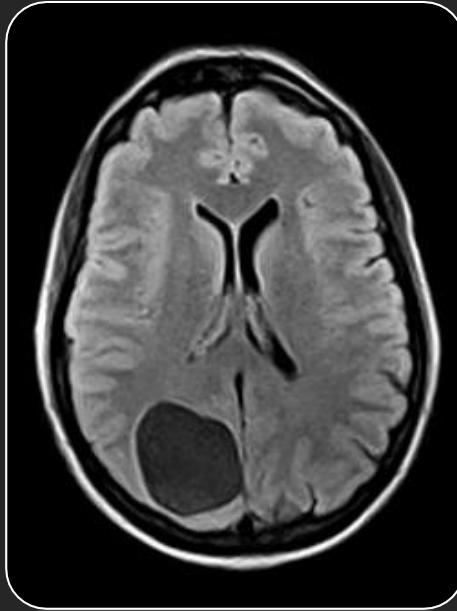
3D HYCE - Coronal



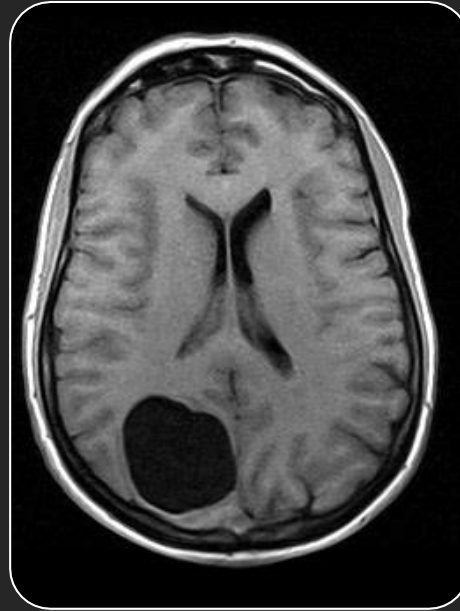
# Brain: Neuroganglion Cyst



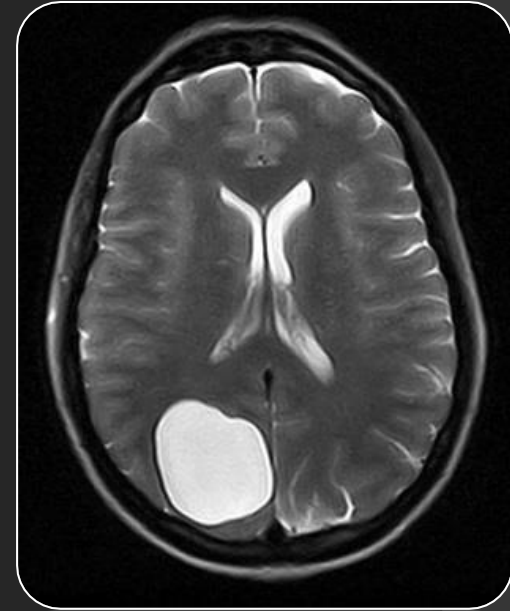
FSE T2 - Coronal



FLAIR T2 - Axial

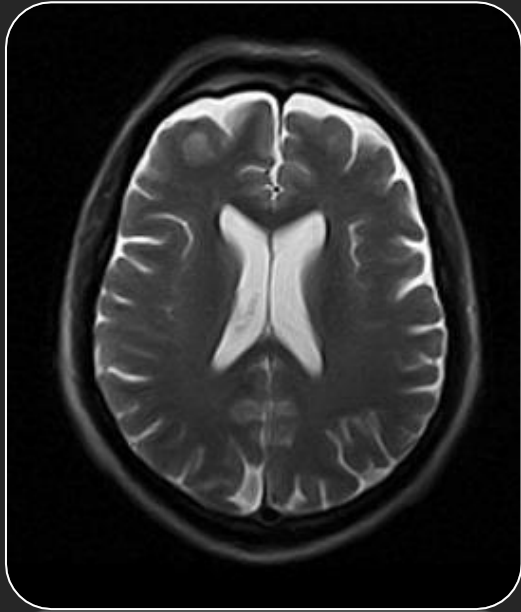


3D SST1 - Axial

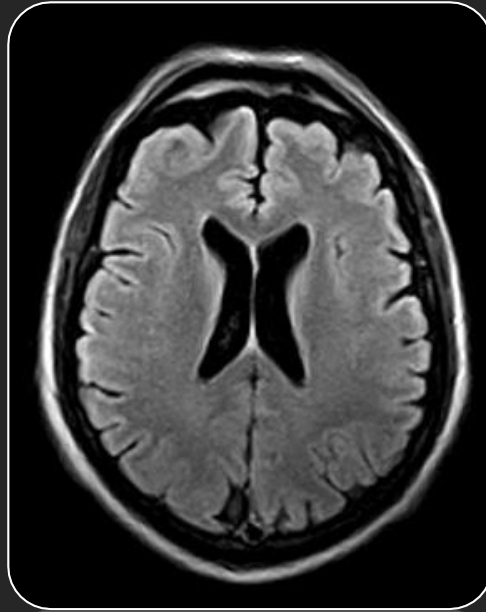


FSE T2 - Axial

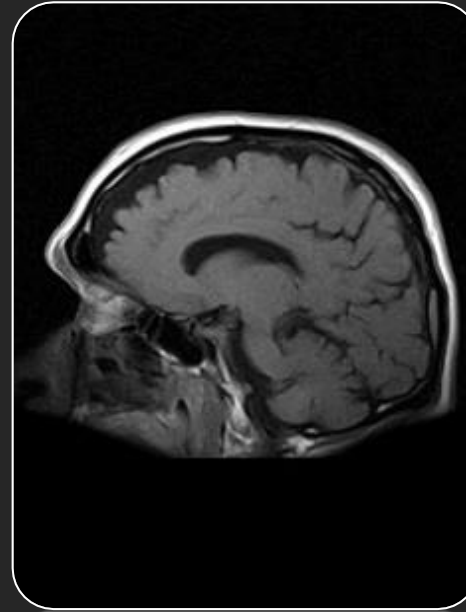
# Brain: Focal Cerebral Atrophy



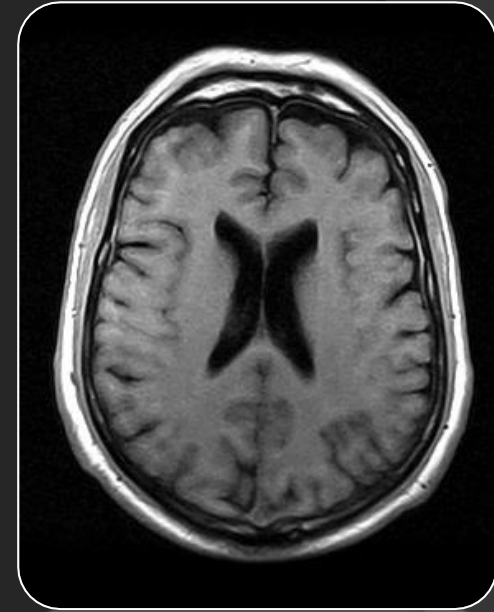
FSE T2 - Axial



FLAIR T2 - Axial

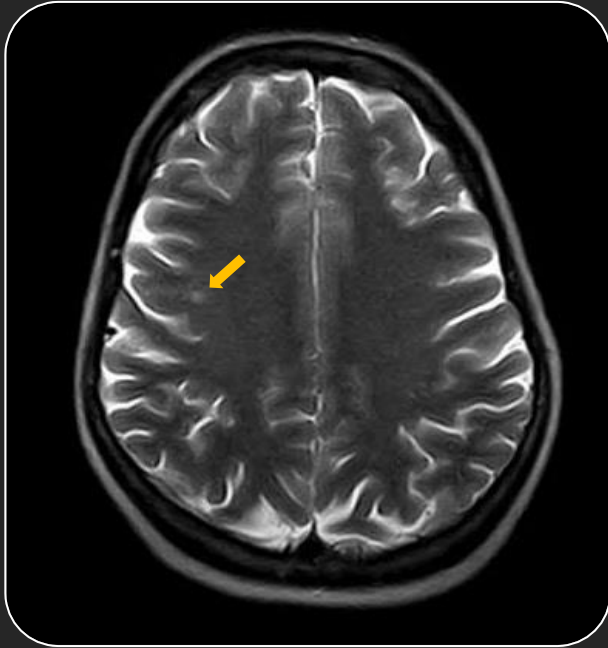


SE T1 - Sagittal

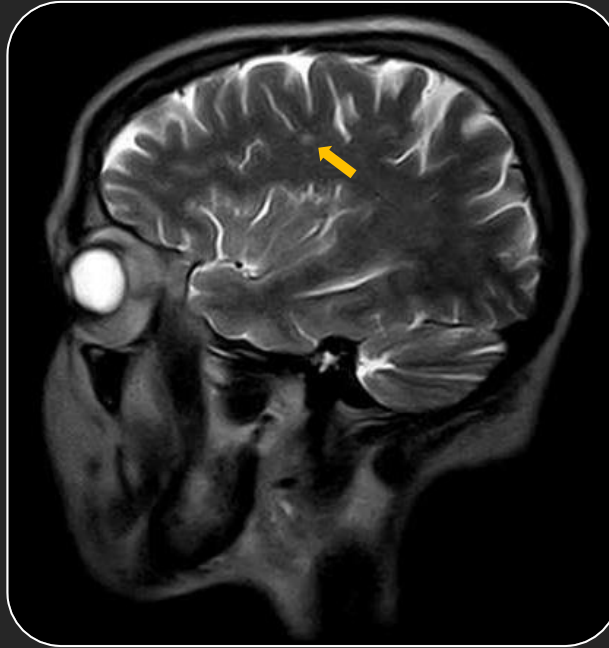


3D SST1 - Axial

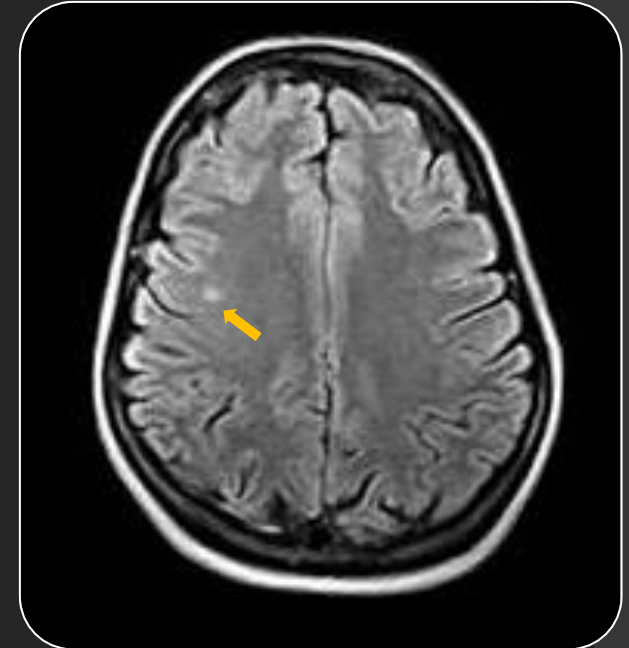
# Brain: Lacunar Ischemic




FSE T2 – Axial



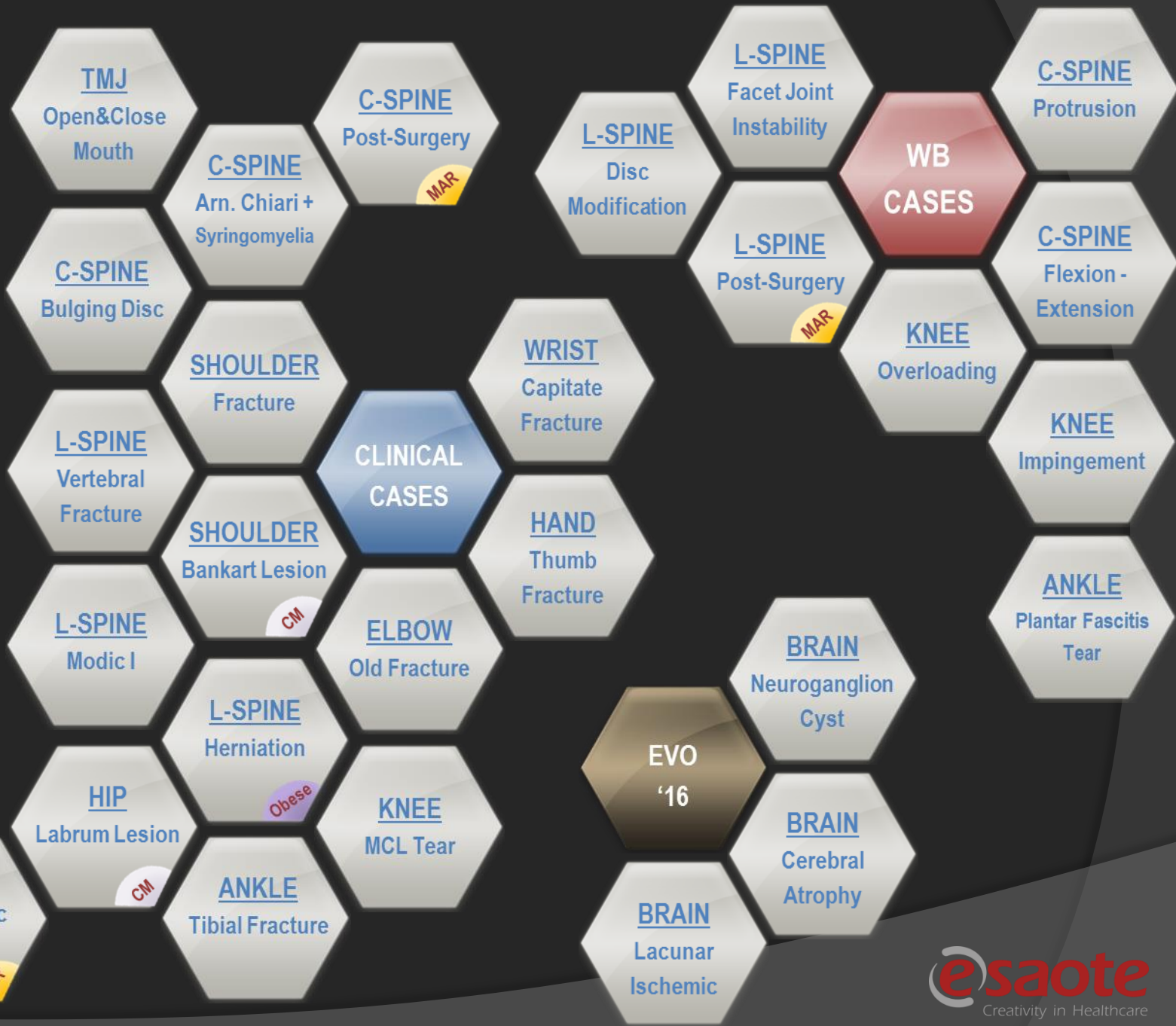FSE T2 – Sagittal



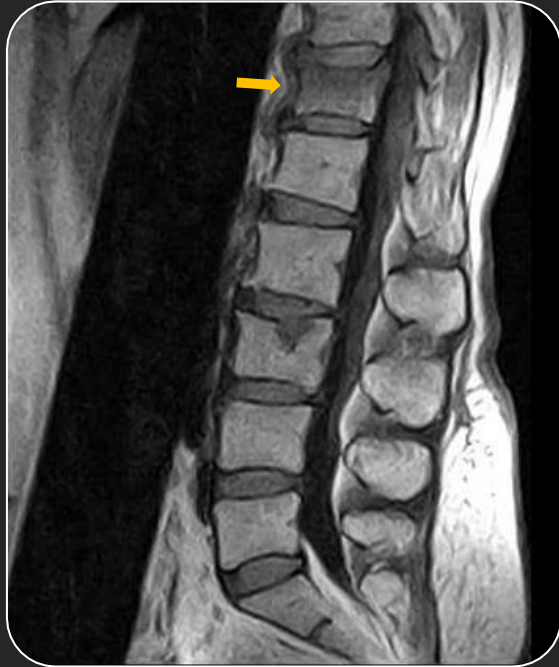
FLAIR - Axial



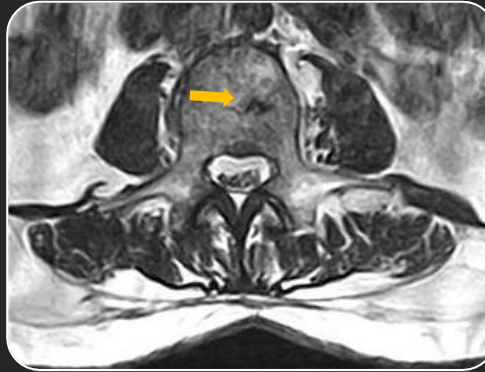
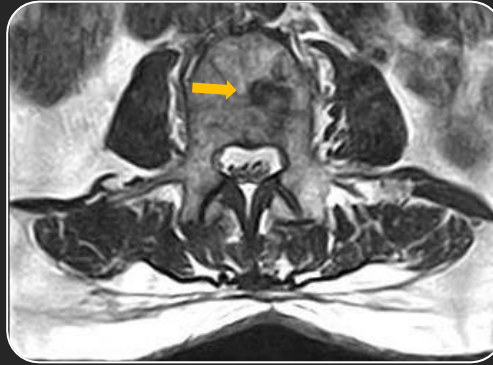**scan brio**  
 eXP Technology  
 The Key to Confidence



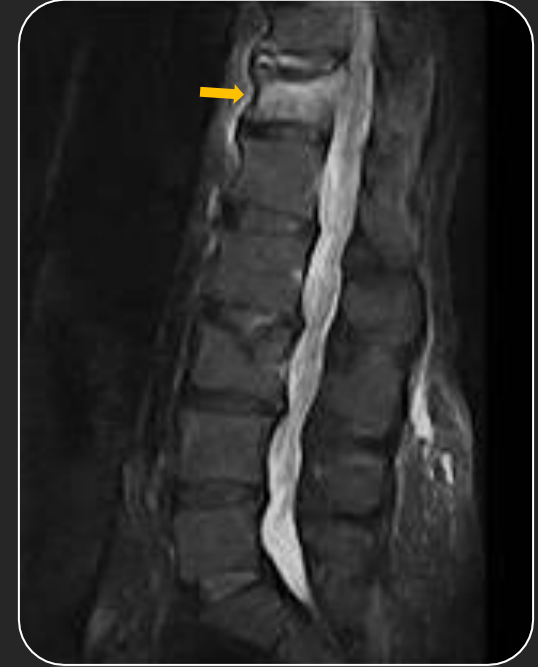# L-Spine: Vertebral Fracture



SE T1 - Sagittal

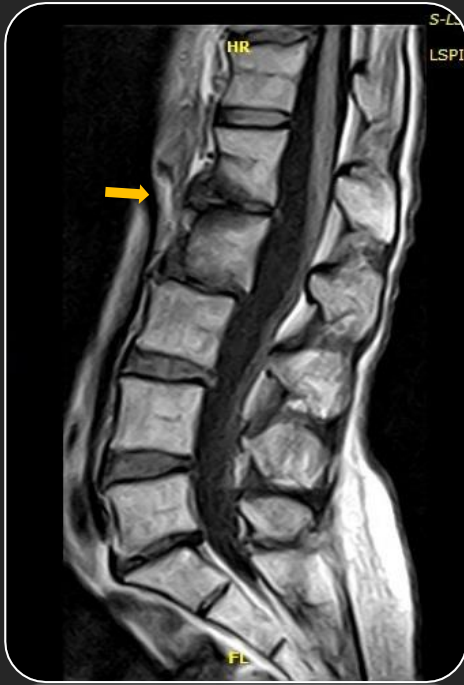

3D HYCE ISO - Axial

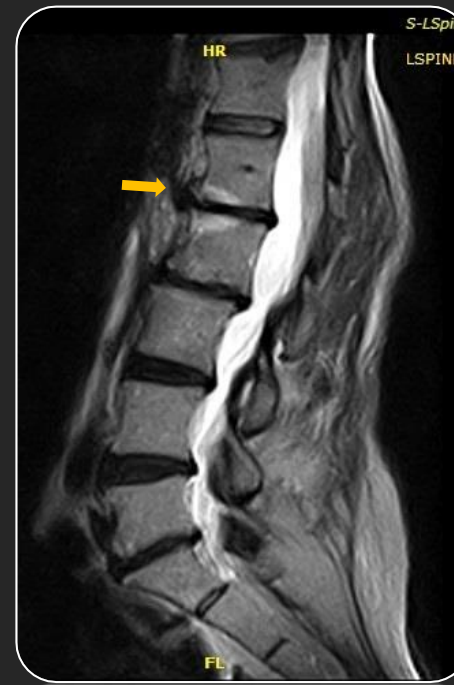
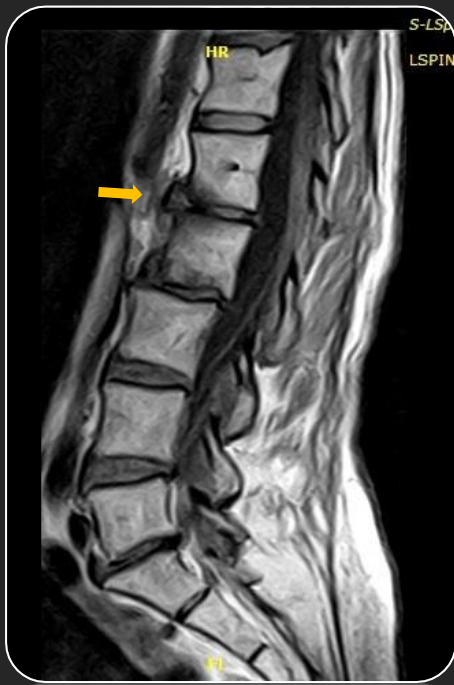
FSTIR - Sagittal

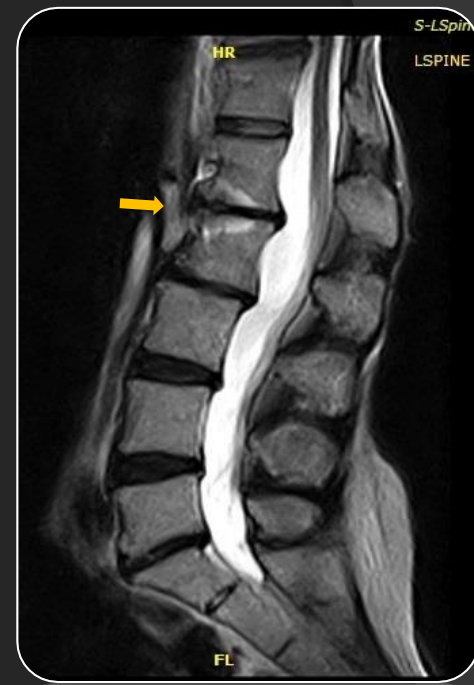# L-Spine: Disc Degeneration (Modic I)



SE T1 - Sagittal



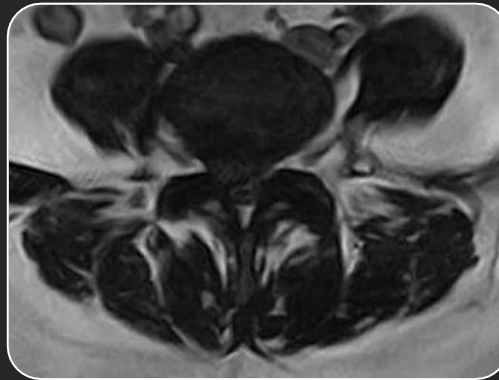
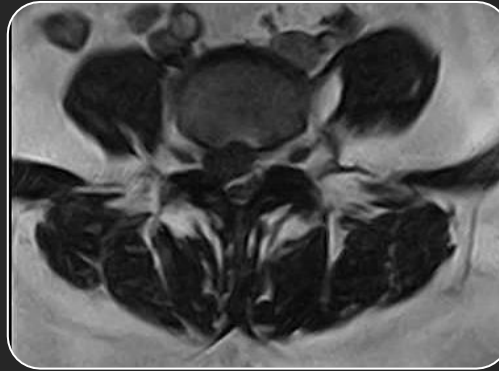
FSE T2 - Sagittal



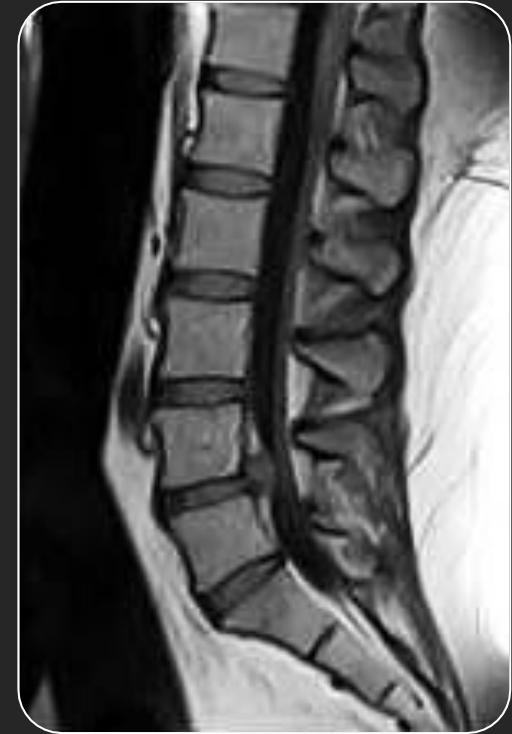# L-Spine: Disc Herniation (Obese Patient)



FSE T2 - Sagittal

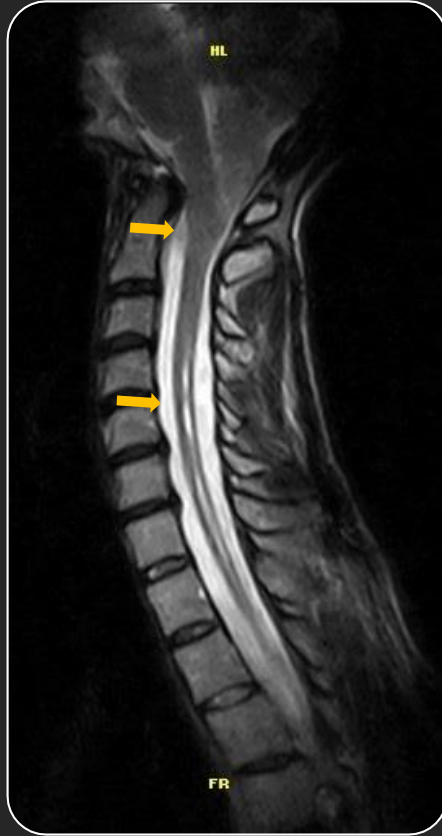


3D HYCE ISO - Axial



SE T1 - Sagittal

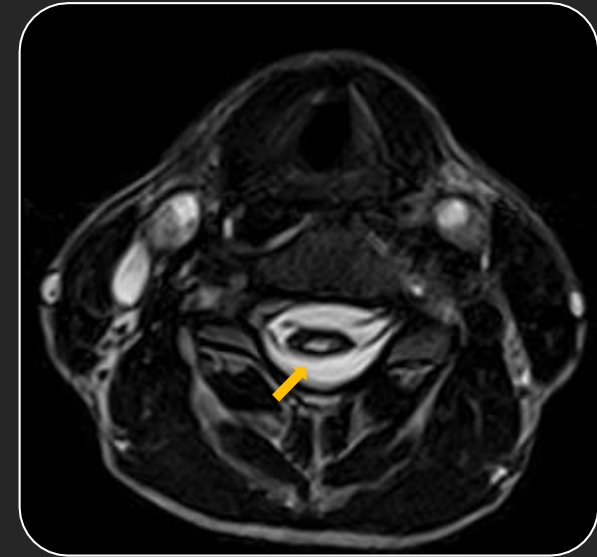
# C-Spine: Arnold Chiari + Syringomyelia



FSE T2 - Sagittal



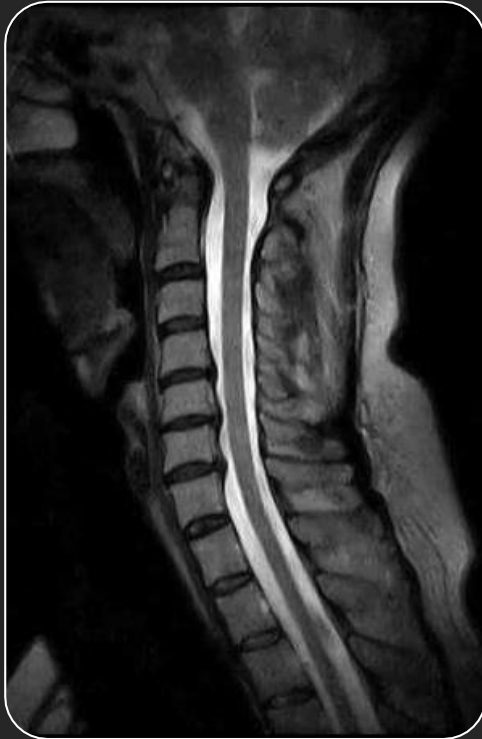SE T1 - Sagittal



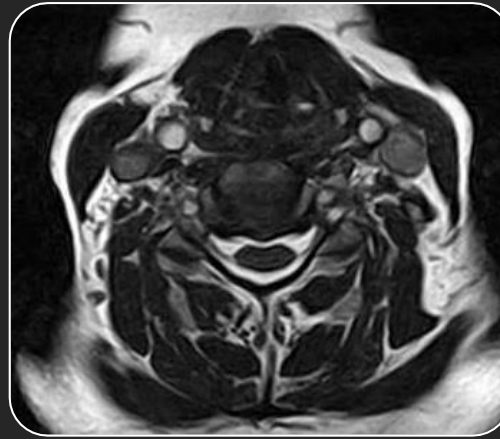3D HYCE ISO - Axial



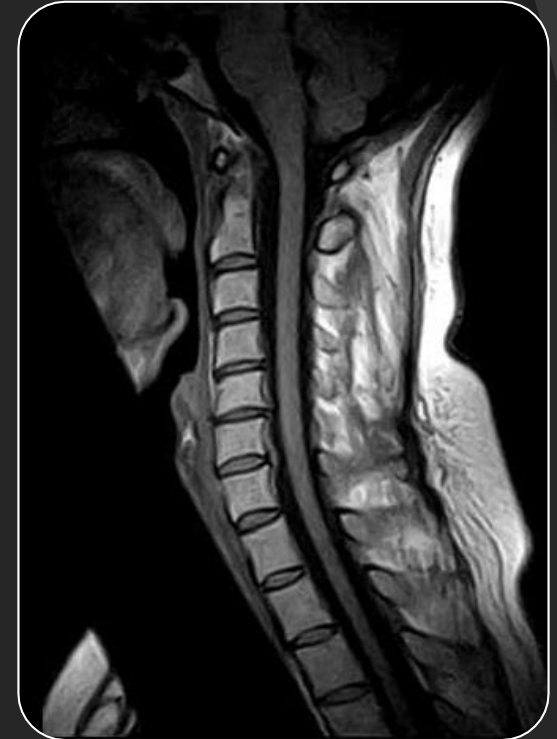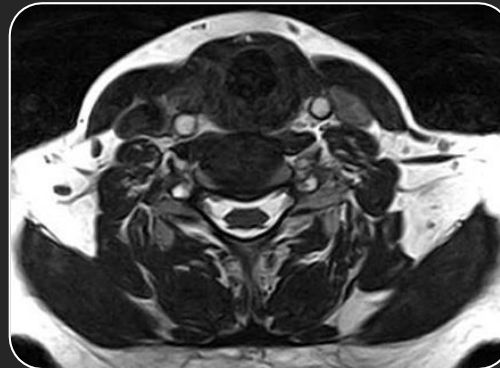
# C-Spine: Bulging Disc



FSE T2 - Sagittal



3D HYCE ISO - Axial

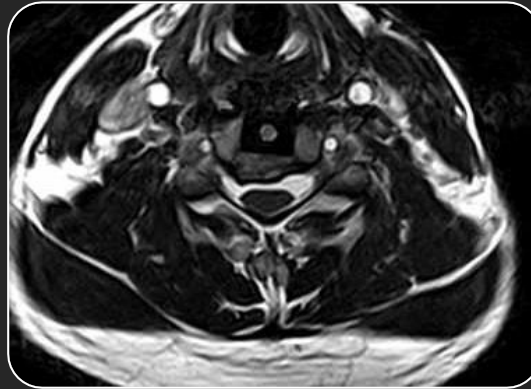
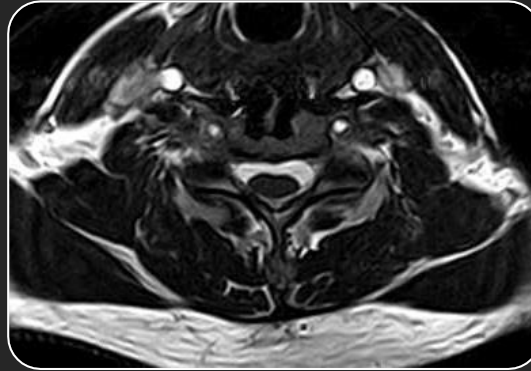


SE T1 - Sagittal

# C-Spine: Postsurgical Fixation (MAR)



FSE T2 - Sagittal

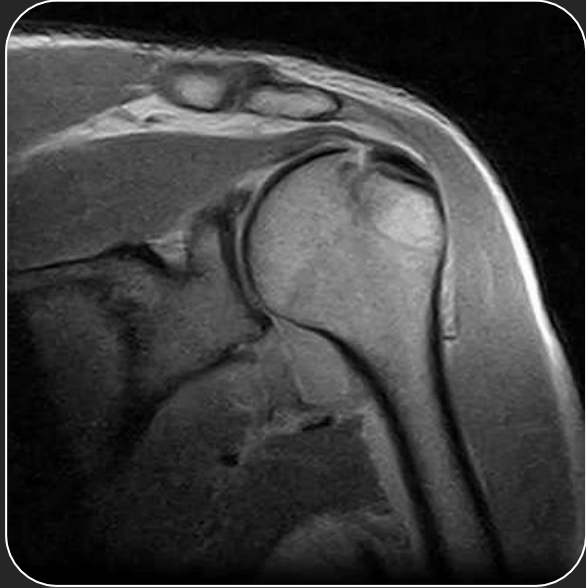

3D HYCE ISO - Axial

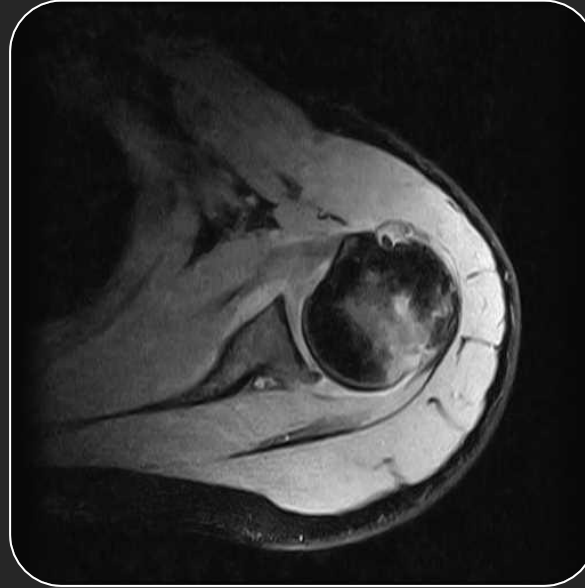


SE T1 - Sagittal

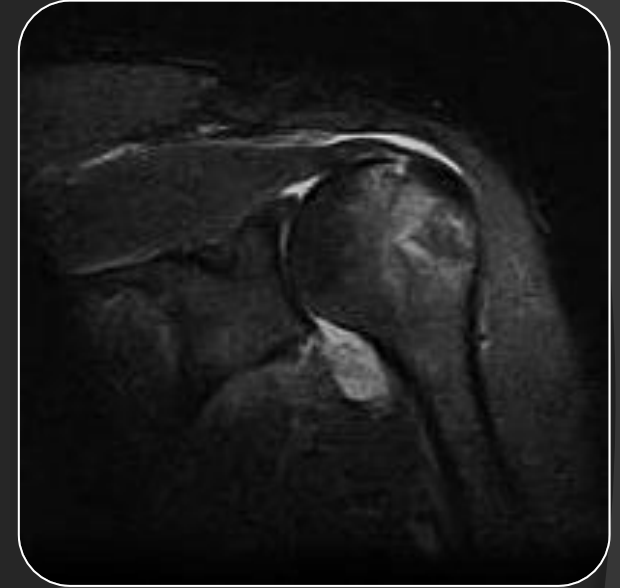
# Shoulder: Greater Trochanter Fracture



FSE PD - Coronal

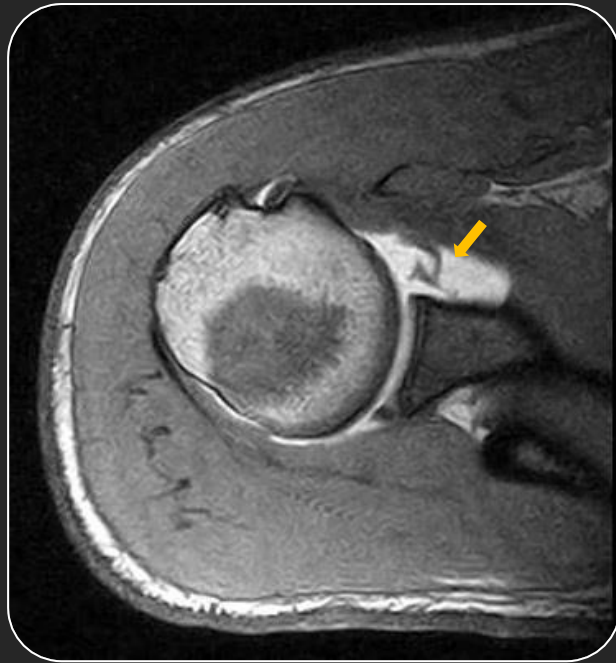

X-Bone T2 (Fat Suppression Echo) - Axial

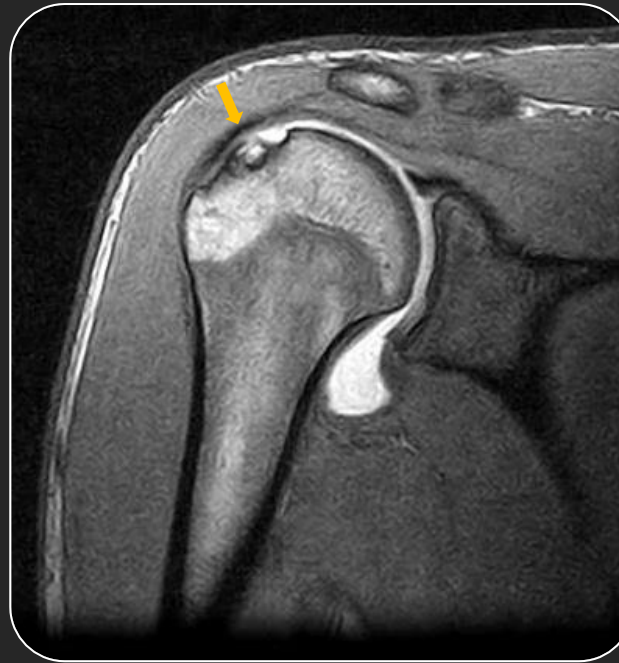

FSTIR - Coronal

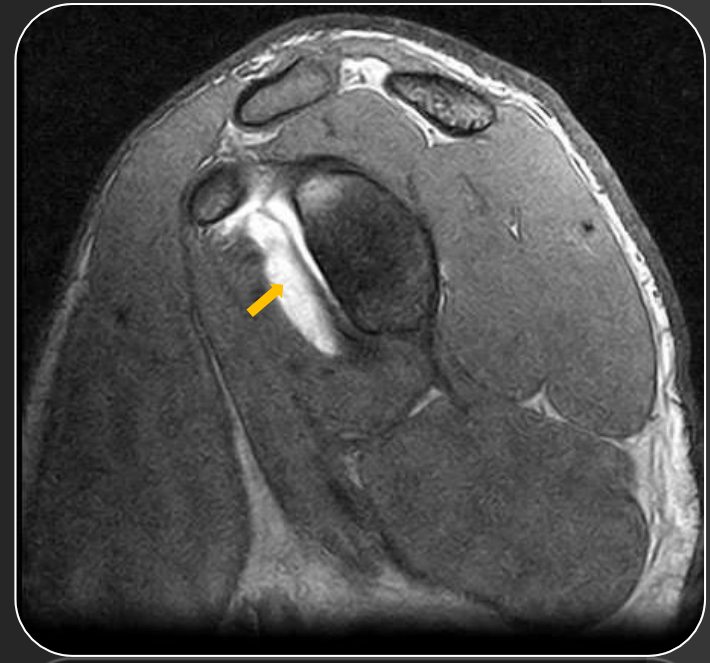# Shoulder: Bankart Lesion + Hill Sachs (CM)



3D SHARC (CM) - Axial

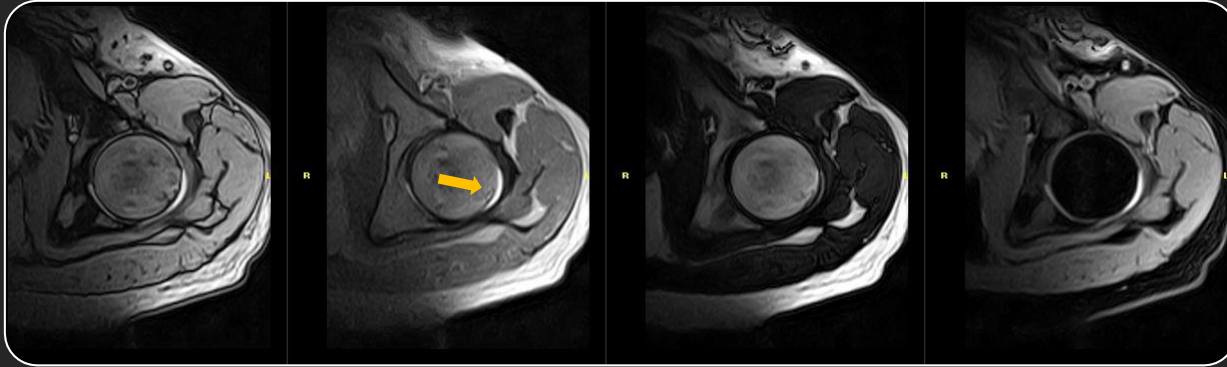


3D SHARC (CM) - Coronal



3D SHARC (CM) - Sagittal

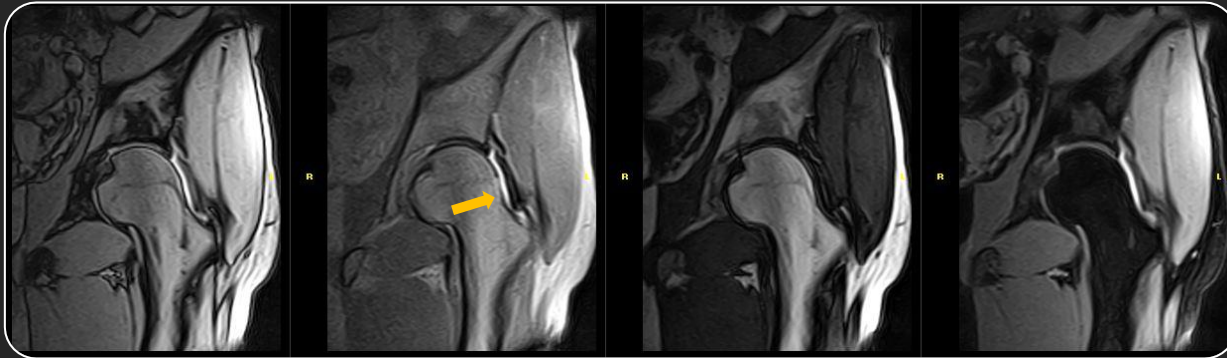
# Hip: Labrum Lesion (CM)



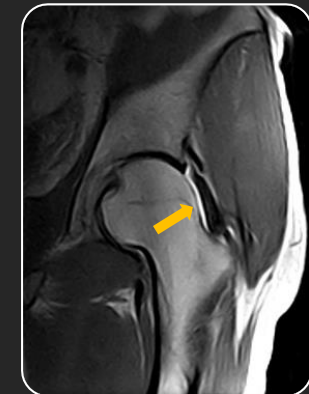
X-Bone T2 - Axial



SE T1 (CM) - Axial

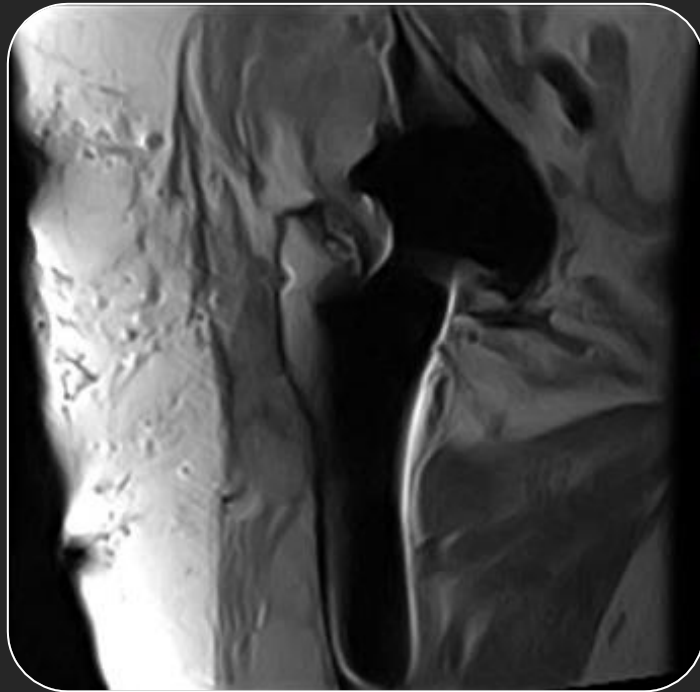


X-Bone T2 - Coronal

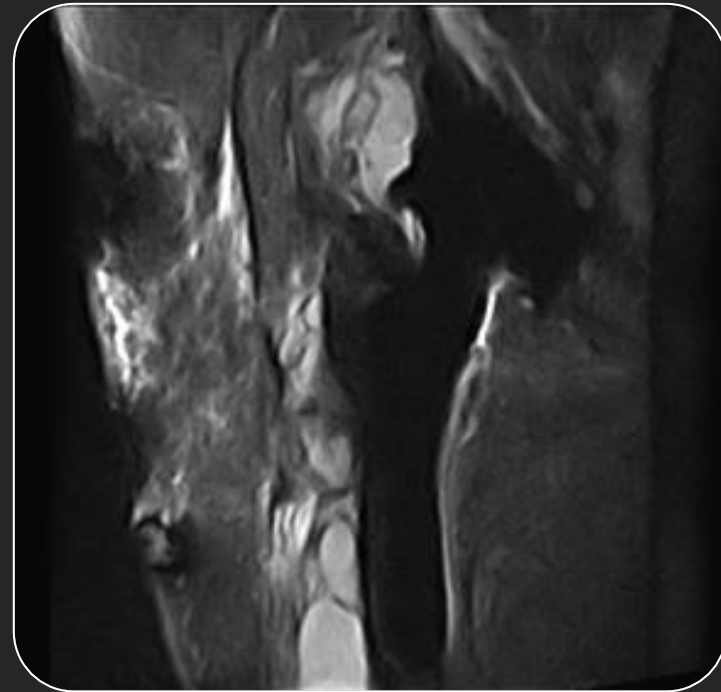


SE T1 (CM) - Coronal

# Hip: Replacement Prosthesis w/ MAR

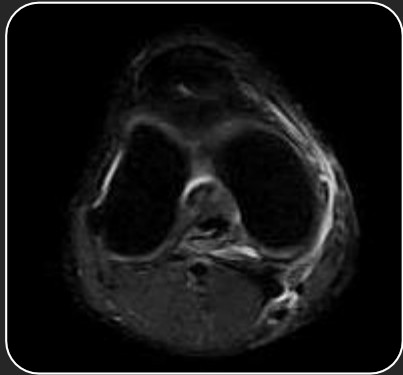


SE T1 (MAR) - Coronal

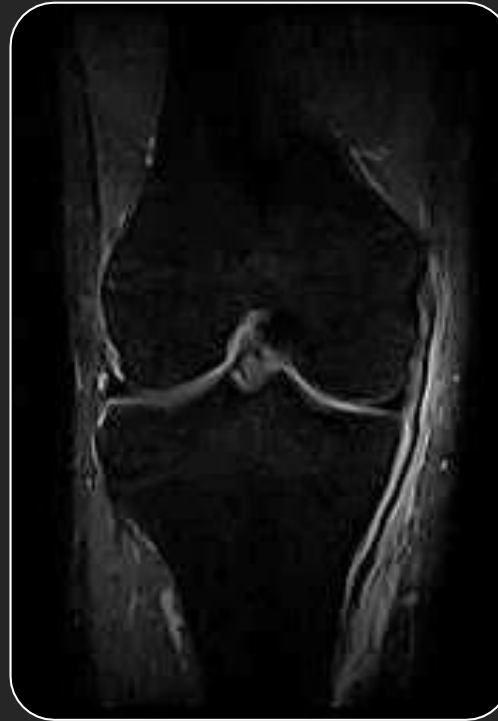

FSTIR (MAR) - Coronal

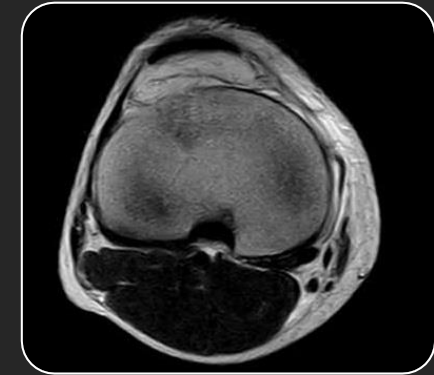# Knee: MCL Tear + Pes Anserinus



FSTIR - Axial

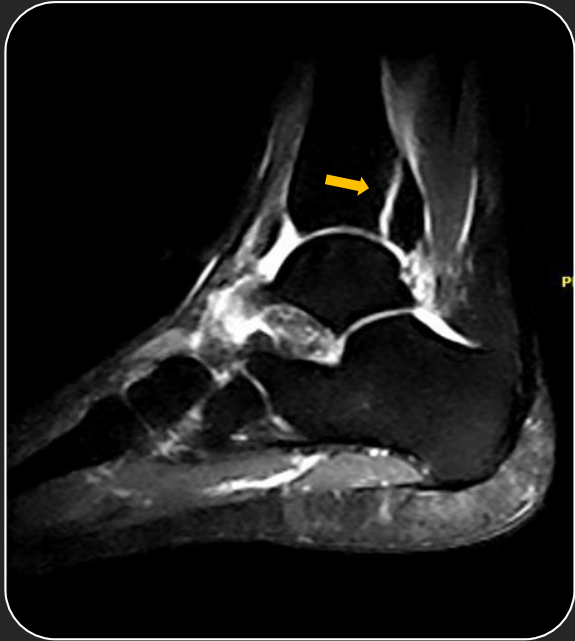

FSTIR - Coronal

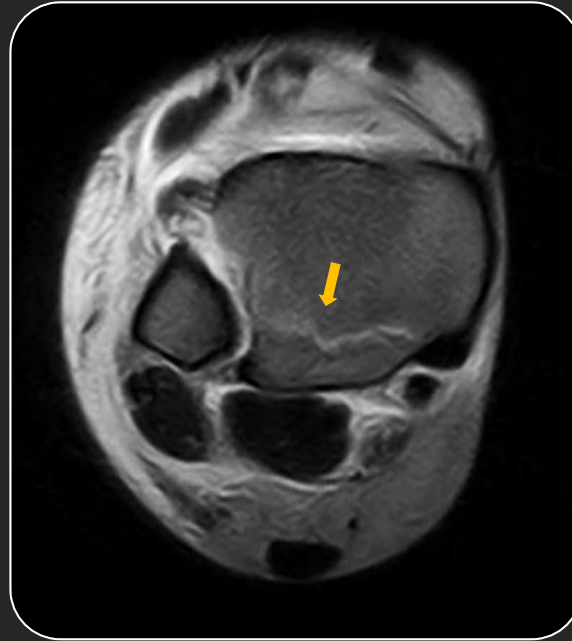


FSE T2 - Axial

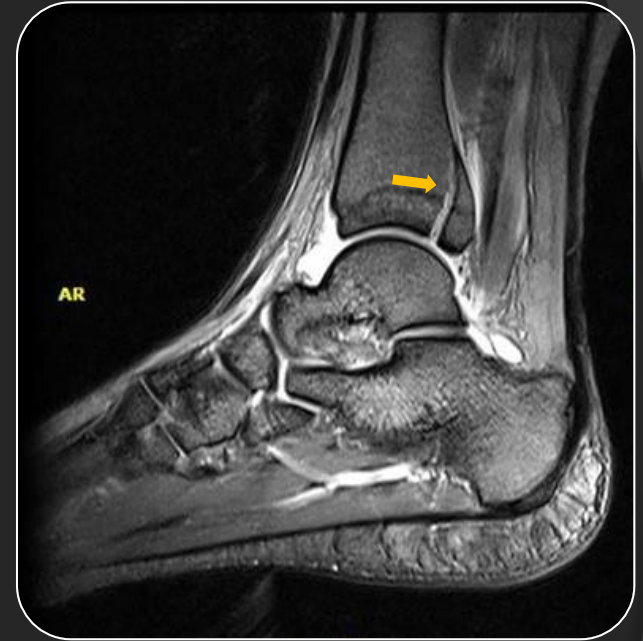# Ankle: Tibial Fracture



GE STIR - Sagittal



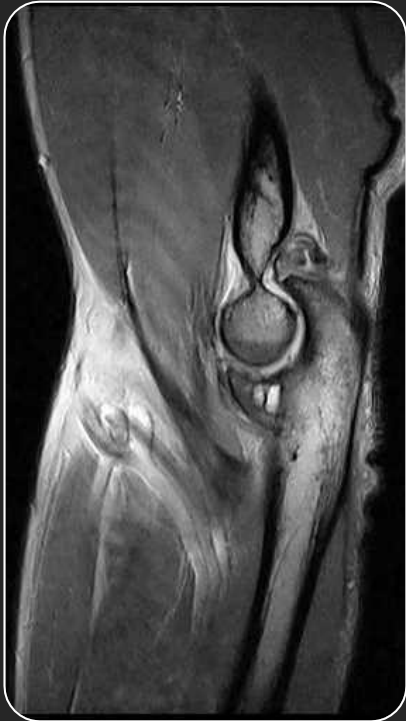FSE T2 - Axial



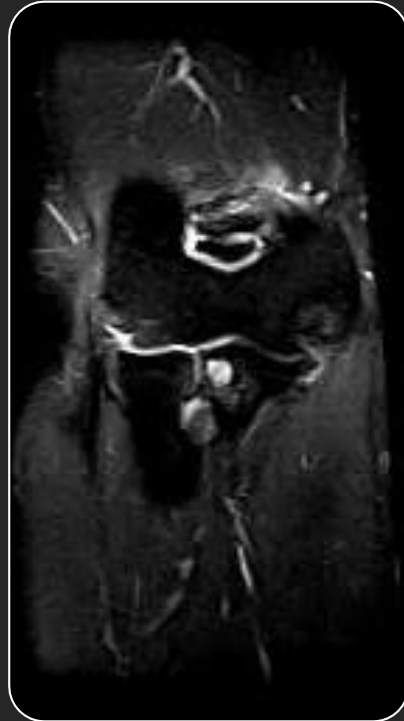
GE T2 - Sagittal



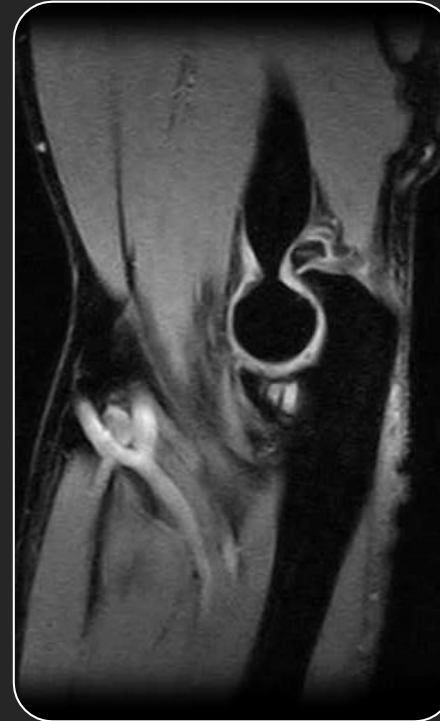
# Elbow: Old Fracture



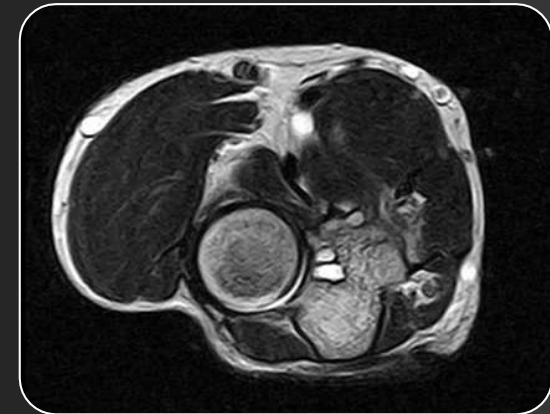GE T2 - Sagittal



FSTIR - Coronal



X-Bone T2 (Fat Suppression Echo)  
- Sagittal



FSE T2 - Axial

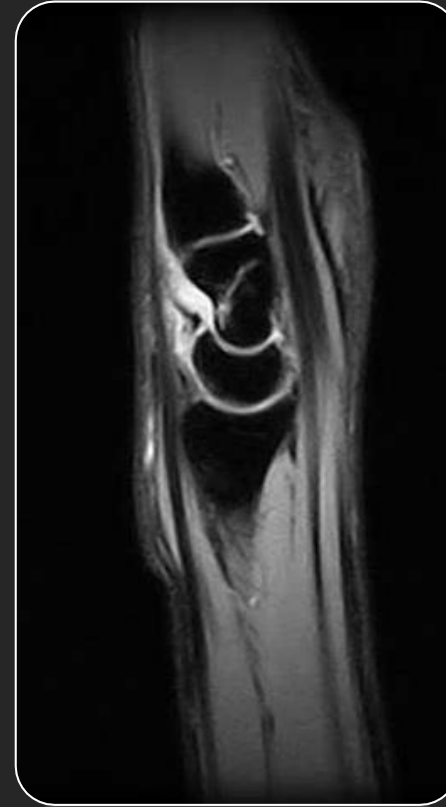
# Wrist: Capitate Fracture



GE STIR - Coronal



3D SHARC ISO - Coronal

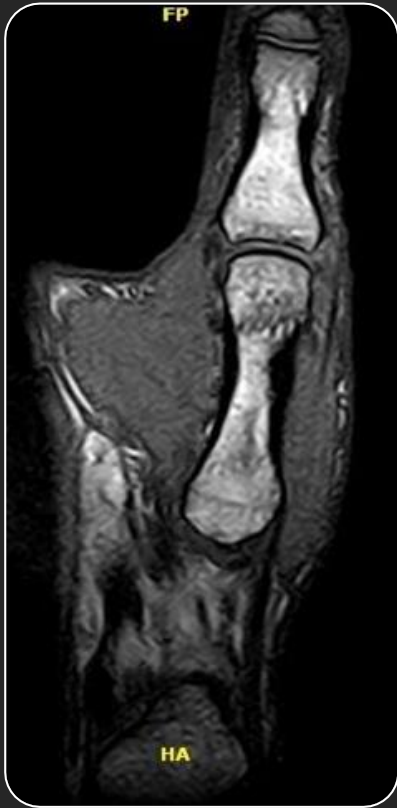

X-Bone T2 (Fat Suppression Echo)  
- Sagittal

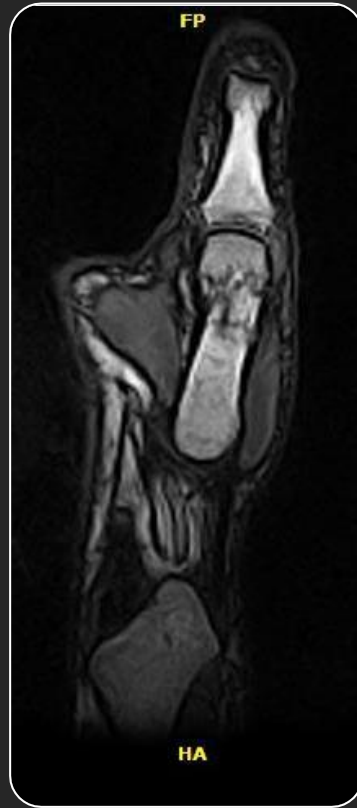


SE T1 - Sagittal

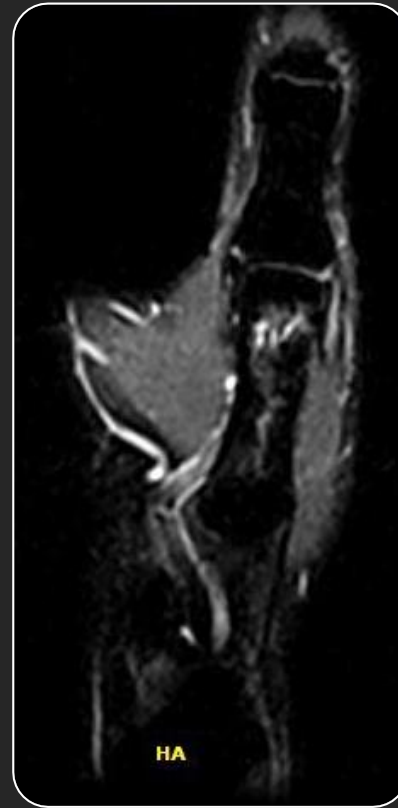
# Hand: Phalangeal Fracture



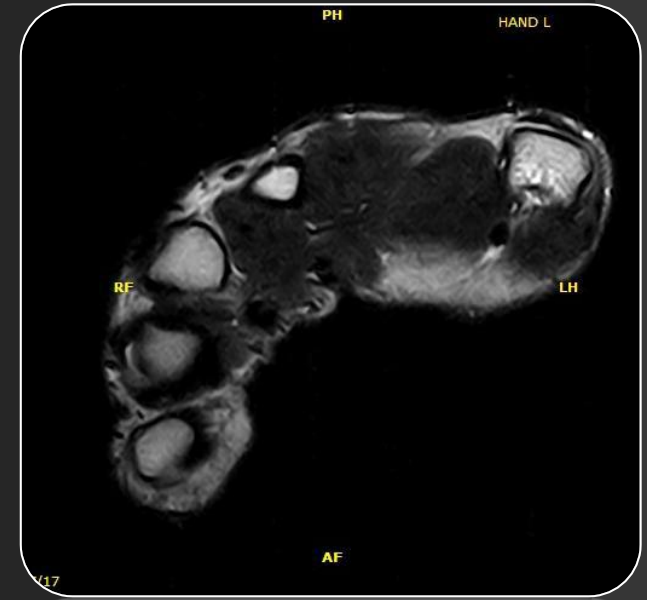3D SHARC - Coronal



3D SST1 - Coronal

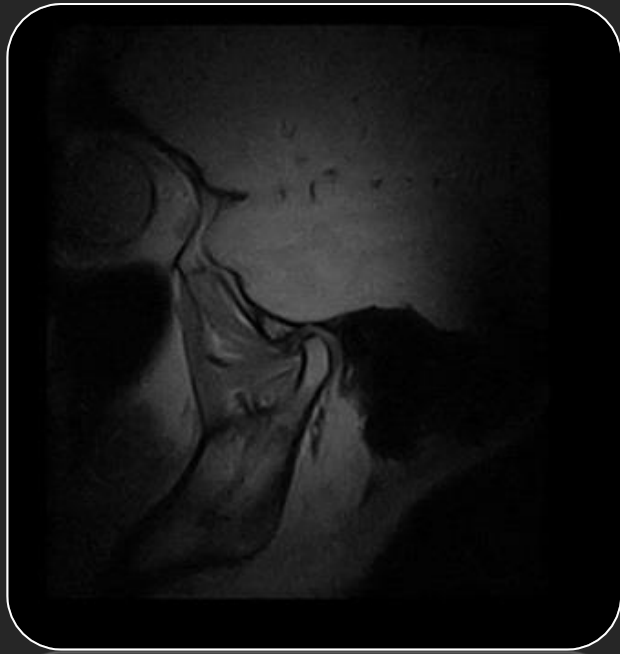

STIR - Coronal

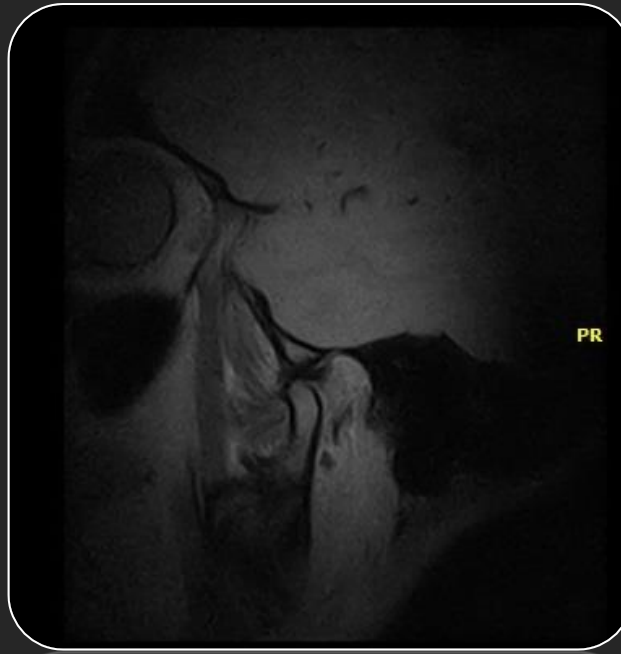


FSE T2 - Axial

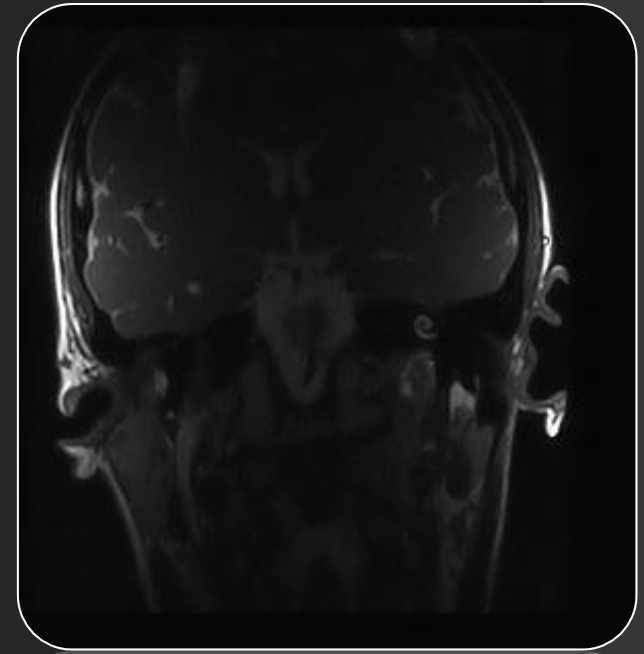
# TMJ: Open&Closed Mouth



FSE PD – Closed Mouth

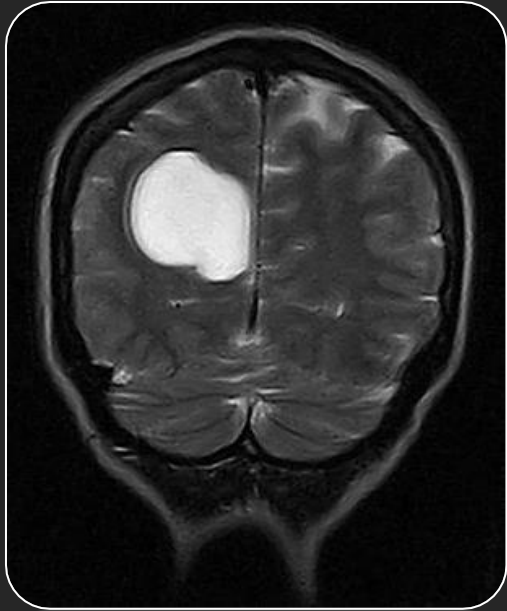


FSE PD – Open Mouth

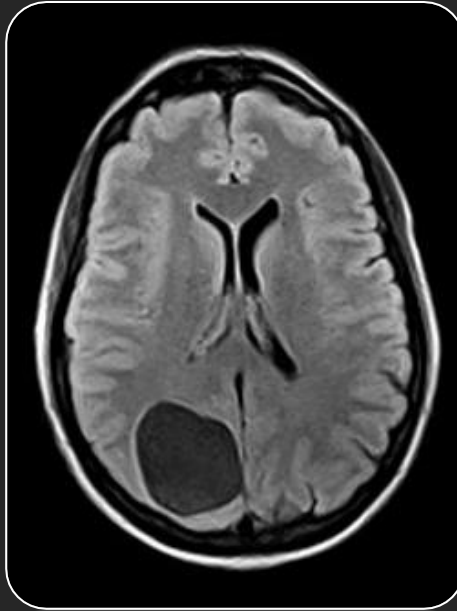


3D HYCE - Coronal

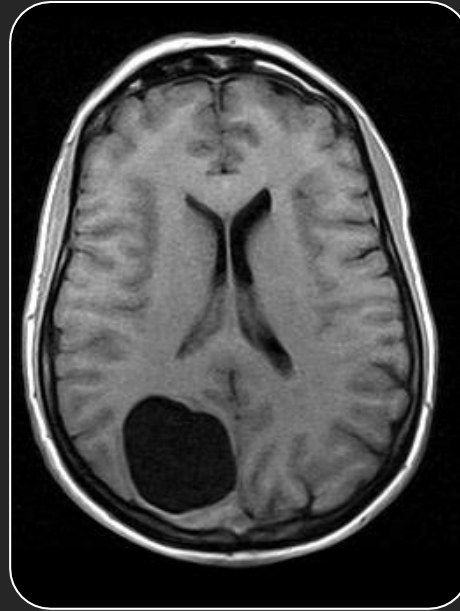
# Brain: Neuroganglion Cyst



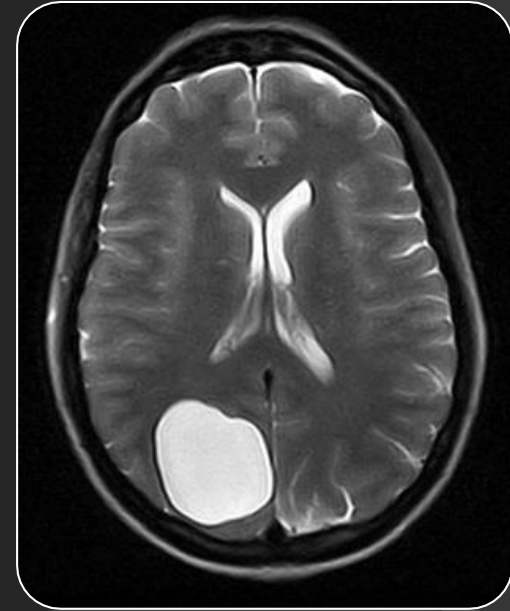
FSE T2 - Coronal



FLAIR T2 - Axial

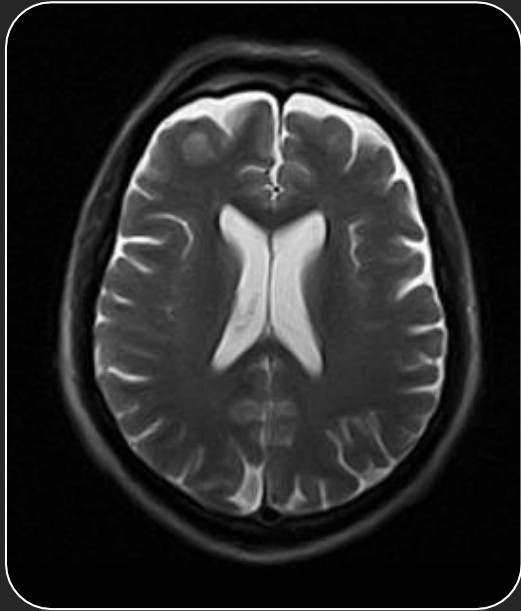


3D SST1 - Axial

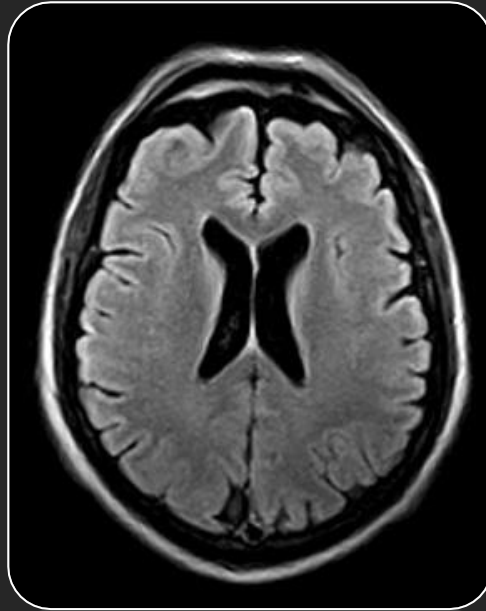


FSE T2 - Axial

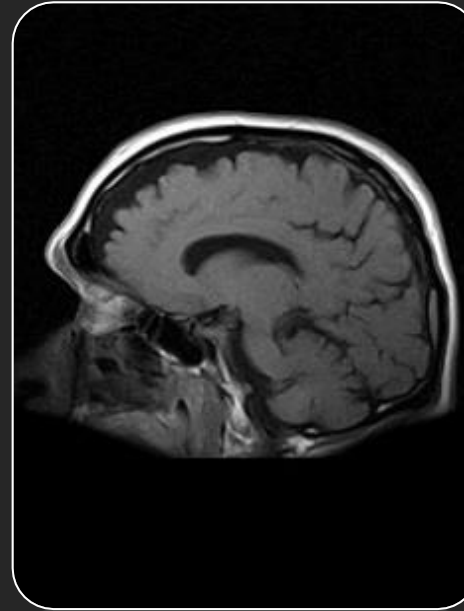
# Brain: Focal Cerebral Atrophy



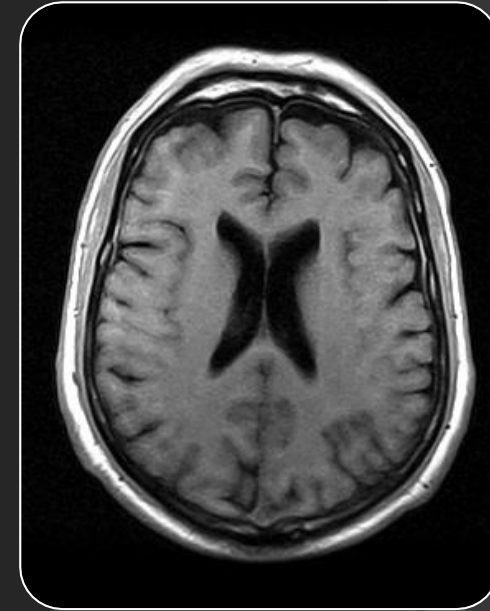
FSE T2 - Axial



FLAIR T2 - Axial

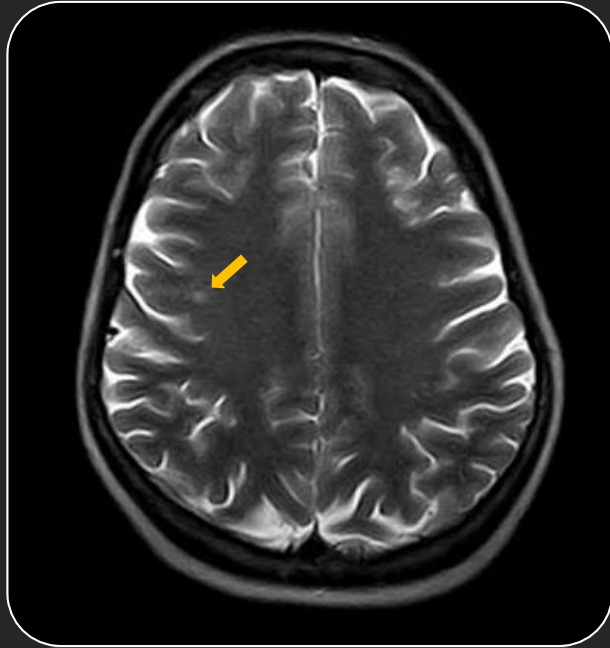


SE T1 - Sagittal

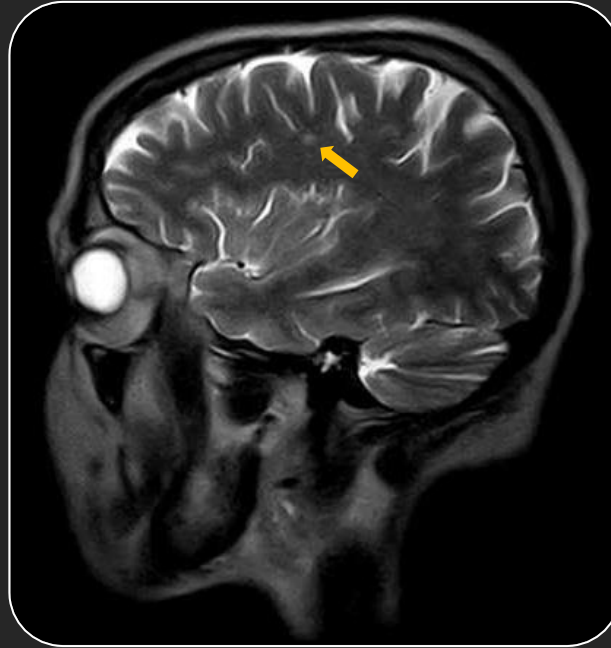


3D SST1 - Axial

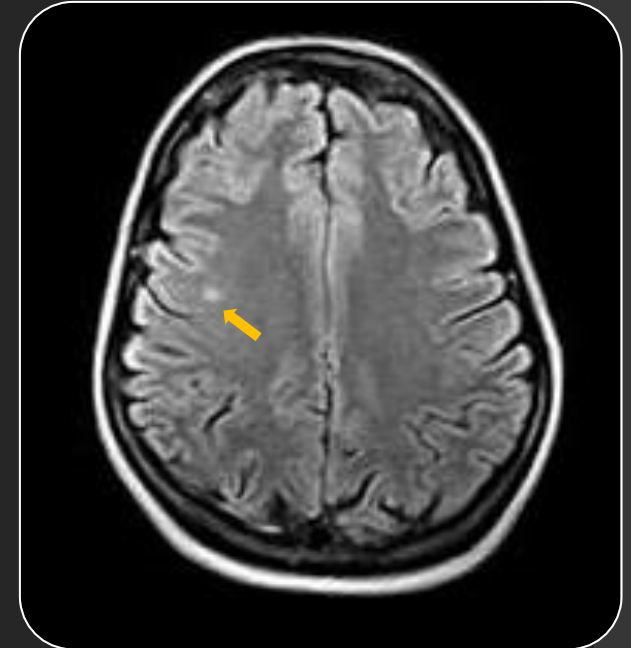
# Brain: Lacunar Ischemic



FSE T2 – Axial

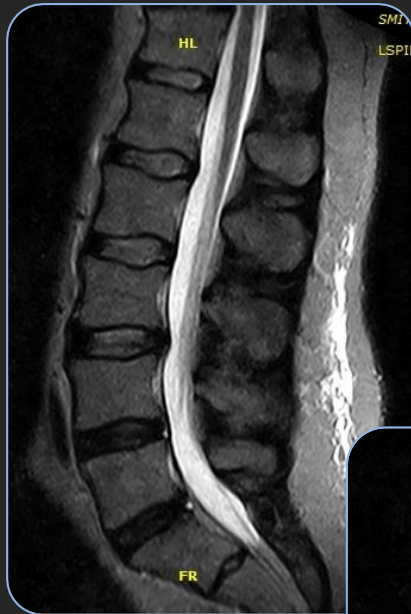

FSE T2 – Sagittal

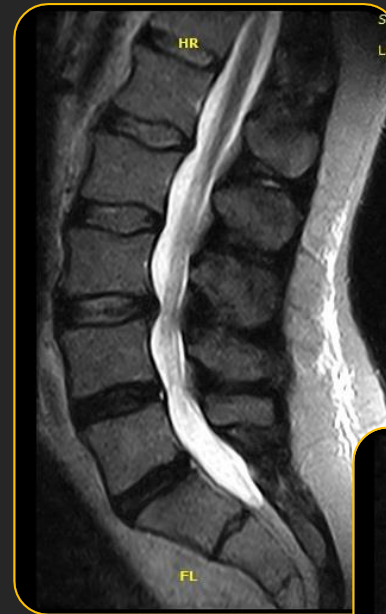

FLAIR - Axial

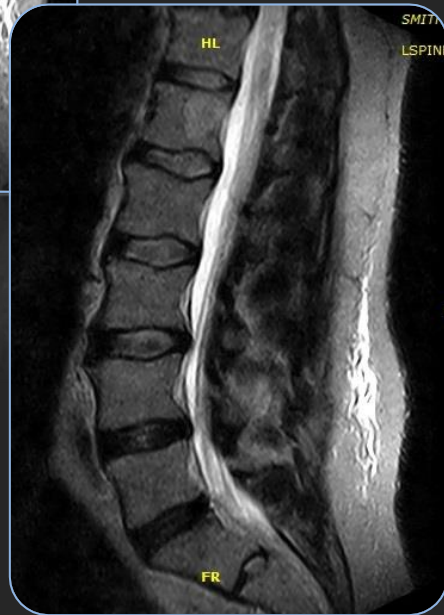# L-Spine: Disc WB Modifications



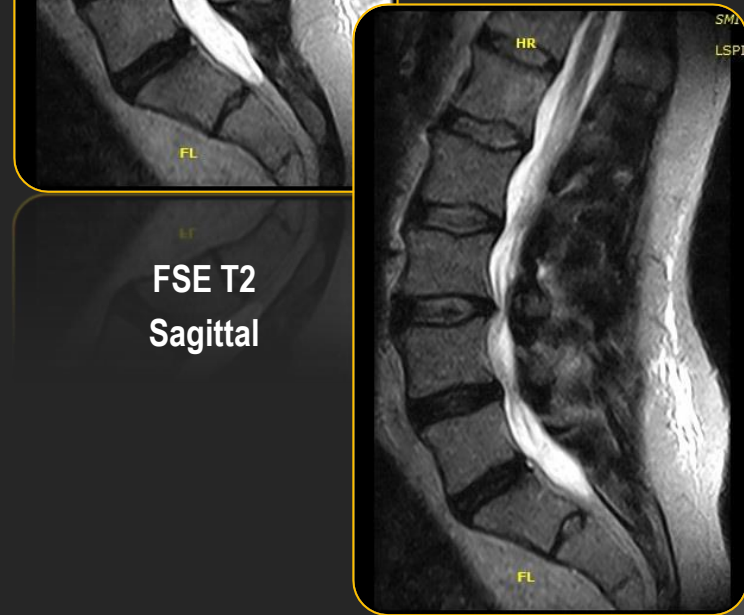
 Supine



 Weight Bearing



FSE T2  
Sagittal

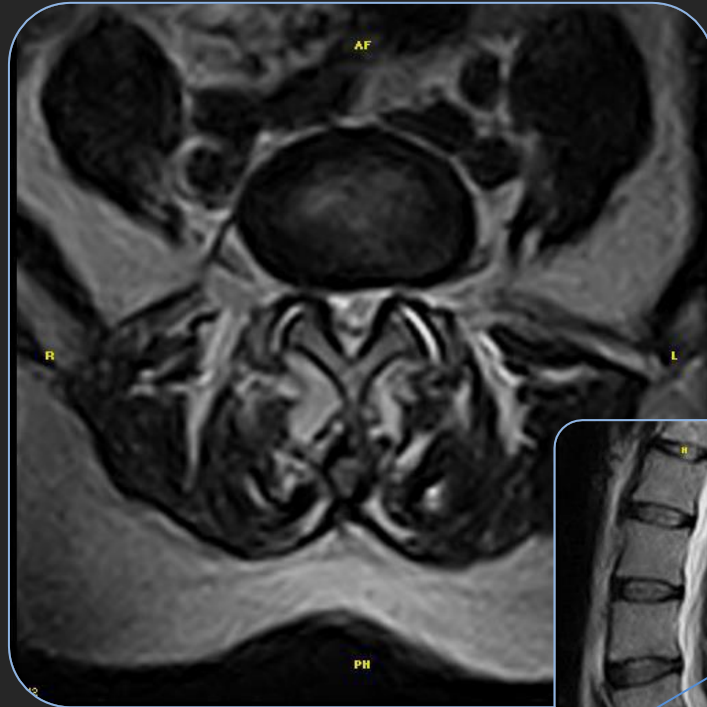


FSE T2  
Sagittal

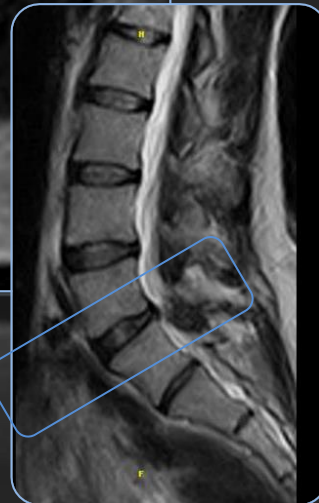


# L-Spine: Facet Joint Instability (WB)

 **Supine**

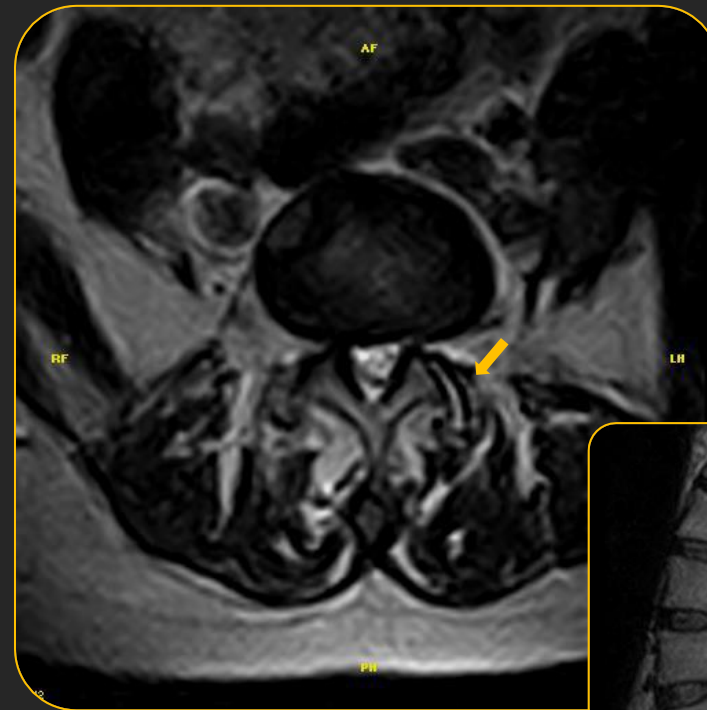


FSE T2 – Axial

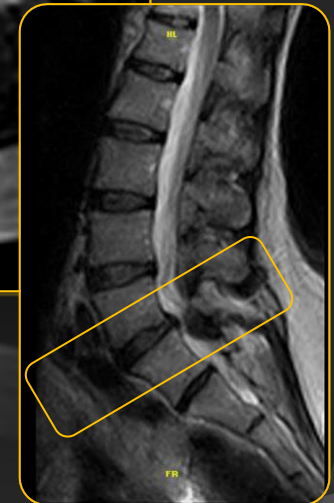


FSE T2 – Sagittal

 **Weight Bearing**



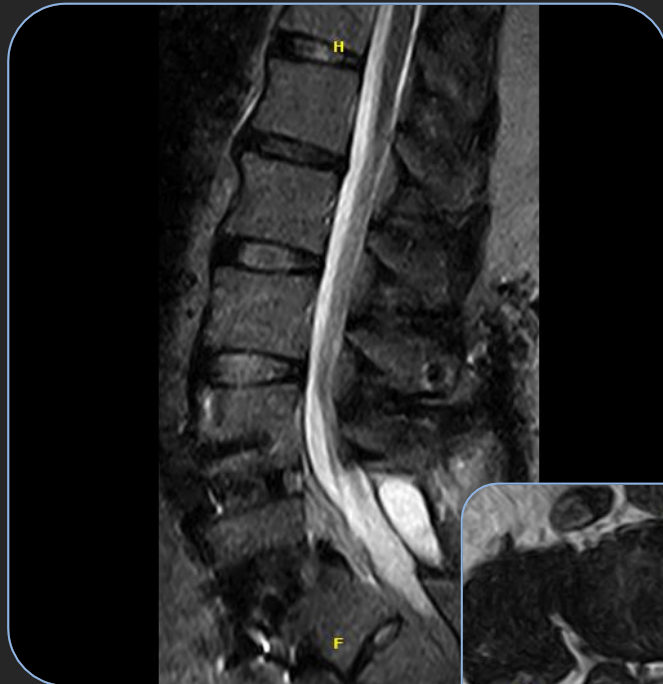FSE T2 – Axial



FSE T2 – Sagittal

# L-Spine: Post-Surgery (WB)

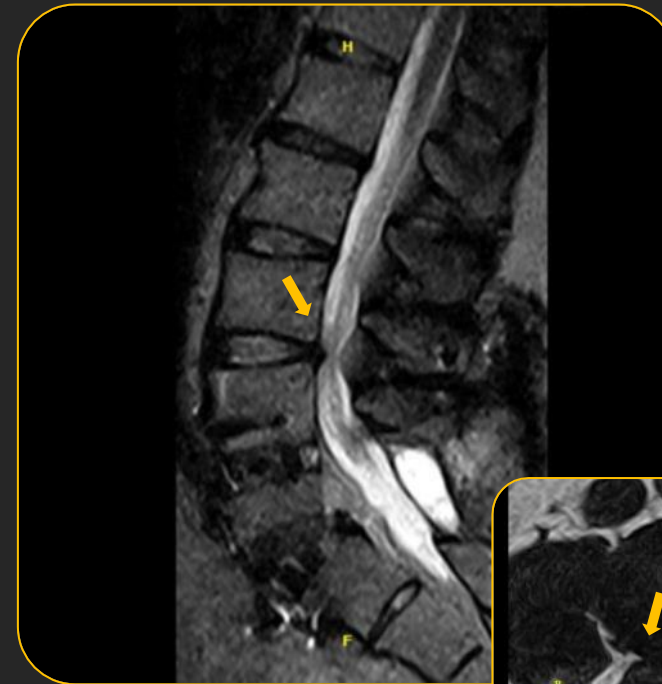 **Supine**



FSE T2 – Sagittal

FSE T2 – Axial

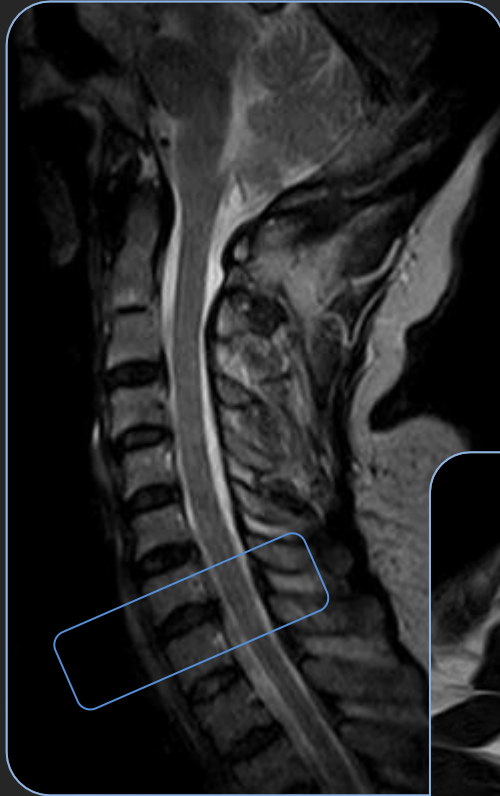 **Weight Bearing**



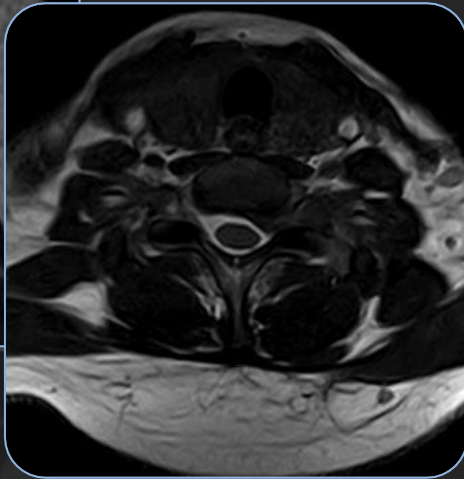
FSE T2 – Sagittal

FSE T2 – Axial

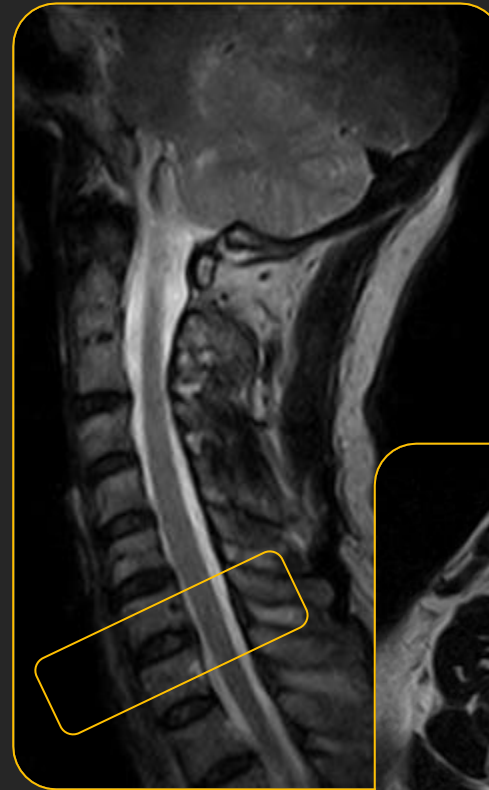# C-Spine: Disc Protrusion (WB)



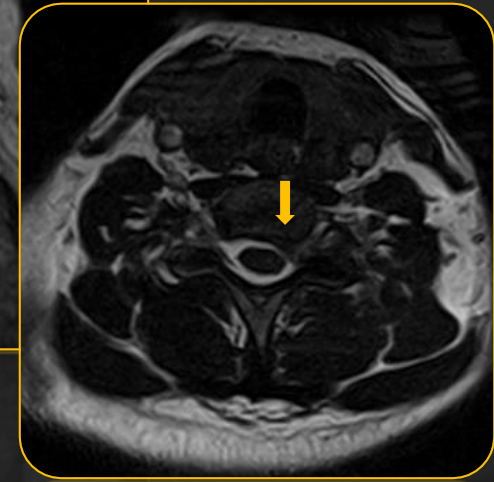
 Supine



3D HYCE - Axial

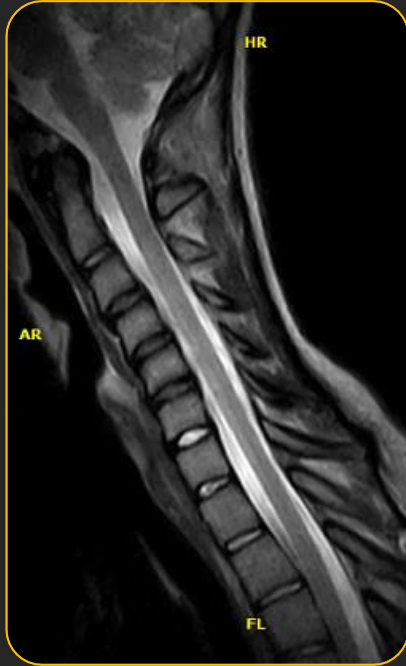

 Weight Bearing

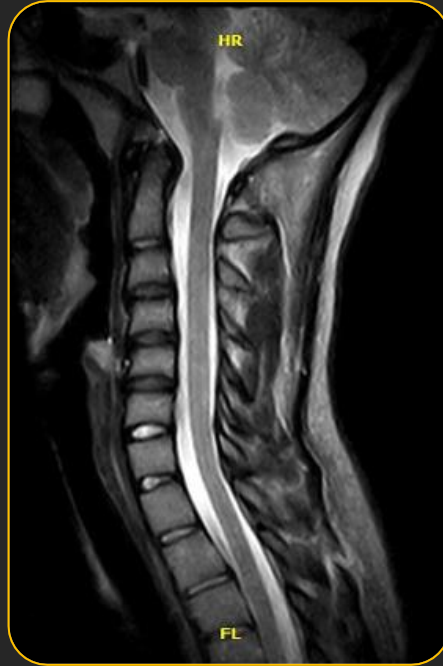


3D HYCE - Axial

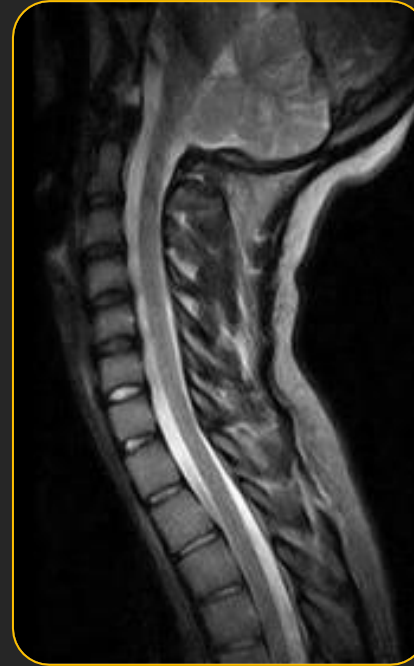
# C-Spine: Flexion & Extension



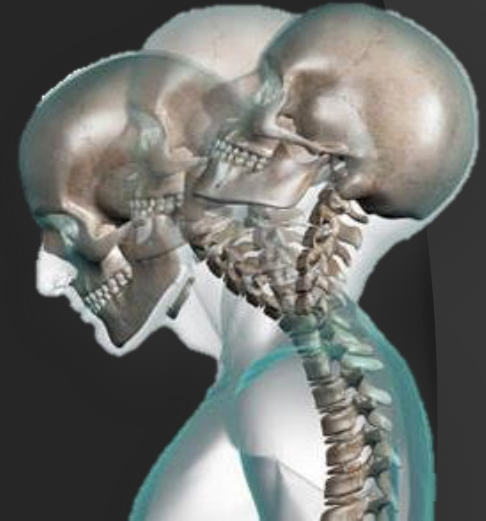FSE T2 – Flexion



FSE T2 – Neutral Position



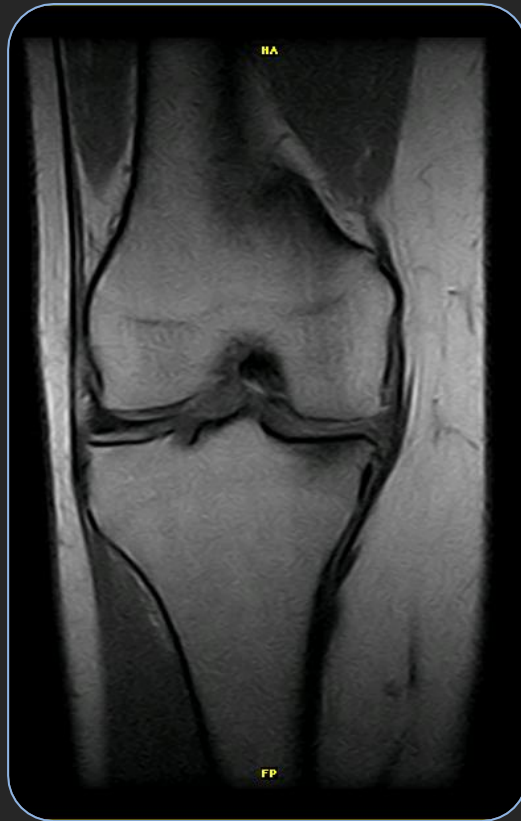FSE T2 - Extension



 **Weight Bearing**

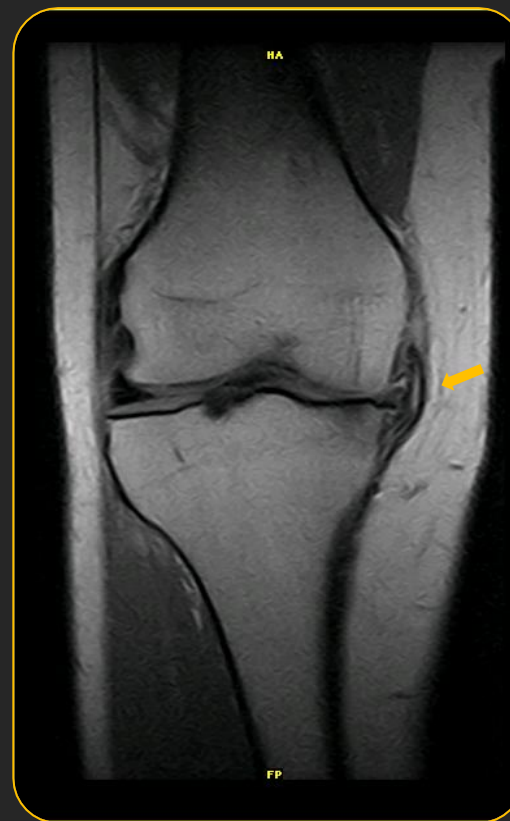# Knee: Overloading and Ligament Laxity

 Supine



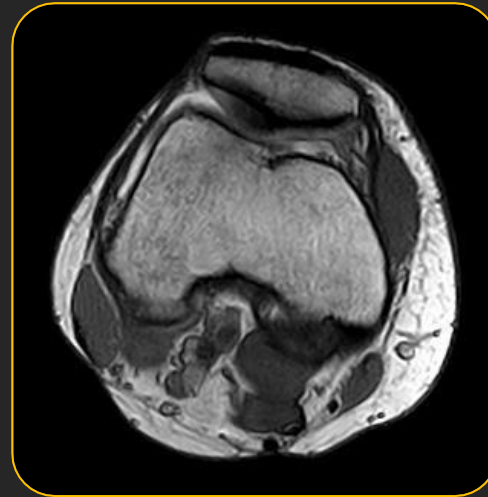
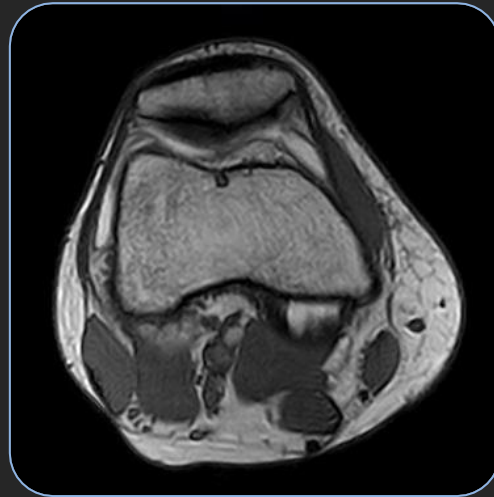
SE T1 – Coronal

 Weight Bearing



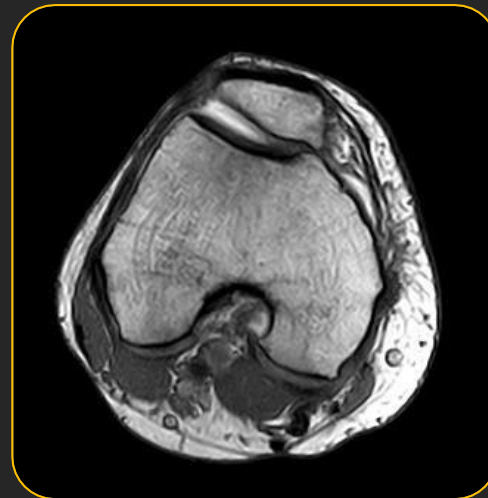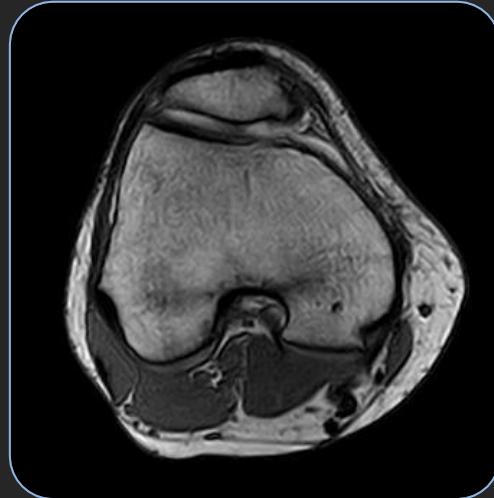
SE T1 – Coronal

# Knee: Medial Impingement Femoro-Patellar Joint



 Supine

 Weight Bearing

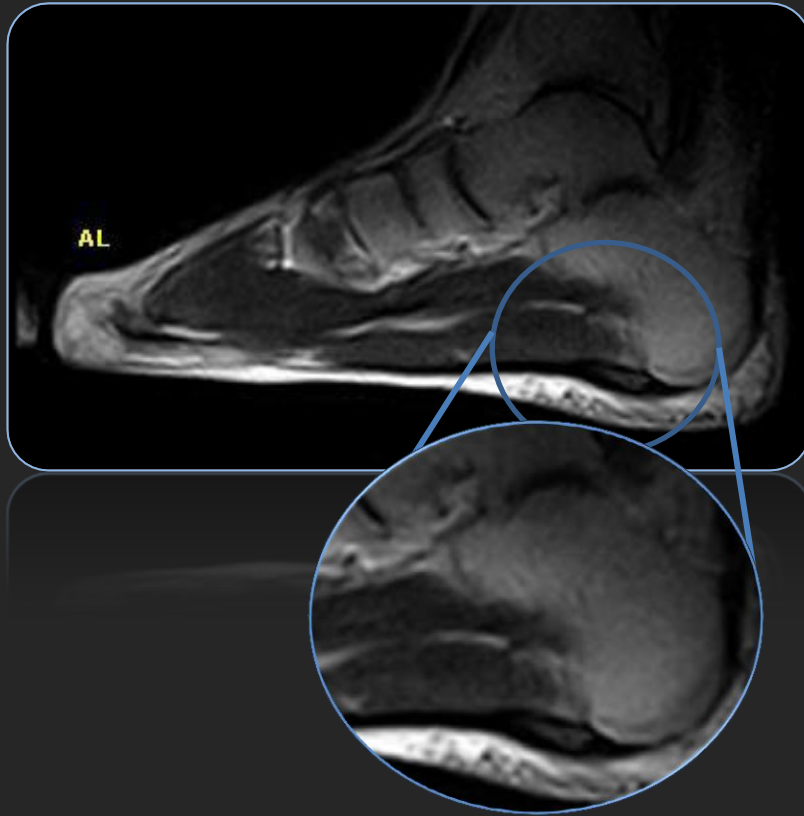


SE T1 - Axial

SE T1 - Axial

# Ankle: Plantar Fasciitis Tear

 Supine



 Weight Bearing

